

## IV. PEDIATRIC SURGERY

### ECHINOCOCCIASIS OF THE SPLEEN

ES Boia<sup>1</sup>, RE Iacob<sup>1</sup>, V Gîrlă<sup>1</sup>, Marioara Boia<sup>2</sup>

<sup>1</sup>Pediatric Surgery and Orthopedics Clinic Timisoara,

<sup>2</sup>Neonatology and Health Care Clinic Timisoara

#### Abstract

Echinococcosis is a tissue infection caused by the *Echinococcus granulosus* worm. The human body (an intermediary host) become infected when the child swallow the worm's eggs. It is more frequent in the rural area. We present the case of a patient, with spleen echinococcosis, hospitalized in our clinic. Lagrot cystectomy was performed with very good results.

**Key words:** spleen echinococcosis, Lagrot cystectomy.

#### Introduction

Echinococcosis is a tissue infection caused by the *Echinococcus granulosus* worm. Alternative names: hydatidosis, hydatid disease, hydatid cyst disease. The risk factors include exposure to canines, cattle, sheep, and the human body, which represent an intermediary host. Children become infected when they swallow eggs in contaminated food. The embryos escape from the eggs, penetrate the intestinal mucosa and enter the portal circulation. The infection is carried to the liver or to the lungs, where cysts form. Cysts can also form in the brain, bones, skeletal muscles, kidney, *spleen*, and other tissues<sup>1,2,3</sup>.

Echinococcosis is common in southern South America, the Mediterranean, the Middle East, Central Asia and Africa and is more frequent in the rural area. It can be prevented by health education<sup>4</sup>.

In our clinic we operated 5-6 cases every year and the incidence is higher in the last years.

**Diagnosis:** In the spleen localization the symptoms are usually present when the cyst is large enough to be felt by physical examination which are: abdominal pain in the upper left quadrant with the presence of palpable mass, fever and fatigability.

Tests to determine the presence and location of the cysts are:

- a chest and an abdominal X-ray
- a thoracic and an abdominal CT or ultrasound
- tests for antibodies to echinococcus<sup>5</sup>
- liver function tests

**Treatment:** In early diagnosis many cysts can be successfully treated with albendazole or mebendazole, which must often be used up to three months. If the cyst is too large, the definitive treatment is to remove them surgically if the patient's condition permits the procedure<sup>6</sup>.

The Lagrot procedure is used with very good results in our clinic<sup>1</sup>.

**Complications:** The large cysts may produce tissue damage by mechanical means. The resulting symptoms are related to the site, type and rate of the growth of the cyst. The cysts may rupture and cause severe illnesses, including fever, low blood pressure and shock, the cysts may also disperse and cause widespread disease.

#### CASE REPORT

This is the case of a girl, V. L., 12 years old, coming from an urban area, who was hospitalized in our clinic with the following symptoms: a slight abdominal pain in the upper left quadrant, minor dyspeptic syndrome, and tumor in the upper left quadrant of about 10/8 cm, having a solid consistency, relatively stable, slightly sensitive and painful.

#### History of the illness:

She had an abdominal trauma 2 months ago. She presented a pain in the upper left quadrant, minor dyspeptic syndrome. An abdominal ultrasound was done, which showed a tumor in the upper left quadrant. She was hospitalized in our clinic for establishing the diagnosis and the treatment.

#### Diagnosis:

- **anamnesis:** - without any elements concerning the etiology of the disease.
- **clinical findings:** - abdominal pain in the upper left quadrant and the presence of a tumor of about 10/8 cm, having a solid consistency, relatively stable, slightly sensitive and painful; lack of appetite
- **paraclinical:**
  1. laboratory data: - high number of leucocytes
    - positive tests for antibodies to echinococcus
    - the other analyses were normal
  2. imagistic data

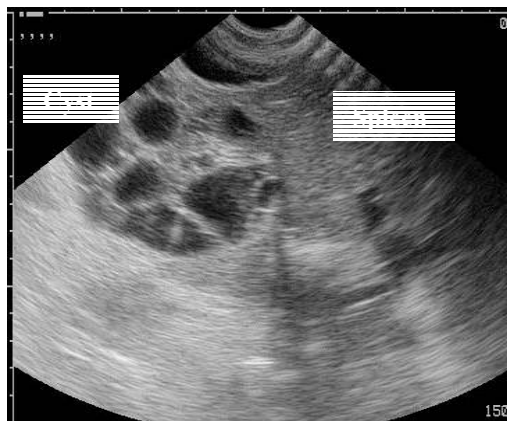

Fig. 1 Ultrasound aspect of the cyst.

a. ultrasound - transonic tumor of 74/70/115 mm,  $V = 317\text{cc}^3$ , situated near the pancreas, the hilum of the spleen, and the left liver lobe, appearing to be a pancreatic cyst or a hidatid cyst (Fig. 1).

b. X-ray - the thoracic and abdominal x-ray and the urography do not offer information for establishing the diagnosis.

c. CT – cystic tumor, well established, which is originated in the spleen, of 9,6/8,2 cm

Treatment

Preoperative care - complete biological investigation within normal limits.

Surgery – consist in following steps:

- median abdominal incision
- exposing the cyst in the superior part of the spleen (Fig. 2)
- puncture of the cavity of the cyst and aspiration of the clear liquid (Fig. 3)
- lavage of the cyst with NaCl 20%
- extraction of the germinal layer (Fig. 4 and 5)
- the partial excision of the external laminated cuticula of the cyst (Fig. 6) and the drainage of the remaining cavity (LAGROT procedure)
- double drainage of the abdominal cavity, suture of the abdominal wall

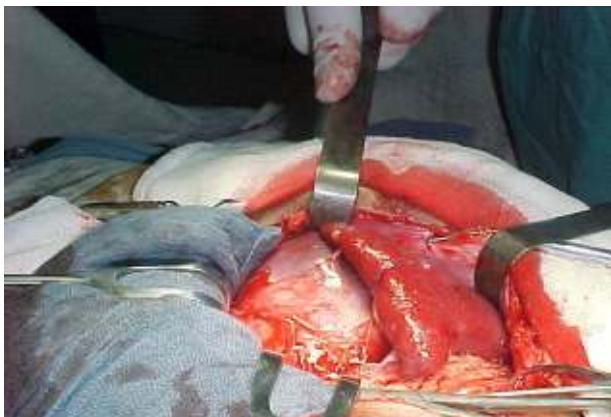

Fig. 2. Exposing the cyst in the superior part of the spleen

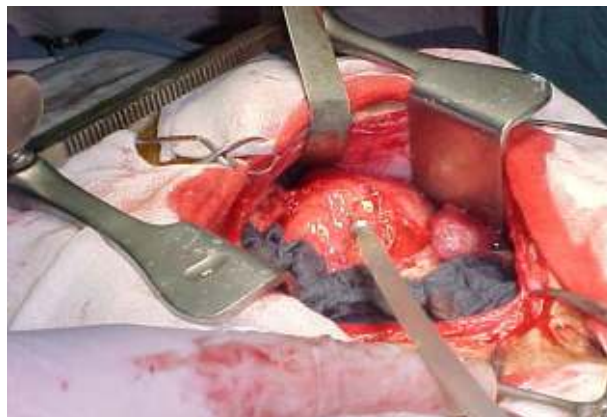


Fig. 3. Puncture of the cyst and aspiration of the clear liquid

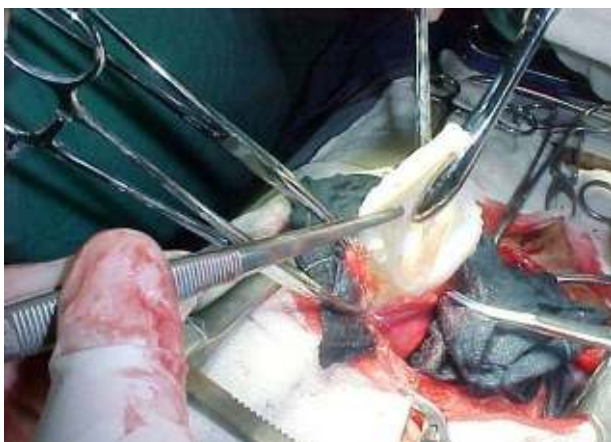

Fig. 4. Extraction of the germinal layer

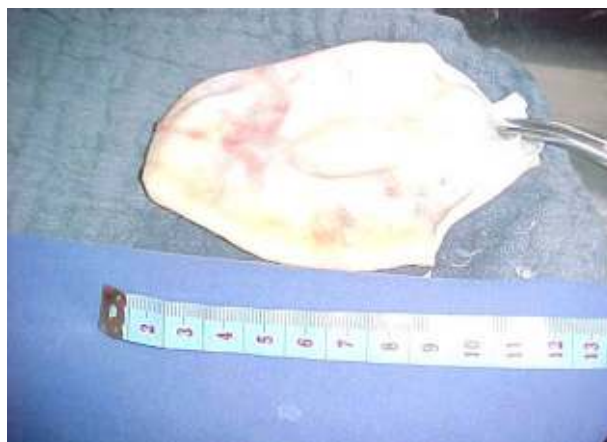

Fig. 5. The aspect and size of the germinal layer

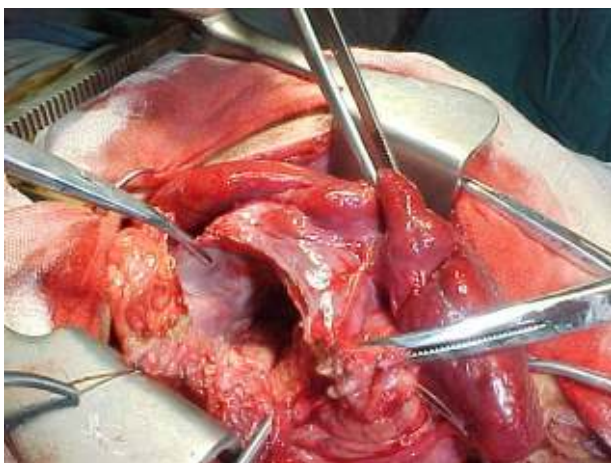


Fig. 6 The partial excision of the external laminated cuticula of the cyst

The postoperative care was done in the Intensive Care Unit in the first 4 days and after in the Surgery Compartment and it consisted of antibiotics (G Penicillin 4 x 1 mil. iu/day for 12 days, and after Amoxiclav 2x2 cp/day), electrolytes, vitamins.

The evolution was favorable, without complications. After 10 days stitches were removed, peritoneal drainage was interrupted after 12 days, and, at 14 days, the drainage of the cyst was interrupted too.

The patient was cured after 17 days.

**Conclusions**

1. The child's hydatidosis is sometimes localized at the level of the spleen.
2. The disease is asymptomatic for a long time and in this case it was diagnosed accidentally.

3. The Lagrot cystectomy has good results in this case, too.

#### References

1. Atmatzidis K, Papaziogas B, Mirelis C, Pavlidis T, Papaziogas T. *Splenectomy versus spleen-preserving surgery for splenic echinococcosis*. Dig Surg. 2003;20(6):527-31. Epub 2003 Sep 24.
2. Beaver PC et al: *Clinical parasitology*, 9<sup>th</sup> ed. Philadelphia, Lea and Febiger. 1984
3. Cebollero MP, Cordoba E, Escartin J, Cantin S, Artigas JM, Esarte JM. *Hydatid cyst of spleen*. J Clin Gastroenterol. 2001 Jul;33(1):89-90.
4. Col C, Col M, Lafci H. *Unusual localizations of hydatid disease*. Acta Med Austriaca. 2003;30(2):61-4.
5. Dar MA, Shah OJ, Wani NA, Khan FA, Shah P. *Surgical management of splenic hydatidosis*. Surg Today. 2002;32(3):224-9.
6. Durgun V, Kapan S, Kapan M, Karabicak I, Aydogan F, Goksoy E. *Primary splenic hydatidosis*. Dig Surg. 2003;20(1):38-41.
7. Fufezan V, Țepeneu P. *Chirurgie Pediatrică*. Timișoara. Ed. Amarcord. 1996.
8. Gherman I. *Boala hidatică*. Bucuresti. Ed. Medicală. 1991
9. Hamamci EO, Besim H, Korkmaz A. *Unusual locations of hydatid disease and surgical approach*. ANZ J Surg. 2004 May;74(5):356-60.
10. Jahani MR, Roohollahi G, Gharavi MJ. *Splenic hydatid cysts in a 20-year-old soldier*. Mil Med. 2004 Jan;169(1):77-8.
11. Kiresi DA, Karabacakoglu A, Odev K, Karakose S. *Uncommon locations of hydatid cysts*. Acta Radiol. 2003 Nov;44(6):622-36. Review.
12. Lo Casto A, Galia M, Barbiera F, Bartolotta TV, Tuttolomondo C, De Maria M. *Isolated hydatid disease of the spleen: CT findings in 4 patients and differential diagnosis*. Radiol Med (Torino). 2002 Sep;104(3):134-9.
13. Manterola C, Vial M, Losada H, Fonseca F, Bustos L, Munoz S, Barroso M. *Uncommon locations of abdominal hydatid disease*. Trop Doct. 2003 Jul;33(3):179-80.
14. Menendez-Arzac R, Sanjuan A, Rebolledo G, Marquez JC, Recinos EG, Cue A, Blas C, Flisser A. *Splenic hydatid cyst*. Rădulescu S, Meyer EA. *Parazitologie Medicală*. București. Ed. All. 1992
15. Ormeci N, Soykan I, Palabiyikoglu M, Idilman R, Erdem H, Bektas A, Sarioglu M. *A new therapeutic approach for treatment of hydatid cysts of the spleen*. Dig Dis Sci. 2002 Sep;47(9):2037-44.
16. Ozdogan M, Baykal A, Keskek M, Yorgancy K, Hamaloglu E, Sayek I. *Hydatid cyst of the spleen: treatment options*. Int Surg. 2001 Apr-Jun;86(2):122-6.
17. Pandeli C, Koutaba E, Burlea M. *Hepatic hydatid cyst and splenic hydatid cyst-their surgical treatment with splenic preservation*. Rev Med Chir Soc Med Nat Iasi. 1997 Jan-Jun;101(1-2):233-5.
18. Pinon JM et al. *Immunological study of hydatidosis*. Am J Trop Med Hyg 1979, 28:318.
19. Sayek I, Yalin R. *Surgical treatment of hydatid disease*. Arch Surg 1992, 115:847
20. Tarcoveanu E, Plesa A, Danila N, Lupascu C, Cotea E, Negru R. *Splenic hydatid cyst. Observations upon 38 cases of splenic echinococcosis*. Rev Med Chir Soc Med Nat Iasi. 2002 Apr-Jun;107(2):311-5.

