PARTICULAR APPLICATIONS OF ELASTIC STABLE INTRAMEDULLARY NAILING (ESIN) FOR FEMORAL FRACTURES IN CHILDREN

Dana Vasilescu[1], D Cosma[1], D Vasilescu[2]
[1] Department of Pediatric Orthopedics, Rehabilitation Clinical Hospital, Cluj-Napoca, Romania
[2] Radiology and Medical Imaging Clinic, Cluj-Napoca, Romania

Abstract

Over the past few years there has been a marked increase in the use of intramedullary fixation in the management of fractures of long bones in children. To some extend this reflects a more interventionist attitude among pediatric orthopedic surgeons but is also due to technical developments, notably that of the elastic stable intramedullary nail (ESIN).

We used ESIN for several years for treating transverse or short oblique fractures of long bones in children. We proposed to analyze the utility of this method in treating complex fractures or pathological fractures (not malignant) in children and we reviewed our series of patients treated with ESIN and we found particular cases of femoral fractures treated with ESIN. We analyzed for these patients the type of fracture, age, related conditions and radiographs.

All fractures consolidated in an axial position ($<5^0$ malposition in all planes) with full use of the affected limb. An additional stabilization by plaster casts (6 weeks) was used for the patient with fibrous dysplasia and the patient with long oblique fracture. Partial weight bearing was permitted after the removal of the cast or after 6 weeks for the other patients.

Intramedullary nails have found their place in he management of femoral shaft fractures in children and even more so in adolescents. ESIN should be used as the procedure of choice for treating femoral fractures in children for many reasons including the economic reason.

Keywords: femoral fracture, ESIN, pathological fracture, child, osteosynthesis

Introduction

Over the past few years there has been a marked increase in the use of intramedullary fixation in the management of fractures of long bones in children (1). To some extend this reflects a more interventionist attitude among pediatric orthopedic surgeons but is also due to technical developments, notably that of the elastic stable intramedullary nail (ESIN).

In 1979, physicians of the French school of Prevot in Nancy started using an elastic stable intramedullary system for femoral shaft fractures in children (1;2). The elastic nails of the French school were an analogous evolution to the stable elastic osteosynthesis proposed by a Romanian group in 1981 (3). In Metaizeau's 1988 monograph (4), the Nancy group describe the physiologic and biomechanical background for using the "embrochage centro medullaire elastique stable" (ECMES) system, the elastic stable centromedullary nailing system with its three-point pressure stabilization of the fractured bone.

Previous experience had suggested that elasticity and stability were not easily combined in one construct (5). However, working from the concept of three-point fixation, these surgeons were able to improve stability significantly by using two pre-tensioned nails inserted from opposite sides if the bone. Metaizeau (2) and his colleagues were able to show that titanium nails, which were accurately contoured and properly inserted, could impart excellent axial and lateral stability to diaphyseal fractures in long bones. Rotational stability was also better than had previously been experienced, although this was to remain the weakest point of the technique (5).

ESIN gives not a rigid but rather an elastic stability. This stimulates the fracture callus. An important advantage comes from the fact that the fracture site is not opened, there is no blood loss and the periostium retains its regenerative power. All of these factors contribute to rapid consolidation (6). If the right size nails are chosen, there is enough rotatory stability and the patients are allowed to bear weight as early as they choose. These factors also contribute to rapid consolidation. With an adequate size of nails there is enough rotatory stability and the patients can be allowed early weight bearing (4).

The ideal fracture for this technique is a transverse or short oblique diaphyseal fracture with minimal comminution in a long bone. However, such is the versatility of the method that the indications have widened considerably with time and personal experience (5). These fractures are easiest to nail and the results are generally good. However, if one is prepared to accept some operative difficulties, all types of fractures can be efficiently stabilized with ESIN with appropriate experience. It is advisable to first gain sufficient expertise with transverse fractures before embarking on nailing spiral fractures. Subsequently fractures with a butterfly fragment may be attempted and finally complex comminuted fractures (7).

For children with neuromuscular conditions or bone fragility, the period of immobilization must be kept to a minimum. Although the quality of bone healing may be uncertain in these patients, ESIN remains superior to plating. The nails function as a splint and protect bone from

chronic deforming. The sliding constructs have definitive advantages here (7).

Purpose

We used ESIN for several years for treating transverse or short oblique fractures of long bones in children. We proposed to analyze the utility of this method in treating complex fractures or pathological fractures (not malignant) in children.

Materials and method

From 2002 we used ESIN as the procedure of choice for children's fractures in our department.

We reviewed our series of patients treated with ESIN and we found particular cases of femoral fractures treated with ESIN. We analyzed for these patients the type of fracture, age, related conditions and radiographs (Table 1).

Surgical technique

Longitudinal skin incisions 2 to 3 cm long are made on the lateral and medial aspects of the distal femoral metaphysis at the level of the upper border of the patella. The entry hole into the bone is made using an awl about 2 cm above the distal growth plate of the femur.

It is preferable to introduce the first nail o the side where the fragments overlap (Fig. 1).

Table 1. Synopsis of patients

Age at operation	*Diagnosis*	*Type of implants used*	*Period of implant*	*Result*	*Removal of implant*
6 yrs	Fracture in the proximal third of the left femur. Fibrocystic dysplasia	K-wires	6 months (1 nail removed after 2 months because of distal migration)	Solid union	Yes
9 yrs	Pseudarthrosis of the middle third of the right femur after early removal of Kuntscher rod for femoral fracture	Elastic nails	1 nail removed after 6 weeks because of wrong direction in the proximal fragment)	Solid union after 2 months	No
15 yrs	Long oblique fracture in the middle third of left femur	Elastic nails	-	Solid union after 2 months	No (lost at follow-up)
15 yrs	Juvenile bone cyst (JBC) of the right femoral neck	Elastic nails	-	Slow healing of the JC	No

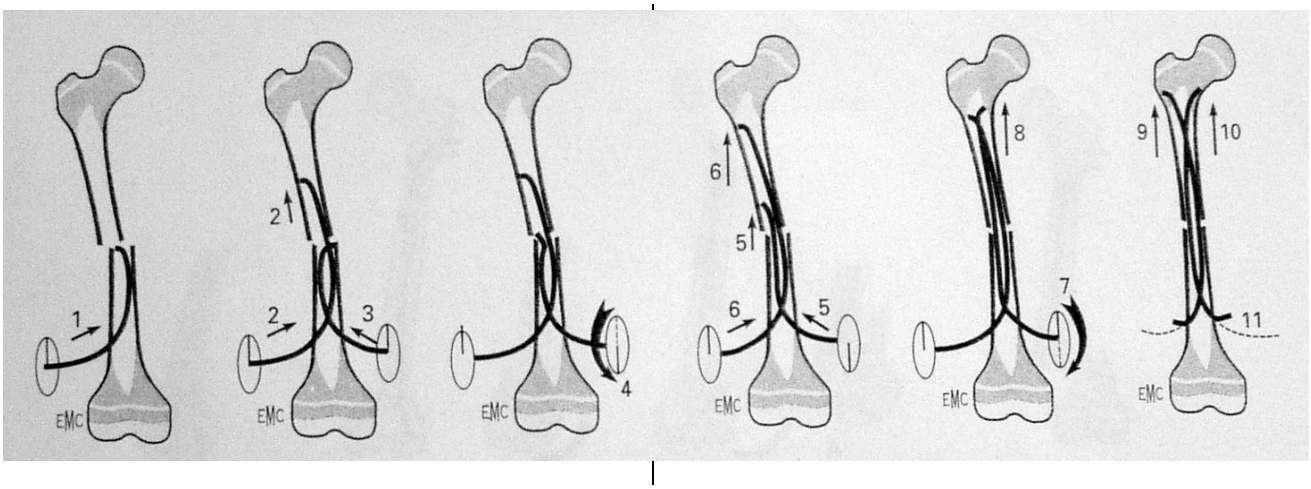

Fig. 1. 1. Introduce the nail on the side where the fragments overlap; 2. The first nail is pushed through the fracture site; 3. The second nail is introduced into the medullary canal; 4. The tip of the second nail is directed toward the fracture site; 5. The second nail is pushed through the fracture site; 6. The first nail is pushed upwards; 7. The second nail is re-orientated; 8. Both nails are pushed near the metaphysis but do not penetrate the cancellous bone; 9. and 10. After reduction of the fracture, the two nails are introduced into the cancellous bone of the metaphysis; 11. The bases of the nails are bent 90^0 and cut. After (7)

It is hammered up the medullary canal to within a few millimeters of the fracture. Under image intensification, the tip of the nail is directed by an axial twist across the fracture site. The second nail is inserted in a similar fashion. Both nails are directed so that they diverge superiorly. The quality of reduction is controlled radiographically. If angulation persists, it is corrected by external manipulation. The traction is removed and the two nails are impacted into the cancellous bone of the proximal metaphysis.

The bases of the nails are bent to 90^0 at the level of the lower metaphysis and cut to leave 1 to 1.5 cm beneath the skin.

The skin is closed. Before waking the patient up the knee is flexed to 90^0 to sink the nails into the fibers of the vastus medialis and lateralis and to avoid stiffness of the knee.

It is essential to ensure that there is no malrotation by assessing the internal and external rotation of the hip. If there is significant difference between the two hips, the child must be repositioned and the nailing redone. The nails are withdrawn so that they lie free within the medullary canal. After manually correcting the malrotation they are again impacted into the proximal cancellous bone.

Finally, a compression bandage is applied around the thigh and knee.

Results

All fractures consolidated in an axial position ($<5^0$ malposition in all planes) with full use of the affected limb. An additional stabilization by plaster casts (6 weeks) was used for the patient with fibrous dysplasia and the patient with long oblique fracture. Partial weight bearing was permitted after the removal of the cast or after 6 weeks for the other patients.

All patients had an unrestricted quality of life, due to the minimally invasive technique of the operation.

The desired formation of callus appeared in all patients, no pseudarthrosis was observed so far.

As expected, the time of consolidation of the pathological fracture and pseudarthrosis was distinctly longer than with normal fractures, which usually have an average of 6-8 weeks. Occasionally the implants were left in situ for more than two years without any visible negative effect on the growth of the affected limb. During growth the end of he nails may migrate into the metaphysis of the corresponding bone without radiologically visible irritation. Nails that become too short can be exchanged for longer and stronger implants.

We had 2 complications: wrong trajectory of one nail in the case of pseudarthrosis (which required removal after 6 weeks) and distal migration of the nail in the case of fibrous dysplasia (required removal after 2 months).

Other complications such as growth disorders, infection or problems with soft tissues were not observed.

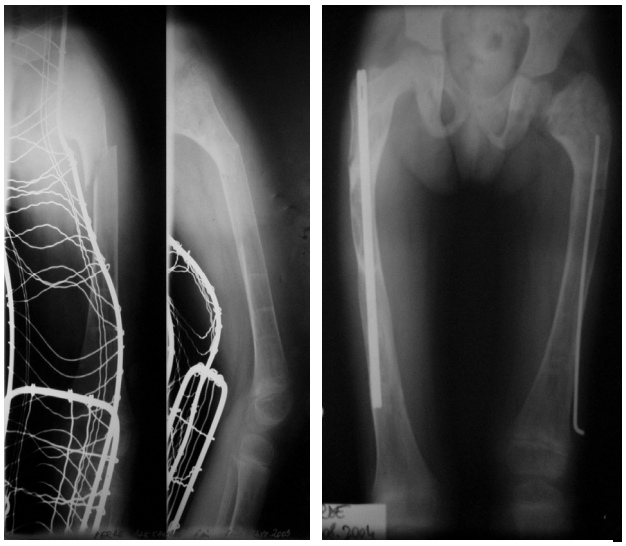

Fig. 2. Fracture in the proximal third of femoral shaft. Fibrous dysplasia. After union and removal of one nail because of distal migration.

Fig. 3. Long oblique fracture of the left femur (before and after nailing and union).

Discussions

Intramedullary nails have found their place in he management of femoral shaft fractures in children and even more so in adolescents (8;9).

There are two prerequisites if closed intramedullary nailing is planned: an orthopedic fracture table and an image intensifier. An orthopedic traction table with child-size shoes is advised for every closed treatment of femoral shaft fracture, whether the surgeons uses the extra- or the intramedullary system (9;10). An image intensifier is necessary for the closed reduction and fixation of a femoral shaft fracture.

Insufficient alignment of the fracture sometimes is a problem with elastic nails (10), especially in fractures with deficient bone marrow, as in osteogenesis imperfecta or myelodysplasia (8).

Fig. 4. Pseudarthrosis of the right femur. Solid union after removal of one wrong direction nail.

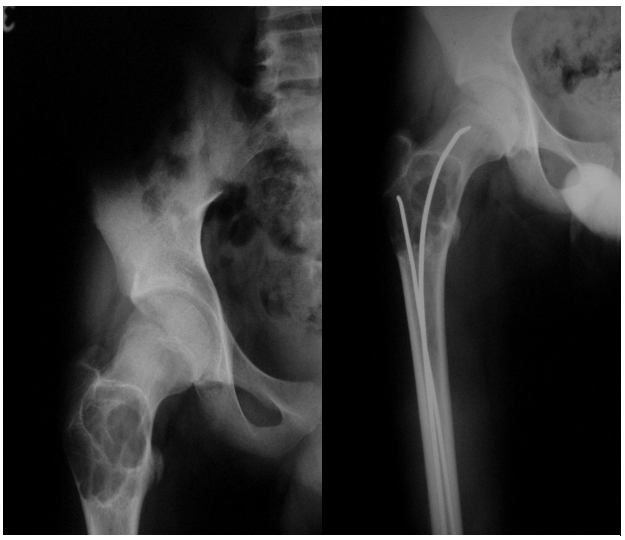

Fig. 5. Juvenile bone cyst of the right femoral neck. Recession of the cyst after nailing (the elastic nails act as internal splint and serve for cyst decompression).

Local skin irritation at the distal femoral insertion site of the rods has been observed after using Nancy nails. In Nancy, 13 of 123 patients (9) and in Munich 2 of 54 children needed secondary shortening of the nails (6). In Stuttgart Parsch observed 8 skin irritations in 45 cases that necessitated shortening of the nail (6). Since the introduction of the new nails with olives, this problem disappeared.

Knee mobility may be reduced in the early phase after the introduction of elastic nails. Parents must be warned about this to avoid unnecessary worries. The limitation of knee flexion disappeared rapidly in all cases after pins were removed (6).

Elastic stable intramedullary nailing has several advantages (11):

- The operation can be done through small incisions, without significant trauma to tissue;
- The reduction is performed as either a closed or an open procedure, thus the pathological bone area may be exposed and, if required, biopsied. The fracture haematoma, the periost and the surrounding soft tissue are spared to encourage accelerated formation of callus;
- The system is elastic and not stiff, thereby rapidly inducing callus with subsequent secondary fracture-healing;
- The metal nails can be left in place without negatively affecting the healing of the bone disease, since, according to the prevailing opinion in the literature, no negative influence on the growth of the affected bone has been demonstrated to date;
- The removal of the implants is simple, quick and atraumatic.

Elastic nails have a useful role in the management of benign pathological fractures of long bones. The pathological fracture may be as a result of local bone weakness or more generalized pathology.

Asymptomatic defects such as fibrous cortical defects or unicameral bone cysts can present as a fracture (12;13). In general, these fractures will unite and often cyst itself will heal. The fracture can be treated by conservative methods but use of elastic nails has some advantages. As well as the stabilization of the fracture the nails will decompress the cyst (11;14;15), which will promote healing of the defect as the fractures unites.

The most common cause of generalized bone weakness resulting in fractures is osteogenesis imperfecta. As well as presenting with an acute long bone fracture, osteogenesis imperfecta also results in progressive bowing of the long bones as a result of repeated micro-fractures. Elastic nails can be used to manage the acute fracture and also to stabilize corrective osteotomies.

Particular care should be exercised in the use of ESIN in osteogenesis imperfecta. Perforation through the abnormal cortex may easily occur and the medullary canal may be very narrow. It is recommended that as long a nail as possible be used and it may be necessary to perform exchange nailing as the child grows. Bending the end into a hook will prevent the nail from being pulled into the bone with subsequent growth. The nails should be left in place at least until the end of skeletal growth.

Conclusions

Elastic stable intramedullary nailing, as a minimal invasive procedure, appears to be safe and reliable method that has good long-term results in the treatment of femoral fractures in children aged 3-15 years. This method has advantages and disadvantages but the overall results make them superior to both traction and cast, in the period of minimal invasive procedures' advent in pediatric orthopedics. For social, psychological and economic reasons, it is time to abandon traction and cast as treatments for femoral fractures in children.

References

1. Metaizeau JP. L'osteosynthese chez l'enfant. Techniques et indications. Rev Chir Orthop 1983;(69):495-511.
2. Ligier JN, Metaizeau JP, Prevot J. L'embrochage elastique stable a foyer ferme en traumatologie infantile. Chir Pediatr 1983;(24):383-385.
3. Firica A, Popescu R, Scarlet M, Dimitriu M, Ionescu V. L'osteosynthese stable elastique, nouveau concept biomecanique. Etude experimentale. Rev Chir Orthop 1981;(67):82-91.
4. Metaizeau JP. Osteosynthese chez l'enfant. Embrochage centro-medullaire elastique stable. Montpellier: Sauramps, 1988.
5. Barry M, Paterson JMH. Flexible intramedullary nails for fractures in children. J Bone Joint Surg [Br] 2004;(86-B):947-953.
6. Parsch KD. Modern trends in internal fixation of femoral shaft fractures in children. A critical review. J Pediatr Orthop [Br] 1997; 6(2):117-125.
7. Metaizeau JP. Stable elastic intramedullary nailing for fractures of the femur in children. J Bone Joint Surg [Br] 2004;(86-B):954-957.
8. Heinrich SD, Drvaric D, Darr K, MacEwen GD. The operative stabilization of pediatric diaphyseal femur fractures with flexible intramedullary nails: a prospective analysis. J Pediatr Orthop 1994;(14):501-507.
9. Ligier JN, Metaizeau JP, Prevot J, Lascombe P. Elastic stable intramedullary nailing of femoral shaft fractures in children. J Bone Joint Surg [Br] 1988;(70):74-77.
10. Heinrich SD, Drvaric D, Darr K, MacEwen GD. Stabilization of pediatric diaphyseal femur fractures with flexible intramedullary nails (A technique paper). J Orthop Trauma 1992;(6):452-459.
11. Knorr P, Schmittenbecher PP, Dietz HG. Elastic stable intramedullary nailing for the treatment of complicated juvenile bone cysts of the humerus. Eur J Pediatr Surg 2003;(13):44-49.
12. Kaelin AJ, MacEwen GD. Unicameral bone cysts: natural history and the risk of fracture. Int Orthop 1989;(13):275-282.
13. Ahn JL, Park JS. Pathological fractures secondary to unicameral bone cysts. Int Orthop 1994;(18):20-22.
14. Roposch A, Saraph V, Linhart WE. Flexible intramedullary nailing for the treatment of unicameral bone cysts in long bones. J Bone Joint Surg [Am] 2000;(82-A):1447-1453.
15. Cohen J. Intramedullary nailing for the treatment of unicameral bone cysts. J Bone Joint Surg [Am] 2001;(83-A):1279-1280.

Correspondence to:

Dana Vasilescu
Viilor Street, No. 46-50
Cluj-Napoca 400347,
Romania
E-mail: drvasilescu@yahoo.com