

## GOLDENHAR-GORLIN SYNDROME – CASE PRESENTATION

Ileana Petrescu<sup>1</sup>, Eva Nemes<sup>1</sup>, Simona Cosoveanu<sup>1</sup>, Luminita Chiutu<sup>1</sup>, Adriana Moisă<sup>2</sup>

<sup>1</sup> 2<sup>nd</sup> Pediatric Clinic, County Emergency Hospital Craiova; UMF Craiova

<sup>2</sup> 2<sup>nd</sup> Pediatric Clinic, County Emergency Hospital Craiova

### Abstract

The paper presents the case of a 6-week-old female infant, diagnosed with Goldenhar-Gorlin syndrome according to the clinical picture (facial dysmorphism associated with left microsomia, left microtia, preauricular appendage, and unilateral macrostomia with malocclusion) and non-cyanotic heart malformation – DSA of an ostium secundum type, poorly tolerated.

**Key words:** Goldenhar-Gorlin Syndrome, infant, diagnosis.

### Introduction

The Goldenhar-Gorlin syndrome represents a complex of anomalies, especially ocular, aural, and mandibular, unilateral; it is frequently associated with vertebral anomalies or/and malformations of internal organs. The affection is a very rare one (1/25.000 live births) with a M:F report of 3/2.

### Clinical case

We present the case of a 6-week-old female infant, who was admitted in 2<sup>nd</sup> Clinic Pediatric (FO 46743/2005) after transferring her from a Pediatric section of a county hospital, in order to be diagnosed with a precordial systolic breath, level III and a persistent respiratory functional syndrome.

The anamnesis reveals that she is the first child of a young, healthy couple. She is the result of a pathologic pregnancy (which required repeated hospitalizations of the pregnant woman, without her presenting their nature), born dismature. She delivered spontaneously, on term, with a pelvic presentation, W = 1,900 g; the Apgar score could not be mentioned by the mother, nor the immediate postnatal evolution. The new born was breast fed for two weeks, then with Lactovit. From the age of three weeks, the infant has presented generalized cyanotic stirring episodes, which required hospitalization.

Objective exam at admission: altered general state, without fever, deficitary nutrition state (G=3,000g), pale teguments and mucosa, perioronasal and extremities cyanosis, dysmorphic, asymmetric with left microsomia, left microtia, preauricular appendages, cheek clefting unilateral macrostomia with homolateral occlusion. Absent subcutaneous cellular tissue at all levels, moderate polypnea with subcoastal draught, spastic cough, AV=148/min, systolic breath level III precordial, liver at 1 cm under the right lower rib, low appetite, present archaic reflexes.

The clinical aspect of the infant pleads for a syndrome with facial asymmetric, unilateral affection, the Goldenhar-Gorlin Syndrome [fig.1].

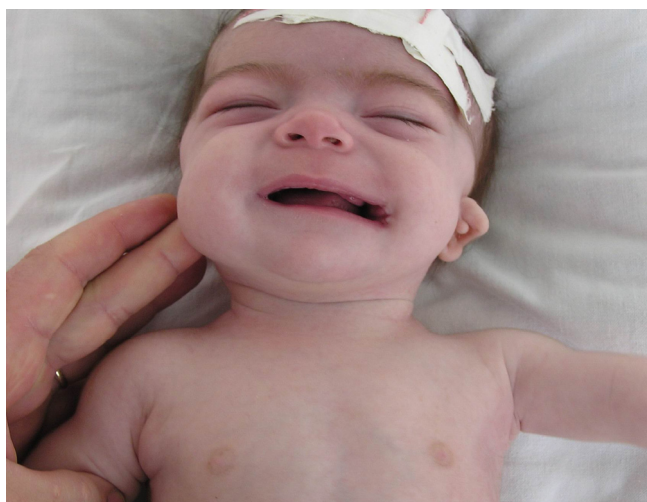
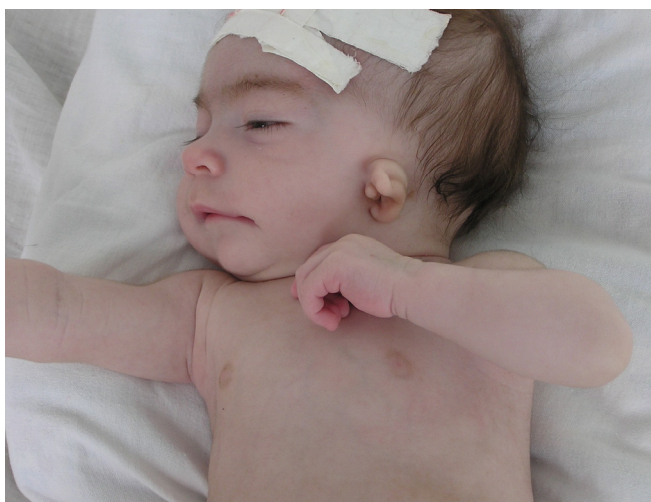
Fig.1.

In order to specify the infant's state and the evaluation of the associated anomalies, we have performed paraclinic investigations and laboratory exams. The

biological tests indicate a moderate anemia (Hb=11.20g/dl, Ht=34%, anisocytosis), hypocalcaemia (Ca=1.86mmol/l), the other laboratory findings being within normal limits (acute

phase reactants, sideremia, proteinemia, glycaemia, urea, creatinine, urine brief exam).

The cardio-vascular x-ray: micronodular opacities perihilary grouped and in the right upper pulmonary field and infrahilary peribronchopulmonary.

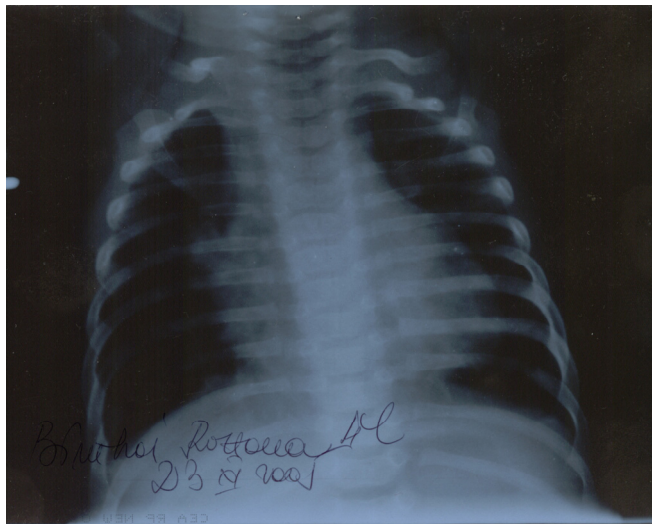


Fig.2

The cardio-vascular x-ray at the age of 4 months (when the infant was again admitted in the hospital): vascular opacities of increased intensity; enhanced cord in frontal plan [fig.2].

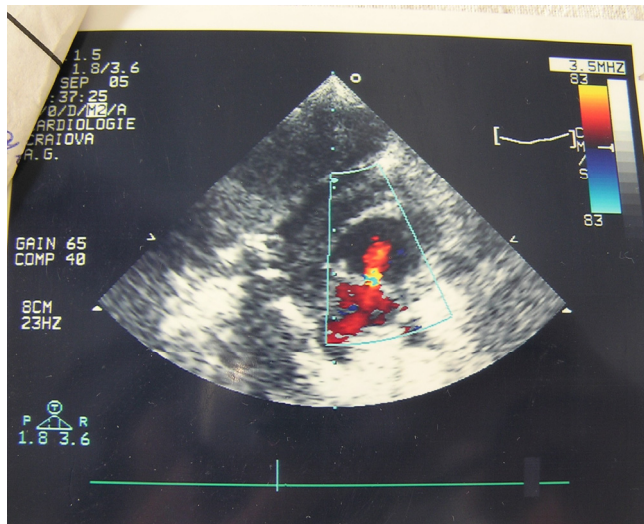


Fig.3

The echocardiography which was performed after 6 weeks and then repeated after 4 months [fig.3] identifies, at the level of the interatrial septum, in the mean 1/3, a continuity solution of 3.5 mm. The established diagnosis is septal atrial ostium secundum defect. The specialty exam which was performed in the Tg. Mures Cardiovascular Surgery Clinic indicates a reparatory surgical intervention at an older age.

Abdominal echography describes a normal echographic aspect of the abdominal organs.

The ENT exam identifies the presence of a malformed outer aural conduct and left external ear with a reconstruction possibility.

The evolution of the case was towards heart failure, requiring digitizing at the age of 4 months when a serious influence upon the nutrition state was also noticed (level II dystrophy).

### Discussions

The Goldenhar-Gorlin Syndrome (also called oculo-auricular dysplasia, facio-auriculo-vertebral, hemifacial microsomia or unilateral intrauterine facial necrosis) represents a complex of anomalies especially ocular, auricular and at the cheek level, unilateral. Vertebral anomalies, anomalies at the level of the internal organs and sometimes mental retardation can be associated (3).

This syndrome was presented by Goldenhar (a Swiss ophthalmologist) in 1952, its description being completed by Gorlin in 1963 (American geneticist and pathologist). It is a very rare disease with an incidence of 1/25000 living births, the minimum prevalence being of 1/45000 in Northern Ireland (4). Sex ratio M:F is of 3/2. The incidence of one of the affections which are part of the syndrome

groups with assymetric facial affection has been reported to be between 1/3500 and 1/5600 live births. (1,4,6)

Most cases are sporadic, but in familial cases all the inheritance modes are possible: autosomal dominant (the most frequent among them), autosomal recessive and multifactorial (1,4,6).

We do not know the precise cause – we suspect an abnormal embryonic vascular supply (fetus vascular accident) to the first arch and abnormality of mesoblastic development affecting the formation of branchial and vertebral systems (6, 10).

The suggestive modifications for the Goldenhar syndrome are present at birth and they consist of maxillary bone hypoplasia (temporal and malar) and unilateral hypoplasia maxilla which give an aspect of facial asymmetry (with unilateral microsomia that appears more often on the right side). We can meet incomplete development of certain facial muscles, cleft palate, cleft lip, an abnormally large mouth (unilateral macrostomia by cheek or upper lip clefting which leads to unilateral malocclusion) (1).

About 10-30% of the effected individuals present malformations on both sides of the body, but with one side more affected than the other (5).

The ocular anomalies are met in 60% of the cases: epibulbar dermoids and lipodermoids, small orbits, colobomas, microphthalmia, blepharophimosis, strabismus, hypertelorism (3,5).

The ear anomalies (in 40% of the cases) include outer ear anotia (absence), outer ear malformation (microtia), outer aural conduct atresia, preauricular nodules or appendages, placed between tragus and corner of the mouth, sometimes blind fistulas in that area. The presence of middle or inner ear anomalies can lead to deafness (1,3,5).

Sometimes, the Goldenhar syndrome can be associated with a dysplasia of the axial skeleton (especially of the cervical region): hypoplasia, the fusion or/and absence of certain vertebrae. (4,5).

The associated anomalies of the internal organs are:

- Congenital heart defects in 5-58% of cases: DSV, persistence of arterial conduct, tetralogy of Fallot, big vessel transposition (1,4)
- Esotracheal fistula (7)
- Pulmonary agenesis (1,7)
- Renal affections: renal agenesis, ectopia or renal fusion, multicystic kidney, double ureter, vesico-ureteral reflux.
- Neurological affections: microcephaly or hydrocephaly, occipital encephalocele etc.

Moderate mental retardation may be present in 10% of the cases (2).

The diagnosis can be established during intrauterine life by means of fetal echography which shows different levels of underdevelopment (more frequent – unilateral) of the craniofacial structures. Hemifacial microsomia, unilateral maxillary hypoplasia, microphthalmia can be detected.

After birth it is necessary to perform a skull CT scan and a NMR, which allow us to notice NCS malformations: intracranial dermoid cysts, brain scythe calcification (4).

The differential diagnosis is performed by hemifacial microsomia (the anomalies are confined to the viscerocranium), other syndromes which can associate the Goldenhar syndrome and which could have common pathogenic mechanisms (the abnormal development of the

neural crest): Charge syndrome, Townes-Brocks syndrome. (4).

The prognostic quo ad vitam is considered favorable when there are no complications. The eye and ear anomalies can be corrected by plastic surgery (indicated in early years). Thus, the epibulbar dermoids can be removed, the palate or the lip reconstruction can be performed, and also the resection of the preauricular appendage, the reconstruction of the outer ear (after the age of 4) and even palate and lip shortening and extension, orthodontic treatment (10). The treatment is a supporting one and it supposes regular audiometric controls.

The genetic advice is useful; cases with familial affection based on familial studies are cited (6-8%) (9). Since most forms are sporadic, the risk that an individual with Goldenhar syndrome have a child bearing this affection is unlikely to happen.

### Conclusions

The above presented case was diagnosed with Goldenhar-Gorlin syndrome by the clinical aspect (facial dysmorphism marked with facial asymmetry, left preauricular appendage, unilateral macrostomia by cheek clefting with homolateral malocclusion). The ENT exam confirms the presence of the outer ear canal and it is not associated with vertebral anomalies. The infant also presents heart congenital malformation (more rarely met) – DSA ostium secundum badly tolerated, appearance of heart failure until the age of 4 months with consequences upon the weight gain, thus hiding the prognostic.

### Bibliography

1. Anneliese Walter-Roşianu, Geormăneanu M. (1986). Boli ereditare în Pediatrie vol II, Bucureşti, Ed.Medicală pg.27-29.
2. Goldenhar, M: Associations malformatives de l'oeil et de l'oreille, en particulier le syndrome dermoide epibulbaire-appendices auriculaires-fistula auris congenita et ses relations avec la dysostose mandibulo-faciale. Journal de génétique humaine, Genève, 1952,1 :243-282
3. Gorlin RJ, Cohen MM Jr, Levin LS Syndromes of the head and neck 3rd ed. New York, Oxford, 1990, pp. 641-9.
4. Gorlin, R.J. et al: Oculo-auriculovertebral dysplasia. Journal of Pediatrics, St. Louis, 1963, 63: 991-999
5. Korlin R, Jue K., Jacobsen U, Oculoauriculovertebral dysplasia. J.Paediatric 1963; 63: 991
6. Kulkarni VV, Shah MD, Parikh AA. Goldenhar syndrome (a case report). J Postgrad Med 1985;31:177-9
7. Martinelli P, Maruotti GM, Agangi A et al. Prenatal diagnosis of hemifacial microsomia and ipsilateral cerebellar hypoplasia in a fetus with oculoauriculovertebral spectrum. Ultrasound Obstet Gynecol 2004;24(2):199-201
8. Pantos RW, Sugar JM. Excision of limbal dermoids. Ophthalmic Surg 1991; 22 :85 -9
9. Rao VA, Kaliaperumal S, Subramanyan T, Rao KR, Bhargavan R. Goldenhar's sequence with associated juvenile glaucoma in Turner's syndrome. Indian J Ophthalmol 2005;53:267-268
10. www.worldcf.org (World Craniofacial Foundation)

Correspondence to:

Ileana Petrescu  
60, Mareşal Antonescu Street  
Craiova  
Romania  
Telephone: +40251502210  
E-mail:scosoveanu@yahoo.com