

## CONGENITAL DIAPHRAGMATIC HERNIA

Ramona Mandrusca<sup>1</sup>, ES Boia<sup>1</sup>, C Popoiu<sup>1</sup>, Luminita Vrinceanu<sup>1</sup>

<sup>1</sup>University of Medicine and Pharmacy “Victor Babes” Timisoara

### Abstract

Five defects might develop in the diaphragm to create intraabdominal viscera herniation:

1. The esophageal hiatus is the most frequent area, wherein the stomach prolapses into the mediastinum.
2. A congenital posterolateral defect occurs from maldevelopment of the diaphragm.
3. Anomalous attachment of the diaphragm to the sternum and adjacent ribs results in a foramen, which allows the bowel to extend into the anterior mediastinum.
4. The association of an epigastric omphalocele and a retrosternal defect in the diaphragm and pericardium (pentalogy of Cantrell) results in herniation within the pericardium.
5. Attenuation of the tendinous or muscular portion of the diaphragm produces eventration.

Paralysis of the muscles of the diaphragm either from trauma to the phrenic nerve or a congenital defect in the anterior horn cells of cervical spinal cord (C3,4) -Werdnig-Hoffmann disease, results in herniation of the intraabdominal contents into the thoracic cavity.

### DEFINITIONS

Congenital diaphragmatic hernia is characterized by a defect in the posterolateral diaphragm (foramen of Bochdalek) through which the abdominal viscera migrate into the chest during fetal life.

**Key words:** congenital diaphragmatic hernia (CDH), diaphragm.

### ANATOMY OF THE DIAPHRAGM

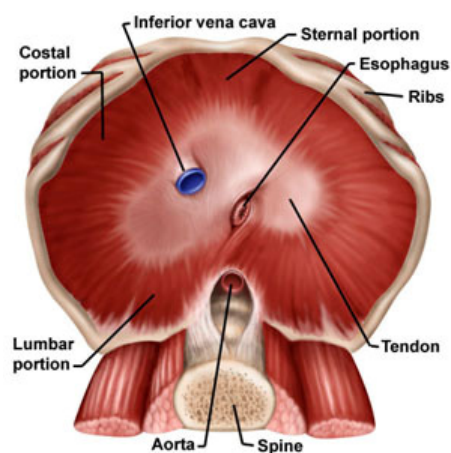
The diaphragm is a fibromuscular sheet that separates the thoracic and abdominal cavities. It is the principal muscle of inspiration.

1. The fibrous portion of the diaphragm—the central tendon, is more anteriorly than centrally oriented and it accounts for about 35% of the total surface of the diaphragm.
2. The muscular portion consists of:
  - the short muscle slips arising from the xiphoid process
  - the origin from the lowest six ribs of the costal arch
  - the muscle arising from the medial and lateral arcuate ligaments, overlying the psoas and quadratus lumborum muscles respectively
  - the vertebral part, the crura, arising from the first three lumbar vertebrae

In 80% of bodies, there is a gap between the muscles arising the lateral arcuate ligament and those of costal origin as they traverse to the central tendon, which is called the vertebral-costal or lumbo-costal triangle. This muscular gap is covered by a fibrous membrane—foramen Bochdalek.

In the diaphragm are three significant openings:

- the vena cava traverses the central tendon to the right of the midline;
- the esophageal hiatus is just to the left of the midline and slightly posterior to the plane of vena cava;
- the aorta lies on the vertebral bodies



### EMBRYOLOGY OF THE DIAPHRAGM

The normal diaphragm is derived from several components. The central tendon is formed from the septum transversum; small dorsolateral portions are from pleuroperi-toneal membranes; dorsal crura are from the esophageal mesentery; the posterior lateral muscle is derived from the inter-costal muscle groups.

Development of the diaphragm begins at week four in human gestation with formation of the septum transversum, which separates the thoracic and abdominal cavities of the embryonic coelom leaving two pleuroperitoneal canals dorsolaterally. The pleuroperitoneal folds extend from the late-lateral body wall and grow medial and ventral until week seven—when they fuse with septum transversum and the mesentery of the esophagus.

The last area for fusion of the septum transversum and the pleuroperitoneal membranes is a foramen called pleuro-peritoneal canal. CDH is a consequence of a persistent pleuroperitoneal canal that results in a defect in the posterolateral portion of the diaphragm. This defect occurs five times more commonly on the left side, because the liver facilitates closure of the right pleuroperitoneal canal.

During the early development of the diaphragm, the midgut is herniated into the yolk sac. If closure of the pleuroperitoneal canal has not occurred by the time the midgut returns to the abdomen (weeks 9 through 10), the abdominal viscera herniate through the lumbocostal trigone into the

ipsi-lateral thorax. This prevents the normal counterclockwise rotation and fixation of the midgut. No hernia sac is present if the herniation occurs before complete closure of the pleuro-peritoneal canal.

### LUNG DEVELOPMENT

At 26 to 33 days gestation, the tracheal diverticulum from the foregut is identified and this split into two lung buds. The subsequent development of the airways is divided into:

- The glandular phase (day 52 to the end of the 16<sup>th</sup> week of gestation), when bronchopulmonary segments are forming by dichotomous branching of the terminal buds;
- The canalicular phase (17 to 26 weeks of gestation) is characterized by continued budding of air spaces, which form the respiratory bronchi, atria and alveoli of the lung. During this period are forming the type I pneumocytes, the type II pneumocytes. This last type produce surfactant beginning at the 24<sup>th</sup> week of gestation.
- The alveolar phase extends from 26 weeks to full term. At this stage, progressive elongation and budding of the thin-walled air spaces occur beyond the transitional ducts, respiratory bronchioles and saccules.

At birth there are about 24 million saccules and these saccules develop septa to form distinct alveoli. The alveoli increase rapidly in number but not in size for 1<sup>st</sup> 3 years. Between 3 and 8 years, the alveoli continue to increase in number and size. At 8 years and older, they enlarge as the chest cavity increases in volume, but no new alveoli form.

### EPIDEMIOLOGY

CDH probably occurs once in 1/2200 births, when stillbirths are included. The natural history of CDH has become clarified with prenatal ultrasound imaging of the fetus.

The cause of CDH is unknown, but there may be a genetic factor; it has been reported in identical twins, sibling and uncles and cousins. Females are affected almost twice as often as males.

### PATHOPHYSIOLOGY

CDH is characterized by a defect in the posterolateral diaphragm (foramen of Bochdalek), through which the abdominal viscera migrate into the chest during fetal life.

The resultant compression of the lungs during their growth and development causes pulmonary hypoplasia to a greater or lesser degree. It is this pulmonary hypoplasia which is responsible for the high rate of mortality associated with this lesion.

Pulmonary hypoplasia associated with CDH is characterized by a diminished number of bronchial branches and total alveoli for gaseous exchange. The pulmonary vasculature is also affected by pulmonary hypoplasia. The arteries are smaller in diameter and have a thicker muscular wall.

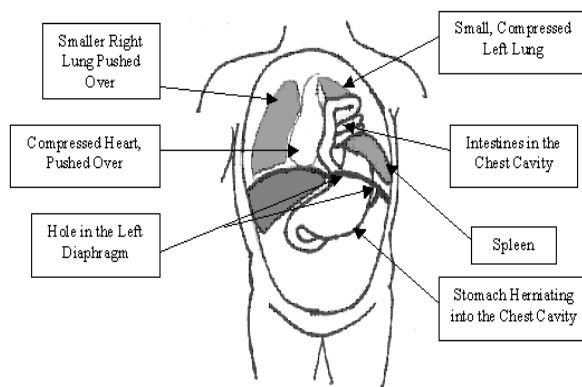
Pulmonary hypertension frequently occurs in infants with pulmonary hypoplasia. The hypertension is the result of a diminished number of pulmonary vessels and

capillary bed, an increased resistance from the abnormally thick muscled arterial walls and an abnormally increased reactivity of arterial musculature to hypoxia, hypercarbia, acidosis and other mediators of vascular tone.

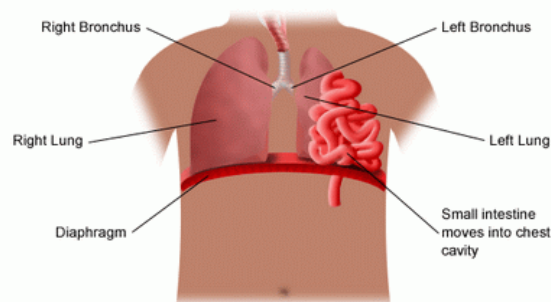
At birth, the infant has difficulty attaining air-entry into the lungs, because the most important mechanism of inspiration is contraction of the diaphragm and because the mediastinum is pushed to the opposite chest and both lungs are compressed. The negative pressure generated during inspiration produces further herniation of bowel within the thorax. During respiratory distress, the infant swallows large volumes of air, which distend the bowel and further compress the lung.

The number of pulmonary artery branches is diminished, so that the right ventricular workload requires pushing blood through a small vascular bed, which results in increased pulmonary artery and right heart pressure.

Shunting of blood from right to left occurs through the ductus arteriosus and foramen ovale, exacerbating systemic hypoxia, hypercarbia and acidosis.



**Congenital Diaphragmatic Hernia**



### DIAGNOSIS

#### PRENATAL DIAGNOSIS

Most series of CDH presenting after birth have quoted a mortality of approximately 50%. However, the advent of widespread maternal ultrasonography has resulted in the identification of a large group of fetuses with CDH

who die in utero, or soon after birth and never present to the paediatric surgeon. The impact of this “hidden mortality” on the management of a fetus with CDH is considerable, as the outlook is much more grave than previously appreciated, with a mortality between 60% and 80%.

There are a number of features which have prognostic value in prenatally diagnosed CDH. Prenatal diagnosis itself may indicate a worse prognosis. Other poor<sup>2,6,11</sup> prognostic indicators include:

- polyhydramnios
- small left ventricular size
- presence of the stomach above the diaphragm
- the liver within the thorax
- lung area-to-head circumference ratio<1
- early gestation diagnosis(less than 24 weeks)

Critical ultrasound findings include the presence of viscera in the right or the left hemithorax above the level of the inferior margin of the scapula or at the level of the four-chamber view of the heart. The hypoechoic signal of the fluid-filled stomach, gallbladder or bowel can be distinguished from the hyperechoic signal of the fetal lung.

Other common findings include:

- A small ipsilateral lung
- A defect in the ipsilateral diaphragm
- A shift of the mediastinum away from the affected side.

Identification of abnormal upper abdominal and presence of peristalsis in herniated bowel loops helps distinguish congenital diaphragmatic hernia from other diagnoses.

After CDH is identified, the fetus is studied for additional anomalies by thorough scanning of the head, spine, heart and kidneys. Amniocentesis or villus biopsy is performed to screen for chromosomal and metabolic anomalies. Associated anomalies are seen in 25% to 57% of all cases of CDH and 95% of stillborns with CDH and include:

- congenital heart defects
- hydronephrosis
- renal agenesis
- intestinal atresia
- extralobar sequestrations
- neurologic defects, including:
  - hydrocephalus,
  - encephalocele,
  - anencephaly,
  - spina bifida.

Chromosomal anomalies, including trisomy 21, 18 and 13, occur in association with CDH in 10% to 20% of cases diagnosed prenatally.

#### POSTNATAL DIAGNOSIS

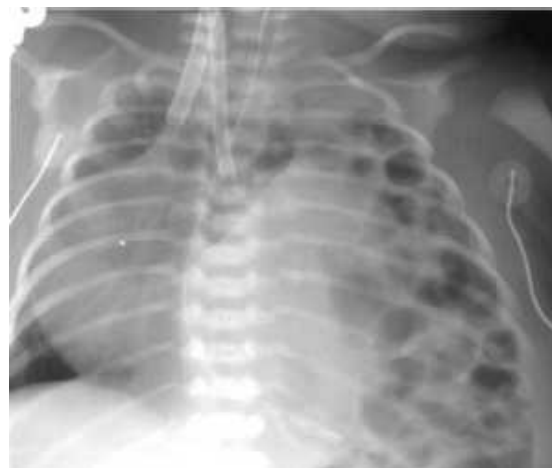The typical neonate with CDH presents within hours of birth with severe respiratory distress. The following are the most *common symptoms* of a CDH:

- difficulty breathing
- fast breathing
- fast heart rate
- cyanosis
- scaphoid abdomen
- shifting of the heart sounds to the right and bowel sounds in the chest.

Gastrointestinal symptoms of abdominal pain, nausea and vomiting may be from compression of the bowel through the diaphragm, producing obstruction, or from gangrene of the bowel, with or without volvulus.

The definitive diagnosis is usually made by *chest X-ray*, which shows bowel loops in the chest and a significant mediastinal shift. A chest radiograph should be obtained, preferably after an orogastric tube has been passed into the stomach.

If the radiograph is taken before air enters the bowel, the affected chest is radiopaque, but the trachea and heart are shifted to the contralateral side and the aerated lung is diminished.



Although most infants with CDH present in the first 24 hours of life, some can appear later. These children have a variety of presentation including mild respiratory distress, an incidental finding in chest radiograph, chronic pulmonary disease, pneumonia, pleural effusion, empyema or gastric volvulus. Presentation with gastric volvulus is worthy of emphasis because it is an indication for emergent surgical intervention.

#### DIFFERENTIAL DIAGNOSIS

The prenatal and neonatal diagnosis of CDH can be confused with a variety of other lesions including:

- the eventration of the diaphragm
- pentalogy of Cantrell
- Morgagni hernia
- congenital cystic disease of the lung
- primary agenesis of the lung
- mucoviscidosis
- esophageal atresia
- pneumothorax
- tracheomalacia

Diaphragmatic eventration has many causes, but in newborn, it commonly results from birth trauma or Wernig-Hoffman anterior horn-cell disease. The physiologic consequences are quite variable, ranging from asymptomatic infants to acute respiratory distress.

A Morgagni hernia occurs in the anterior muscular diaphragm at the hiatus for the internal mammary artery and is rarer than the Bochdalek hernias. Affected infants can

present with gastrointestinal crisis because of incarceration and need emergent surgery; most are asymptomatic.

**TREATMENT**

**PRENATAL TREATMENT**

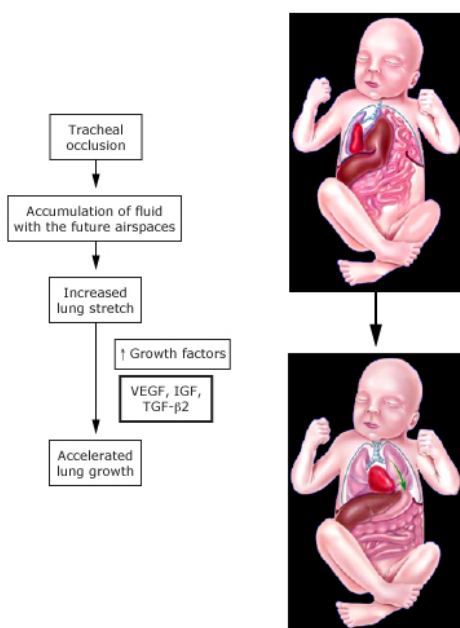
The advantage of prenatal diagnosis is not so much for surgical preparation as it is for educating parents about possible treatments and outcomes. It also allows the fetus and mother to be referred safely to an appropriate level III tertiary perinatal center where the full array of respiratory care expertise and strategies are immediately available.

<sup>3</sup>As a matter of principle, a spontaneous vaginal delivery is preferred unless obstetric issues supervene. The mere diagnosis of CDH is not an indication for elective cesarean section.

Correction of the lung compression using open fetal surgery permits sufficient lung growth to support respiratory function at birth. Morphometric analysis of the lung in this model has confirmed that *in utero* repair results in improved lung growth and reversal of the characteristic pulmonary vascular changes.

In the animal models of CDH, <sup>8</sup>tracheal occlusion induces lung growth, increases alveolar surface area and alveolar number, as well as visceral reduction from the chest. The results of these experiments were so compelling that the fetal occlusion was applied in human fetuses with severe CDH.

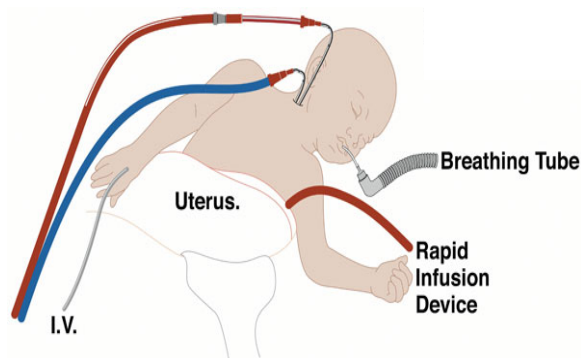
The fetal lung secretes fluid by active ion transport through gestation, and this lung fluid provides a template for lung growth. Occlusion of the fetal trachea traps this fluid and stimulates lung growth, either by retention of growth factors within the lung or stimulation of local growth factors by the gentle distension provided by the fluid. A randomized trial in humans found that tracheal occlusion did not improve outcome compared with standard treatment.



As a result of the poor outcomes with the procedure, a procedure was described using transuterine endoscopy or FETENDO. The results from the FETENDO<sup>10</sup> approach in high risk CDH were promising. Shortly after initiation of the FETENDO trial for CDH it is developed a less invasive endoluminal balloon tracheal occlusion technique<sup>9</sup>.

Depending on the nature of CDH, the fetus may be a candidate for reversible balloon tracheal occlusion or EXIT-to-ECMO (ex utero intrapartum treatment to extracorporeal membrane oxygenation) procedures, both of which are types of fetal surgical intervention.

Some prognostic information may be gained by noting the gestational age at diagnosis, the presence of polyhydramnios and the size of the defect.



**PREOPERATIVE TREATMENT**

<sup>1</sup>Newborn infant who present with respiratory insufficiency require endotracheal ventilatory support. Initial mask ventilation is avoided, because insufflation of air is produced into the stomach and bowel.

As soon as endotracheal ventilation is achieved, the baby is paralyzed to facilitate ease of ventilation without the baby struggling and displacing bowel into the chest. The stomach is decompressed with a nasogastric tube which is connected to a vacuum. The ventilatory pressures must be carefully restricted to less than 45 mmHg.

Appropriate fluid management and monitoring with central venous and urinary catheters is important. Umbilical artery and right atrial catheters are inserted. Cannulation of the right radial artery is desirable to detect any difference in the PaO<sub>2</sub> in the aorta, proximal and distal to the ductus arteriosus. When the PaO<sub>2</sub> in the distal aorta is lower than that in the right radial artery, pulmonary hypertension and/or hypoplasia is present.

The objective of ventilation is to maintain the postductal PaO<sub>2</sub> above 40mmHg, the PaCO<sub>2</sub> less than 30mmHg and the pH greater than 7.5 to achieve maximum pulmonary vasodilatation.

A small number of babies have minimal to moderate respiratory distress, which responds well to ventilation. A larger number are born in extremis, are never resuscitable and die within the first few hours or days of life. There is a middle group, who have a brief “honeymoon period” after which rapid deterioration takes place. This is

probably due to vasoconstriction of the abnormally reactive pulmonary vascular bed.

A battery of pharmacological agents was used in an attempt to decrease pulmonary vascular resistance. These drugs contribute to capillary leak, hypovolemia and systemic hypotension.

More recently, nitric oxide has been used as a selective pulmonary vasodilator when added to ventilatory gases. This agent is rapidly degraded so that systemic hypotension does not occur.

Some authors have suggested surfactant replacement, because there is some evidence that infants with CDH may be surfactant deficient. None of these approaches, appears to have had a major impact.

<sup>2</sup>There are three new techniques which have some promise to improve survival in CDH:

1. ECMO - the patient's blood is perfused through a membrane oxygenator for gaseous exchange and then returned to the patient. The blood may be withdrawn from the right atrium and returned to the venous circuit, but the most frequent technique is to return it to the arterial circuit. An incision in the neck gives access to the deep jugular vein, where a large-bore catheter with multiple holes can be passed into the right atrium. A common carotid arteriotomy allows passage of a cannula into the arch of the aorta. The venous blood is drawn by gravity into a reservoir. The blood is pumped around a silicone rubber membrane, which is permeable to oxygen and carbon dioxide. While the patient is on by-pass, the lungs are ventilated at a rate of 10 times per minute.

A peak inspiratory pressure (PIP) is used at 20 cm H<sub>2</sub>O and the positive end-expiratory pressure (PEEP) is used at 5 cm H<sub>2</sub>O. This pressure places the lungs at relative rest while they are expanded for expected ideal blood flow and ventilation.

The most serious complication is intracranial bleeding, which is much more common in premature infants.

Indications for neonatal ECMO<sup>2</sup>:

- Oxygenation index > 25
- No congenital anomaly incompatible with normal life
- Gestational age > 35 weeks
- Mechanical ventilation less than 7-10 days
- No evidence of intracranial haemorrhage
- In CDH evidence of a 'honeymoon period'

Several investigations have reported a survival of greater than 70% using ECMO in selected high-risk newborns with CDH.

2. HFO (HIGH FREQUENCY OSCILLATION) is being used experimentally in respiratory distress syndrome and meconium aspiration, with encouraging preliminary results. There is good evidence that HFO permits ventilation with a lower mean airway pressure.

3. DELAYED SURGICAL REPAIR OF CDH has many advantages. Although it had been assumed for many years that immediate operation to decompress the chest was necessary, there are a number of problems with this approach. Ventilatory management is not as good during transport to and from the operating room, infants often

deteriorate after surgery. After paralysis and positive pressure ventilation, it is common on chest X-ray to see the lungs expand, the mediastinal shift resolve and the bowel move down into the abdomen.

Sakai and colleagues have shown that surgical repair of the defect actually worsens thoracic compliance and PCO<sub>2</sub>, suggesting that emergency repair may be harmful to the already borderline infant.

Repair of the hernia does not increase the surface area available for gas exchange in hypoplastic lungs. The alveoli are not atelectatic and do not expand upon decompression of the chest.

A consensus has developed recently that surgery be performed when pulmonary vascular tone is maximally stabilized. This is followed by preductal-postductal oximetry. Recent reports on infant with CDH studied by whole body plethysmography during prolonged preoperative resuscitation demonstrate that infant minute ventilation improves with decreased mechanical support over the first several days of life with concomitant improvement in blood gas parameters.

A timely operation can often be performed after 100 hours with minimal supplemental oxygen and airway pressure requirements, particularly if therapy is guided primarily by preductal oxygen saturation.

### SURGICAL REPAIR

*It is essential to consider that CDH is a physiologic, not a surgical emergency!*

Repair of the defect is usually the most straightforward part of the management of CDH. Preoperative antibiotics are usually used. Blood should be available.

<sup>1</sup>Once the infant has stabilized, a general anesthetic using halothane and pancuronium bromide (Pavulon) is preferred to minimize vasoreactivity.

Through a left subcostal abdominal incision, the defect is exposed and the viscera are pulled down out of the chest. The stomach, the spleen, part of the pancreas, the small bowel and the proximal colon are often in the chest.

The spleen on the left and the liver on either side can be difficult to reduce, but this must be done without injury. On the right side, the kidney and adrenal gland may be found in the chest.

When there is a true hernia sac with a membrane of parietal pleura and peritoneum, this should be resected to achieve adequate healing.

Usually the anterior rim of the diaphragm is better developed than the posterior component. The posterior aspect of the defect is covered by peritoneum. An incision is made in the peritoneum posteriorly and the posterior muscular edge freed to develop as much posterior diaphragm as possible.

Much of the time it is possible to carry out direct closure using interrupted non-absorbable sutures. The one found to be most secured is a vest-over-pants closure using horizontal mattress sutures as the first row and then a simple suture between each of these to reinforce the first suture line.

In some cases, the defect is too large for primary closure and prosthetic material (Gortex or Marlex) is used.

An alternative to this approach is a muscle flap taken from the transversus abdominus, leaving the outer abdominal muscle layers intact.

The lateral rim may be absent, making it necessary to put the lateral sutures either around the rib or into the intercostal muscle.

Procedure for nonrotation of the midgut as well as appendectomy is not needed and potentially dangerous because of the risk for hemorrhage.

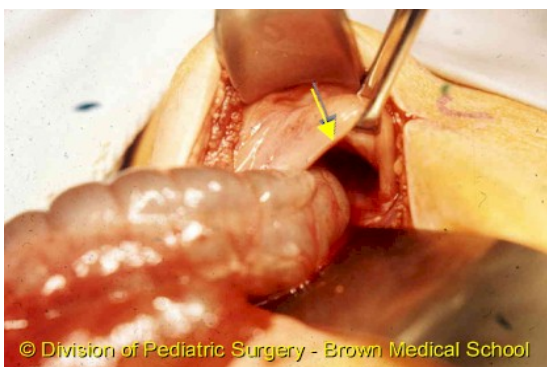
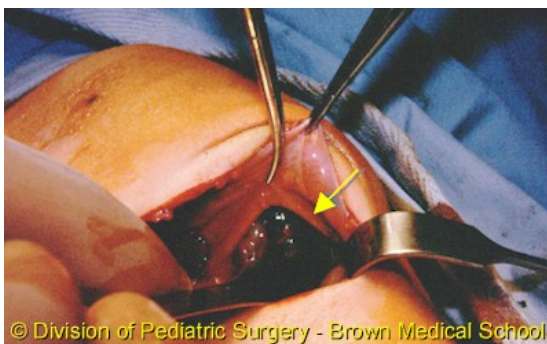
Prior to closure, the abdomen is manually stretched to make room for the herniated viscera. Wound closure may be difficult, because the peritoneal cavity is small; on occasion, a Silastic gusset is required for abdominal wound closure. Primary closure in layers is usually possible.

A tube thoracostomy is generally not needed in either hemithorax for the CDH infant, unless there is a pneumo-thorax, a bronchopleural fistula, bleeding or some other specific indication. The ipsilateral lung is hypoplastic and hence smaller than that hemithorax. Because the pleural space is driven to obliterate itself, and because the lung is not yet capable of filling it, the remaining space will be filled with pleural fluid.

If a chest tube is used, it is important to avoid applying suction, as it increases the transpulmonary pressure gradient and predispose to pneumothorax.

<sup>3</sup>**LUNG TRANSPLANTATION** - may be an option for the infant with severe pulmonary hypoplasia, who is truly refractory to all forms of therapy.

Transplantation of a single lung has been reported in one case. Lung transplantation may allow the remaining hypoplastic lung to grow and to recover from injury while still allowing adequate oxygenation and ventilation. This approach has not been widely used because of the substantial problems associated with donor lung availability and immunosuppression.



## POSTOPERATIVE CARE

<sup>1</sup>It is primarily based on close fluid management, ventilatory support, which often requires paralysis and haemodynamic monitoring:

- The chest tube is connected to a water seal
- The ventilatory care continues postoperatively with the goal of maintaining hypocarbia and a pH greater than 7.5
- In the first 24 to 48 hours postoperatively, intravenous fluid infusions consists of
- Ringer lactate solution

Depending on the previous intensity of hypoxia, cardiomyopathy and renal failure may occur.

## FOLLOW-UP

### Pulmonary care

Severely affected infants have chronic lung disease.

These infants may require prolonged therapy with supplemental oxygen and diuretics, an approach similar to that for bronchopulmonary dysplasia.

Late pulmonary hypertension has been successfully treated with low-dose inhaled nitric oxide. This therapy can be delivered via nasal cannula following extubation. In a recent report, the median duration of treatment using inhaled NO delivered via nasal cannula was 17 days.<sup>4</sup>

### Neurologic evaluation

The incidence of hearing loss appears to be particularly high in patients with CDH (approximately 40% of infants). An automated hearing test should be performed prior to discharge.

### Gastroesophageal reflux

The incidence of significant gastroesophageal reflux is very high in patients who survive CDH (45-85%). The need for a diaphragmatic patch may be a significant predictor of gastroesophageal reflux.

### Growth assessment

Failure to thrive is common. In one study, one third of infants required gastrostomy tube placement to improve caloric intake. The need for supplemental oxygen at the time of discharge is a significant predictor for subsequent growth failure. Possible causes include increased caloric requirements due to chronic lung disease, oral aversion after prolonged intubation, poor oral feeding due to neurologic delays and gastroesophageal reflux.

## PROGNOSIS

Of those pediatric patients who are born alive at a medical center where the operative treatment is undertaken, the mortality exceeds 60 to 65%.

Those infants who are symptomatic at birth and who survive transport to a pediatric surgical center have a mortality of 35 to 50%.

The mortality is much greater in babies who require urgent treatment within the first 6 to 24 hours of life compared with older babies.

<sup>4</sup>Survivors are at risk for significant longterm morbidity, including chronic lung disease, growth failure, gastroesophageal reflux, hearing loss and neurodevelopmental delay.

**References**

1. Ashcraft KW, Holder TM: Textbook of Pediatric Surgery 2<sup>nd</sup> Edition, 1995
2. Prem Puri: Newborn Surgery, 1996
3. Keith T. Oldham, Paul M. Colombani, Robert P. Foglia: Surgery of Infants and Children-Scientific Principles and Practice
4. Cortes RA, Keller RL, Townsend T: Survival of severe CDH has morbid consequences. *J. Pediatr. Surg* 2005 Jan
5. Adzick NS, Harrison MR: The unborn surgical patient. *Curr. Prob. Obstet. Fertil* 18:173, 1995
6. Bootstaylor BS, et al: Prenatal sonographic predictors of liver herniation in CDH. *J Ultrasound Med* 14:515, 1995
7. Flake AW: Fetal surgery for CDH. *Semin. Pediatr. Surg* 5:266, 1996
8. Harrison MR, et al: Correction of CDH in utero. V. Initial experience. *Journal of Pediatric Surgery* 25:47, 1990

Correspondence to:

Ramona Mandrusca  
Dr. Iosif Nemoianu Street, No. 2,  
Timisoara,  
Romania  
Phone: +40723012975  
E-mail: adi\_mandrusca@yahoo.com