

IV. PEDIATRIC SURGERY

SURGICAL TREATMENT OF GASTROSCHISIS USING SILIMED GASTROSCHISIS CONTAINER - CASE REPORT

ES Boia¹, RE Iacob¹, O Adam², A Pavel², Maria Trailescu², Marioara Boia¹, Nicoleta Pavel³

¹University of Medicine and Pharmacy “Victor Babes” Timisoara

²Clinical Emergency Hospital for Children “Louis Turcanu” Timisoara - Pediatric Surgery and Orthopedics Department

³Special Services for Children with Disabilities Timisoara

Abstract.

Gastroschisis is a defect of the abdominal wall, on the right side of the umbilical cord, where evisceration of intestinal loops.^[2] The vertical opening is approximately 2 to 5 cm in size, with the umbilicus normally developed and properly positioned.^[4,5] The small and large intestines are usually the only organs protruding outside the abdominal wall. The spleen and liver may also be involved, but with a much lower incidence.^[6] Malformations of other major organ systems are infrequently associated with gastroschisis; however, if malformations occur, they are commonly related to infarction or atresia of the herniated bowel.^[7]

Key words: gastroschisis, silimed gastroschisis container.

Introduction

The etiology of gastroschisis is uncertain, but it has been reported to be of nongenetic origin.^[8] Four hypotheses for the etiology of the defect have been proposed. The first is that gastroschisis may result from a vascular disruption of the right lateral fold allowing the abdominal contents to herniate outside the abdominal cavity.^[2] The second is that the defect results from occlusion of the omphalomesenteric artery in utero. This occlusion may weaken the abdominal wall causing it to rupture.^[4] The third hypothesis is that premature atrophy or abnormal persistence of the right umbilical vein leads to mesenchymal damage and failure of the epidermis to differentiate.^[9] This damage or differentiation failure results in a defect of the abdominal wall. The fourth and last hypothesis is that a gastroschisis defect may be the end result of an intrauterine rupture of a small omphalocele with the absorption of the sac.^[7]

The incidence of gastroschisis ranges from 1.4 to 2.5 per 10,000 live births and has no gender predilection.^[7,9,10,12]

Factors associated with an increased risk for gastroschisis include maternal age, parity, and maternal use of selected drugs. The incidence of gastroschisis is higher in young mothers and declines markedly with increasing maternal age.^[1,2,13] Women less than 20 years of age are 11 times more likely to have an affected infant.^[5] Low parity has also been shown to increase the risk for gastroschisis.^[2] Drugs taken during the first trimester including nicotine, pseudo-

ephedrine alone or in combination with acetaminophen, phenylpropanolamine, cocaine, aspirin, and acetaminophen are associated with an increased incidence of gastroschisis.^[5,15-17]

With advancements in prenatal testing and ultrasonography, abdominal wall defects are commonly diagnosed in utero as early as 12 to 14 weeks gestation.

The differential diagnosis of abdominal wall defects includes gastroschisis and omphalocele. Gastroschisis is a defect in the abdominal wall lateral to the umbilical cord, whereas omphalocele is a defect in which the intestines are enclosed within the umbilical cord. It may be difficult to distinguish between the two diagnoses if the protective sac of the omphalocele has been ruptured.^[3,19] It is important to remember that gastroschisis defects do not involve the umbilical cord. It is also essential to distinguish between the two defects because there is a higher incidence of major congenital/chromosomal anomalies associated with omphalocele.^[7] The incidence of chromosomal anomalies associated with gastroschisis is less than 5%.^[4]

The infant with gastroschisis typically presents with a small, underdeveloped abdominal cavity caused by evisceration of the intestines. Although the distal portions of the colon, liver, and other solid organs have the potential to protrude through the abdominal wall defect, these organs usually remain in the abdominal cavity.^[19] Malrotation occurs almost universally because of the protrusion of the intestines outside the abdominal wall.^[20] Exposure to amniotic fluid can cause the uncovered bowel to become inflamed, thickened, and edematous. The affected bowel can also appear as a matted mass with no identifiable loops. A peel over the serosal surface of the bowel can occur as a result of amniotic fluid exposure. This, in conjunction with a chemical peritonitis, may impede reduction of the intestine into the abdominal cavity.^[4,19,21]

There is a lower incidence of associated anomalies with gastroschisis compared with other abdominal wall defects. A 10-year review of infants with gastroschisis found a 30% incidence of associated anomalies with intestinal atresia and cryptorchidism or undescended testes being the most common.^[22] Intestinal atresia was noted in 22% of affected infants, while cryptorchidism was noted in 55%.^[22]

In a second 10-year review of infants with gastroschisis, ileal atresia occurred in 5.4% of affected infants and cryptorchidism occurred in 24%.^[14] Cryptorchidism in infants with gastroschisis has an estimated occurrence of 31%.^[23] Cryptorchidism is considered a minor anomaly that usually requires conservative management.^[23]

While the goal of delivery of the newborn with gastroschisis is to optimize their outcome by minimizing trauma to the exposed gastrointestinal contents, the best mode of delivery for these infants remains controversial. From a theoretical standpoint, one might assume delivery by cesarean section would be more advantageous than vaginal delivery for several reasons. The first reason is a cesarean delivery is thought to produce less compromise to the mesenteric circulation because there may be less compression and twisting of the bowel during uterine contractions and passage through the birth canal. Another reason is that the risk of infection to the exposed bowel is decreased by cesarean delivery with intact membranes. The last theoretical disadvantage to vaginal delivery is if a large defect is present with possible liver involvement, there may be an increased risk for avulsion injury.

While the rationale to promote cesarean delivery of the newborn with gastroschisis makes sense from a theoretical standpoint, none of these assumptions have been confirmed by clinical data.^[24] No significant differences in outcomes between cesarean and vaginal delivery were noted in several studies of morbidity associated with gastroschisis and type of delivery.^[22,25,26] The measures of morbidity in these studies included time to full oral feedings, duration of parenteral nutrition, age at discharge, incidence of complications, and number of hospital days.^[22,25]

Presurgical management. Stabilization and preoperative management of the newborn with gastroschisis must take into consideration many factors, including thermoregulation, fluid volume status, gastric distention and intestinal compromise, infection, respiratory status, and preparation for surgery. Stability of the aforementioned factors is necessary before the impending surgical repair to optimize the infant's outcome.

The infant must be monitored for signs of hypothermia, respiratory distress, and shock. A thorough physical examination should also be performed to determine the presence of other anomalies.^[3,7]

Delivery room management of the infant with gastroschisis has included the use of saline-soaked gauze dressings to prevent damage to the exposed intestines.^[29] The bowel bag is the most appropriate alternative.^[28] Bowel bags provide a sterile environment for the exposed intestine and reduce the risk for contamination and tissue trauma. In addition, the bowel bag helps to prevent evaporative heat and fluid losses and enables pooling of fluid within the bag. This pooling of fluid can be measured to provide a more accurate assessment of fluid loss.^[28]

Once initial stabilization in the delivery room is achieved, the newborn is admitted to the neonatal intensive care unit (NICU) for further evaluation and stabilization before surgical repair. Because the newborn with gastroschisis is at an increased risk for fluid loss because of the large surface area of exposed bowel, the newborn may

present with symptoms of shock.^[30] Fluid resuscitation with isotonic solutions such as normal saline or Ringer's lactate is recommended for the newborn in shock.^[31,32] Fluid resuscitation is usually continued until the infant's urine output normalizes and/or blood gases indicate normal acid-base balance.^[31]

The infant must be continually assessed for signs of gastrointestinal compression before surgical repair. A naso/orogastric tube should be inserted and placed to intermittent suction to keep the bowel and stomach decompressed.^[29,33]

Decompression is important because it helps to prevent partial or total obstruction of blood flow and oxygenation to the bowel. If decompression does not occur, there is an increased risk for bowel necrosis secondary to the constriction of the exteriorized intestine through the small visceral defect. Decompression will also reduce the infant's risk for emesis and thus aspiration.^[33]

Bowel compromise can occur during positioning of the infant. Infants with gastroschisis should be positioned on their right side in a lateral decubitus position to enhance venous blood return from the gut.^[29] The right lateral decubitus position also decreases the risk of decreased perfusion caused by compression or kinking of mesenteric vessels.^[20]

Diagnostic testing and antibiotic prophylaxis are the last two areas of presurgical management. While the specific tests may vary from NICU to NICU, the most common presurgical studies ordered include a baseline chest x-ray, complete blood count (CBC) with differential and platelets, serum electrolytes, blood glucose level, total protein, and a blood type and cross match.^[3] Broad-spectrum antibiotics such as ampicillin and gentamicin are started to decrease the risk of infection from bacterial contamination of the exposed bowel.^[33,34]

Surgical management of the infant with gastroschisis remains controversial. While primary closure of the abdominal defect is the preferred surgical approach, each pediatric surgeon must subjectively assess the degree of abdominal wall tension anticipated before deciding the nature of the repair.^[8,22] If primary closure cannot be obtained, the alternative management strategy is a staged silo repair.^[31] In a small or medium size gastroschisis, one staged repair includes returning the bowel contents into the abdomen and closing the skin. If the gastroschisis is large, or there are other problems, it may need to be closed in a staged procedure over 7-10 days. A silastic sheet (silo) is placed around the exposed bowel. Every day, the silo is tightened to push more bowels into the baby's abdomen. The silo is then removed and the skin on the baby's abdomen is closed.

Because of the increased risk of sepsis and hypovolemic shock, primary closure is considered in all cases where reduction does not cause hemodynamic or respiratory compromise.^[7,33] Airway and intra-abdominal pressures should be kept less than 25 and 20 mm Hg, respectively, to prevent adverse hemodynamic consequences to other organs and tissues.^[7] Strategies to achieve primary repair include stretching of the abdominal wall, evacuating the contents of the stomach and small bowel, irrigating

meconium from the intestines, and enlarging the defect by leaving a fascial hernia.^[20,35] If primary closure is attempted without sufficient space in the abdominal cavity, potential complications secondary to abdominal compartment syndrome may occur.^[36,37] If the surgeon is unable to achieve primary closure or if a primary closure leads to hemodynamic and/or ventilatory compromise, an alternative method of closure must be used. Currently, most surgeons use a silastic silo for gradual reduction of herniated abdominal contents. Secondary closure occurs at a later time when the intestinal contents fit within the abdominal cavity.^[7,20] Closure of the silo is usually performed in stages over 7 to 10 days, with reduction of the silo occurring one to two times daily.

A variety of methods including umbilical tape ties, sutures, clamps, or staples are used for silo reduction.^[20,38] While slow reduction of the silo reduces the risk of abdominal compartment syndrome, the nurse must remember that the infant remains at risk for complications associated with abdominal compartment syndrome. The infant should be carefully assessed during and immediately after the reduction for complications. Initial postsurgical management of the infant with gastroschisis includes monitoring of vital signs, cardiovascular and respiratory status, fluid and electrolyte balance, and pain. After the repair, intra-abdominal pressure increases and can result in venous compression. Venous compression may compromise renal blood flow and the glomerular filtration rate, resulting in decreased urine output. A urinary catheter may be necessary to relieve bladder distention and to allow for a more accurate measurement of urine output.^[4] Maintenance fluid requirements may need to be increased because of third spacing into the distended bowel and abdominal cavity.^[29-31] Alterations in electrolyte balance may ensue from this shift of fluids. The postoperative infant may require anywhere from 120 to 170 mL/kg/d of a crystalloid solution that is adjusted to provide for adequate tissue perfusion and urine output.^[20] A large-bore naso/orogastric tube placed to intermittent suction is needed to prevent gastrointestinal distention caused by hypoperistalsis. Hypoperistalsis or adynamic ileus is frequently seen in the postoperative period and may persist for several weeks.^[29] The initial gastrointestinal drainage is characteristically green because of the back up of biliary and pancreatic secretions in the immediate postoperative period. As gut motility improves, the drainage becomes clear in appearance. Volume loss from the gastric tube must be monitored, because it is possible for the infant to lose up to 100 mL/kg/d.^[3] Replacement of these losses is necessary to maintain homeostasis.

Because of the increased intra-abdominal pressure, close monitoring of respiratory status is essential for the first 48 to 72 hours postsurgery. Respiratory support, as indicated, is provided to optimize oxygenation and ventilation. The increase in abdominal pressure may interfere with optimal expansion of the diaphragm and venous return impeding both ventilation and oxygenation.^[42] Some infants may benefit from mechanical ventilation or continuous positive airway pressure (CPAP) to maximize lung expansion, lung volume, and oxygenation.^[33] Other

infants may not tolerate CPAP because of increased abdominal distention from the increased airflow to the gastrointestinal track. A properly functioning naso/orogastric tube will minimize this risk.

In the **immediate postsurgical period**, the infant with gastroschisis is usually returned to the NICU from the operating room intubated and on mechanical ventilation. While most infants can be extubated within 24 to 48 hours after surgery, infants who are small for gestational age, preterm, and/or have significantly increased intra-abdominal pressure may require a longer period of ventilator support.^[31]

After the initial stabilization period, the main goal of management is to provide adequate nutrition and pain management. Initially, the infant will require parenteral nutrition. Gut motility is delayed because of the chemical peritonitis that occurred when the intestinal contents were exposed to amniotic fluid. Delayed gut motility may persist for weeks after surgical repair and is often influenced by the severity of the defect and other associated anomalies such as intestinal atresia.^[29,31]

Because of the postoperative ileus, total parenteral nutrition (TPN) is needed in all infants with gastroschisis and is usually initiated within 24 to 48 hours after surgery.^[29,33] Because these infants may require TPN for weeks after surgery,^[31] a central line is recommended. The minimal daily requirements for postoperative TPN are 90 to 100 kcal/kg/d, 3 g/kg/d of protein, 3 to 4 g/kg/d of intravenous lipids, and dextrose to maintain euglycemia.^[43] Because of protein losses from the surgical stress, wound healing, and/or third spacing, additional protein in the TPN may be necessary.^[43]

Once gut motility returns, it is important to be proactive with the initiation of enteral feedings. A retrospective study found the age of initial enteral feeding was positively correlated with the time of discharge.^[14] These investigators also noted that for every additional day enteral feedings were delayed, hospital length of stay was increased by 1 day. Infants with gastroschisis have a tendency toward malabsorption of substrates and possible allergies secondary to gut inflammation. The use of elemental formulas, expressed human milk, or preterm formulas are indicated because they are more easily digested.^[3,4,43] Typically, small volume feedings are initiated and advanced by 10 to 20 mL/kg/d as tolerated.^[43] TPN is usually decreased as the feedings increase.

Manipulation of bowel and the increase in intra-abdominal pressure postrepair may increase the need for analgesia in the first 48 to 72 hours after surgery.^[30] Infants should be routinely assessed for pain using a validated pain assessment tool, and analgesia should be provided as needed according to established pain guidelines.^[44] Pain may be controlled with analgesics such as morphine sulfate or fentanyl as a continuous intravenous drip or as a bolus at regularly scheduled intervals. The nurse should keep in mind that these medications may result in respiratory depression and slow gut motility.^[3]

Outcomes for the infant with gastroschisis are usually affected by a number of complications, including

cholestasis secondary to long term TPN, malrotation, midgut volvulus, hypoperistalsis, gastroesophageal reflux (GER), and aspiration pneumonia.^[3,7,14,22]

The most common complications resulting in increased morbidity and mortality include intestinal atresia/stenosis, sepsis, and necrotizing enterocolitis (NEC).^[45-49]

Intestinal atresia is seen in approximately 5% to 25% of newborns with gastroschisis.^[45] The development of intestinal atresia/stenosis occurs secondary to torsion and volvulus of the exteriorized bowel, causing a disruption of mesenteric vessels and blood flow to the affected intestine. The size of the defect may also cause strangulation of the bowel, increasing the risk for an atretic/stenotic area to arise.^[50] Intestinal atresia is difficult to diagnose before the time of closure because of the inflamed and matted appearance of the bowel. In the postoperative period, intestinal atresia/stenosis should be considered in all infants who present with poor feeding tolerance, abnormal stooling patterns, and/or abdominal distention with vomiting.

Infection is another complication associated with gastroschisis defects. Initially, the newborn is at risk for infection because of the breach in skin integrity from the exteriorized bowel. The risk is then increased postoperatively in infants with a staged repair because of delayed closure of the defect. Other factors contributing to the risk of sepsis include central venous access and the immaturity or incompetence of the neonatal immune system.

Postoperative interventions to prevent and/or minimize the risk of infection include continuation of broad-spectrum antibiotic therapy for an additional 3 to 7 days^[20] and a high index of suspicion for infection on the part of health care providers. The infant must be assessed for signs and symptoms of infection at the site of the repair, the site of central vascular access, and systemically. Aseptic dressing changes and constant monitoring of the wound site are necessary measures to decrease the risk for opportunistic infections.^[19]

Case report

We present the case of premature newborn male was born to a 18 year old G.I.P.I mother at 34 weeks gestation via cesarean section. Appropriate antenatal care and monitoring occurred throughout the pregnancy. Prenatal ultrasonography was done at 30 weeks gestation revealing free intestine floating in the amniotic fluid, coming from the anterior abdominal wall and right hydronephrosis. There was no maternal history of drug or alcohol abuse. The mother elected for a cesarean section delivery after fetal lung maturation was assured.

The baby looks normal at birth except for matted intestinal loops and the stomach coming through an anterior abdominal wall defect just to the right of the umbilical cord. The stomach, small bowel, and large intestine was outside of the hole. The bowel is matted, swollen, and shorter than normal. The loops were very edematous and don't resemble normal intestines (fig. 1).

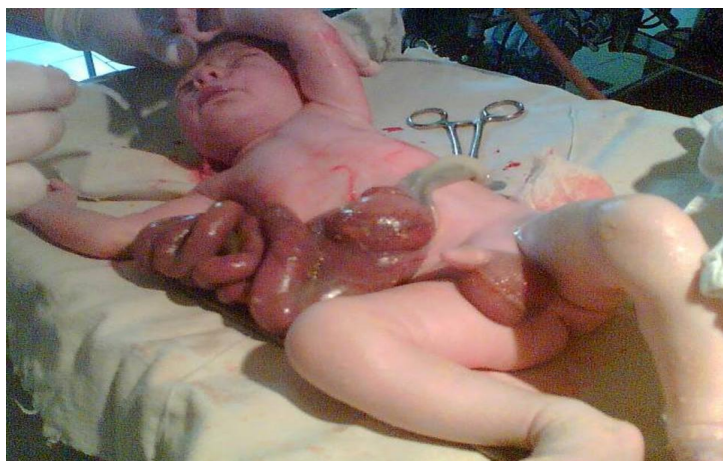

Figure 1: Typical gastroschisis with the hole just to the right of the umbilical cord.

Treatment in the delivery room includes evaluation of the vital functions, then the intestines are wrapped with saline soaked sterile gauze (well padded with no pressure), followed by dry sterile dressings to minimize heat loss.

The patient was transported in our section after 30 minutes where a pediatric surgeon is consulted. Laboratory evaluation showed normal levels of serum electrolytes and normal results of renal-function tests.

In the operating room, after induction of anesthesia, a urinary drainage catheter and a second IV line was placed. Arterial catheter placement in the radial artery was attempted, but failed. Instead, a 4 French catheter was placed into the umbilical artery via the umbilical cord. The

catheter was prepped in the surgical field. There were no complications related to the umbilical artery catheter. The stomach, small bowel, and large intestine was outside of the hole. The bowel was matted, swollen, and shorter than normal. The loops were very edematous and doesn't resemble normal intestines.

Because the cavity abdominal was very small in contrast with volume of intestinal loops eviscerated, for evited the abdominal sindrom compartiment, we decided for an siliconated prothesing of the defect, after excluding the intestinal atresia, using silimed gastroschisis container of five cm. diameter (O.P. 1809/08.10.2005).

The silo has a flexible ring at the bottom which is inserted inside the abdomen while the intestines sit inside of the bag. The bag is made smaller little by little which causes the intestines to go back into the abdomen. The bag is sterile, impermeable to micro-organisms, transparent, flexible, resistant, internally smooth, does not adhere to the bowel loops, readily available, and inexpensive, properties

that make it an excellent alternative as a prosthesis for staged surgical treatment of congenital anomalies of the abdominal wall such as gastroschisis.

The intestines was returned to the abdomen gradually by gentle pressure and placing the string which ties off the top of the silo gradually lower on the silo at the bedside in the NICU (fig.2,3).

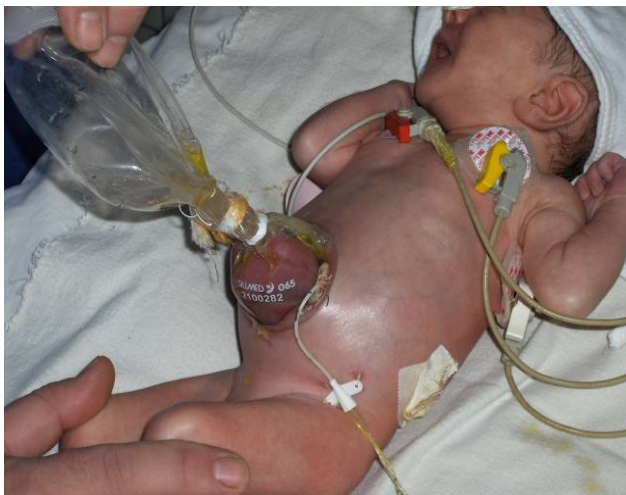

Figure 2: A newborn with gastroschisis with a silimed gastroschisis container of five cm. diameter- a 6-th day postsurgical.

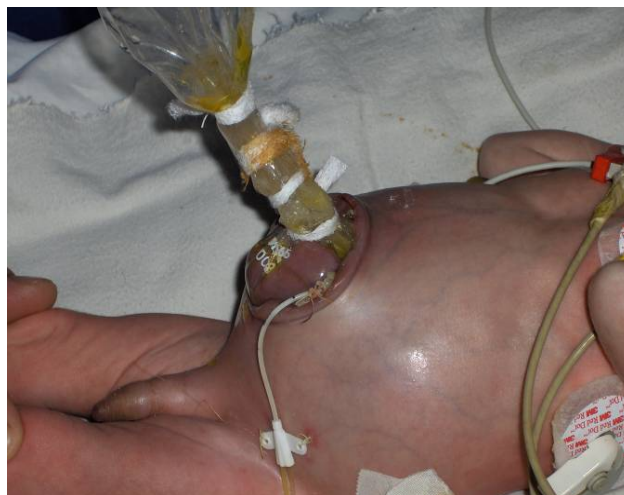

Figure 3: A newborn with gastroschisis with a silimed gastroschisis container of five cm. diameter- a 8-th day postsurgical.

Once the intestines are almost all back inside (this process was completed after 9 days in this case), the infant was returned to the operating room for closure of the gastroschisis (O.P. 1874/17.10.2005)

The silo was removed (fig. 4) and the hole in the abdomen closed, but because still was tension by the suture line we decided for lateroabdominal incisions (fig.5).

Antibiotics are discontinued shortly after the silo is removed.

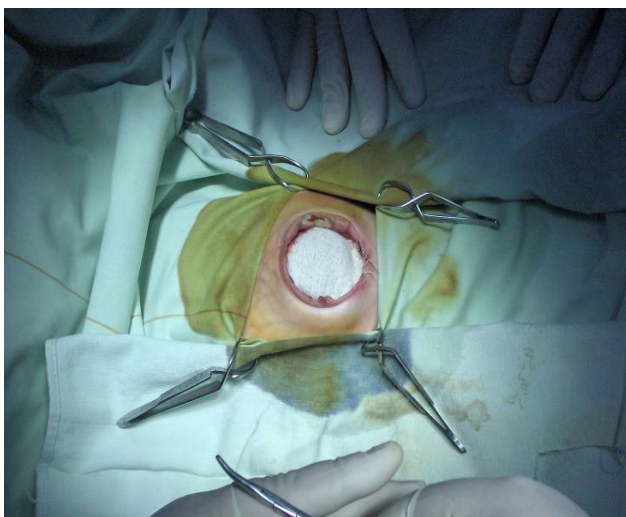


Figure 4: A newborn with gastroschisis after container removed - a 9-th day postsurgical.

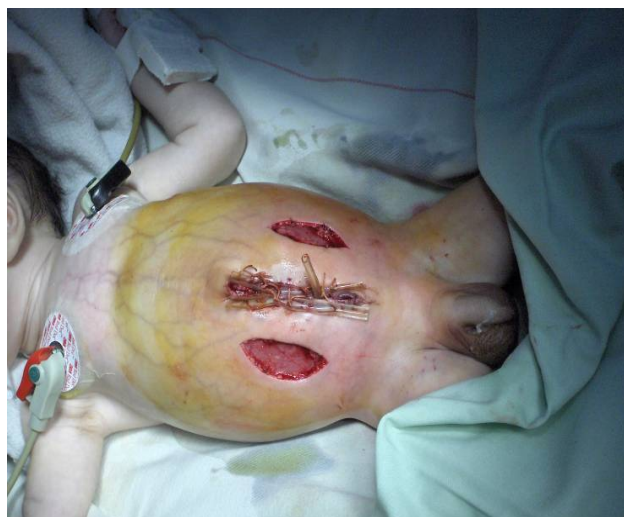

Figure 5: Closure of the abdominal wall.

The patient was supported with a ventilator for about 12 hours, then weaned to supplemental nasal oxygen at 1 week. The infant was initially maintained on peripheral total parenteral nutrition (TPN). Nasogastric suction was discontinued at 1 week and gesol solution begun, with the

use of a feeding tube. Two weeks before admission, fever, vomiting, shortness of breath, productive cough, and generalized weakness developed. The oxygen saturation was 88 percent while the patient was breathing ambient air.

This was progressed to half-strength, then full-strength, breast milk over a 2-week period. He was gradually weaned from continuous feeds to bolus and regular breastfeeding. The patient was discharged at 25 days of life. Her weight was 2400 grams at time of discharge. At 6 month of age, he had experienced normal growth and development.

Conclusions:

1. Gastroschisis is a rare, but complex, defect of the abdominal wall.
2. Surgical treatment using silimed gastroschisis container is an effective treatment in gastroschisis if the surgeon is unable to achieve primary closure leads to hemodynamic and/or ventilatory compromise.

3. While primary closure of the abdominal defect is the preferred surgical approach, each pediatric surgeon must subjectively assess the degree of abdominal wall tension anticipated before deciding the nature of the repair and the alternative management strategy is a staged silo repair.
4. There are numerous complications that may occur secondary to the evisceration of the intestines, requiring long-term follow-up.
5. With the advances seen in neonatal medicine, including surgical techniques, parenteral nutrition, respiratory support, and control of infection, these infants may go on to lead healthy and productive lives.

References

1. Molik K, Gingalewski CA, West KW, et al: Gastroschisis: A plea for risk categorization. *J Pediatr Surg* 36:51-55, 2001.
2. Torfs C, Curry C, Roeper P: Gastroschisis. *J Pediatr* 116:1-6, 1990.
3. Howell KK: Understanding gastroschisis: An abdominal wall defect. *Neonatal Network* 17:17-25, 1998.
4. Glasser JG: Omphalocele and Gastroschisis. *eMedicine* 2001;2: 1-23. Accessed February 25, 2002.
5. Martin RW: Screening for fetal abdominal wall defects. *Obstet Gynecol Clin North Am* 25:517-526, 1998.
6. Luton D, DeLaguasie P, Guibourdenche J, et al: Effect of amniocentesis on the outcome of prenatally diagnosed gastroschisis. *Fetal Diagn Ther* 14:152-155, 1999.
7. Puri A, Bajpai M: Gastroschisis and omphalocele. *Ind J Pediatr* 66:773-789, 1999.
8. Komuro H, Imaizumi S, Hirata A, et al: Staged silo repair of gastroschisis with preservation of the umbilical cord. *J Pediatr Surg* 33:485-488, 1998.
9. Khan AN, Thomas N: Gastroschisis. Accessed December 27, 2002. Di Tanna GL, Rosano A, Mastroiacovo R: Prevalence of gastroschisis at birth: Retrospective study. *BMJ* 325:389-390, 2002.
10. Curry J, McKinney P, Thornton J, et al: The aetiology of gastroschisis. *Br J Obstet Gynecol* 107:1339-1346, 2000
11. Boyd P, Bhattacharjee A, Gould S, et al: Outcome of prenatally diagnosed anterior abdominal wall defects. *Arch Dis Childhood* 78: F209-F213, 1998.
12. Stoll C, Alembik Y, Dott B, et al: Risk factors in congenital abdominal wall defects (omphalocele and gastroschisis): A study in a series of 265, 858 consecutive births. *Ann Genet* 44:201-208, 2001.
13. Sharp M, Bulsara M, Gollow I, et al: Gastroschisis: Early enteral feeds may improve outcome. *J Paediatr Child Health* 36:472-476, 2000.
14. Kozer E, Nikfar S, Costei A, et al: Aspirin consumption during the first trimester of pregnancy and congenital anomalies: A meta-analysis. *Am J Obstet Gynecol* 187:1623-1630, 2002.
15. Werler MM, Sheehan JE, Mitchell AA: Maternal medication use and risks of gastroschisis and small intestinal atresia. *Am J Epidemiol* 155:26-31, 2002.
16. Hume RF Jr, Martin LS, Bottoms SF, et al: Vascular disruption birth defects and history of prenatal cocaine exposure: a case control study. *Fetal Diagn Ther* 12:292-295, 1997.
17. Weaver LT: Anatomy and embryology, in Craven L (ed) *Pediatric Gastrointestinal Disease: Pathophysiology, Diagnosis, & Management* (ed 2). St Louis, MO, Mosby, 1996, p 9.
18. Brandt ML: Gastrointestinal surgical emergencies of the newborn, in Taeusch HW, Ballard RA (eds): *Avery's Diseases of the Newborn* (ed 7). Philadelphia, PA, WB Saunders, 1998, pp 979-994.
19. Kurkchubasche AG: The fetus with an abdominal wall defect. *Med Health RI* 84:159-161, 2001
20. Ortiz VN, Villareal DH, Olmo J, et al: Gastroschisis: A ten-year review. *Bolivian Assoc Med Periodical Rev* 90:69-73, 1998.
21. Lawson A, de la Hunt MN: Gastroschisis and undescended testis. *J Pediatr Surg* 36:366-367, 2001
22. Blakelock RT, Harding JE, Kolbe A, et al: Gastroschisis: Can the morbidity be avoided? *Pediatr Surg Intensivist* 12:276-282, 1997.
23. Anteby E, Yagel S: Route of delivery of fetuses with structural anomalies. *Eur J Obstet Gynecol Reprod Biol* 106:5-9, 2003.
24. Segel SY, Marder SJ, Parry S, et al: Fetal abdominal wall defects and mode of delivery: A systematic review. *Obstet Gynecol* 98(5 Pt 1):867-873, 2001.
25. Strodbeck F: Abdominal wall defects. *Neonatal Network* 17:51-53, 1998
26. Rescorla FJ: Surgical emergencies in the newborn, in Polin RA, Yoder MC, Burg FD (eds): *Workbook in Practical Neonatology* (ed 3). Philadelphia, PA, WB Saunders, 2001, pp 423-459
27. Hartman GE, Boyajian MJ, Choi SS, et al: General surgery, in Avery GB, Fletcher MA, MacDonald MG (eds): *Neonatology: Pathophysiology and Management of the Newborn* (ed 5). Philadelphia, PA, Lippincott, Williams & Wilkins, 1999, pp 1005-1044
28. Gaines BA, Holcomb GW, Neblett WW: Gastroschisis and omphalocele, in Ashcraft KW (ed): *Pediatric*

- Surgery (ed 3). Philadelphia, PA, WB Saunders, 2000, pp 639- 653.
29. Langer JC: Gastroschisis and omphalocele. *Semin Pediatr Surg* 5:124 -128, 1996.
 30. Diaz JH: Intraoperative management, in Goldsmith JP, Karotkin EH (eds): *Assisted Ventilation of the Neonate* (ed 3). Philadelphia, PA, WB Saunders, 1996, pp 409-435
 31. Berseth CL: Disorders of the umbilical cord, abdominal wall, urachus, and omphalomesenteric duct, in Taeusch HW, Ballard RA (eds): *Avery's Diseases of the Newborn* (ed 7). Philadelphia, PA, WB Saunders, 1998, pp 933-940.
 32. Dolgin SE, Midulla P, Shlasko E: Unsatisfactory experience with 'minimal intervention management' for gastroschisis. *J Pediatr Surg* 35:1437-1439, 2000.
 33. Watson RA, Howdieshell TR: Abdominal compartment syndrome. *South Med J* 91:326 -332, 1998.
 34. Vanamo K: Silo reduction of giant omphalocele and gastroschisis utilizing continuous controlled pressure. *Pediatr Surg Intensivist* 16:536 -537, 2000.
 35. Kimble RM, Singh SJ, Bourke C, et al: Gastroschisis reduction under analgesia in the neonatal unit. *J Pediatr Surg* 36:1672-1674, 2001.
 36. Bianchi A, Dickson AP: Elective delayed reduction and no anesthesia: "minimal intervention management" for gastroschisis. *J Pediatr Surg* 33:1338 -1340, 1998
 37. Davies MW, Kimble RM, Woodgate PG: Ward reduction without general anesthesia versus reduction and repair under general anesthesia for gastroschisis in newborn infants. *Cochrane Database Syst Rev* 3:CD003671, 2002
 38. Dimitriou G, Greenought A, Griffin F, et al: Temporary impairment of lung function in infants with anterior abdominal wall defects who have undergone surgery. *J Pediatr Surg* 31:670 -672, 1996
 39. Valentine CJ: Congenital anomalies of the alimentary tract, in Groh-Wargo S, Thompson M, Cox J (eds): *Nutritional Care for High-Risk Neonates*, Chicago, IL, Precept Press, 2000, pp 439- 455
 40. Walden M: *Pain Assessment and Management: Guideline for Practice*. Glenview, IL, National Association of Neonatal Nurses, 2001
 41. Driver CP, Bruce J, Bianchi A, et al: The contemporary outcome of gastroschisis. *J Pediatr Surg* 35:1719 -1723, 2000
 42. Fleet MS, de la Hunt MN: Intestinal atresia with gastroschisis: A selective approach to management. *J Pediatr Surg* 35:1323-1325, 2000.
 43. Sai Prasad TR, Bajpai M: Intestinal atresia. *Ind J Pediatr* 67:671- 678, 2000
 44. Snyder CL: Outcome analysis for gastroschisis. *J Pediatr Surg* 34:1253-1256, 1999.
 45. Ogunyemi D: Gastroschisis complicated by midgut atresia, absorption of bowel, and closure of the abdominal wall defect. *Fetal Diagn Ther* 16:227-230, 2001.
 46. Jayanthi S, Seymour PL, Puntis JW, et al: Necrotizing enterocolitis after gastroschisis repair: A preventable complication? *J Pediatr Surg* 33:705-707, 1998.
 47. Oldham KT, Coran AG, Drongowski RA, et al: The development of necrotizing enterocolitis following repair of gastroschisis: a surprisingly high incidence. *J Pediatr Surg* 23:945-949, 1988
 48. Tunell WP, Puffinbarger NK, Tuggle DW, et al: Abdominal wall defects in infants. Survival and implications for adult life. *Ann Surg* 221:525-530, 1995
 49. Koivusalo A, Lindahl H, Rintala RJ: Morbidity and quality of life in adult patients with a congenital abdominal wall defect: a questionnaire survey. *J Pediatr Surg* 37:1594 -1601, 2002
 50. E.S.Boia, Marioara Boia: *Urgențe chirurgicale neonatale*.Ed. Popa's Art,1995.

Correspondence to:

Eugen Boia,
Gospodarilor Street, No. 42,
Timisoara 300778,
Romania,
E-mail: boiaeugen@yahoo.com