

GIANT PEDICULATE LIPOMA OF THE ANTERIOR NECK

HI Osakwe¹, RE Iacob¹, Z Moldovan¹, M Soiu¹, Maria Trailescu¹, R Mejd²

¹County Emergency Hospital Arad (Dept. of Pediatric Surgery), Arad, Romania

²University of Medicine and Pharmacy Timisoara, Romania

Abstract

Background: Lipomas are common benign soft tissue tumors that are found rarely on the anterior part of the neck. Surgical interventions in these tumors are very challenging because of the proximity of the blood vessels and the vagus nerve and this knowledge of the anatomy and meticulous surgical technique are essential.

Case presentation: A male patient of about 5 1/2 years old with a large asymptomatic mass, with which occupied the base of neck involving the whole anterior part of the neck just like the crest of a turkey mimicking an hygroma, this require a total excision followed by reconstruction and drainage with two tubes.

Conclusion: Giant pediculate lipom of the anterior neck just like the neck crest of a turkey mimicking an hygroma is an extremely rare case. The high resolution MRI provides an accurate cost effective preoperative investigation method. Surgical operation of this nature should be performed by an experienced surgeon and care should be taking to protect the carotid arteries the jugular vein and the vagus nerve.

Key words: pediculate lipom of the anterior neck, surgical treatment.

Background

Lipomas are the most common encountered benign mesenchymal tumors, arising in any location, where fat is normally present^{1,2}. The occurrence in the head and neck is relatively rare³. Most commonly at the posterior subcutaneous neck. Surgical intervention here is challenging because of the proximity of the blood vessels and the nerve and thus the knowledge of anatomy and meticulous surgical technique are essential. Here we describe a rare case of giant pediculate lipoma of the anterior part of the neck that was successfully managed surgically.

Case presentation

A 5,1/2 years old male child and his mother presented in our department with a large anterior neck mass requesting surgical excision for a cosmetic better neck appearance. Parents had been aware of the relatively fast going painless swelling for the past 5 years, parents are poor, with less education and living in isolated part of the village and never sought medical advice. Clinical examination revealed a mobile, soft and tender mess measuring 11/9,5 cm in size and located at the anterior part of the neck. The surface off the mass was smooth and the underlying skin was normal without sign of decoloration or tumor adhesion (Figure 1).

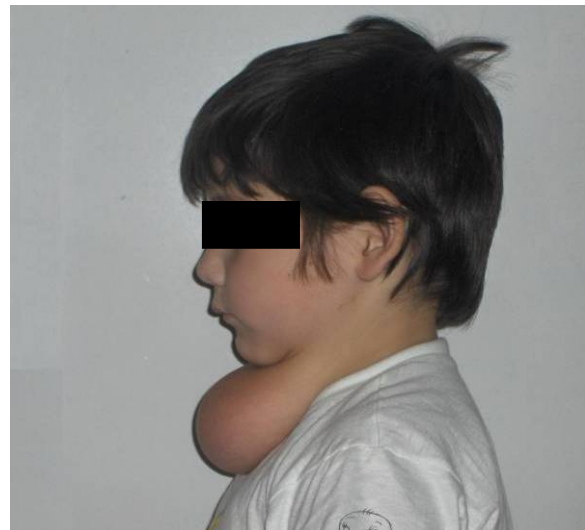
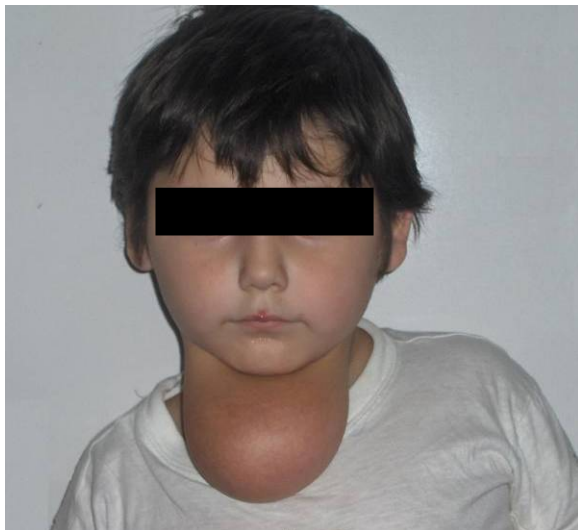
Fig. 1. Pediculate lipom of the anterior neck – clinical aspect.

The vagus nerve function was intact. The high resolution MRI showed an adipose tissue signal density

mass well encapsulated measuring 11,9,5 cm (Figure 2).

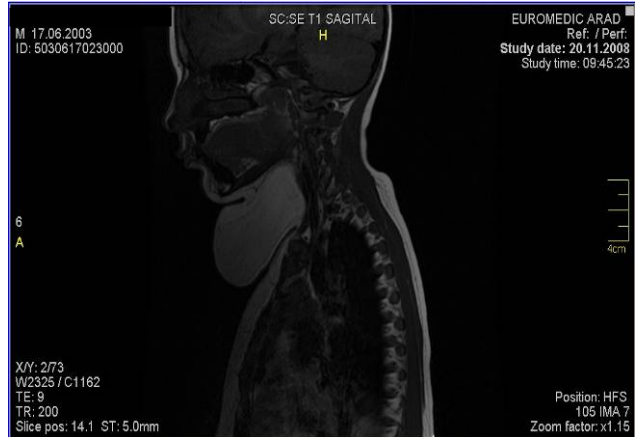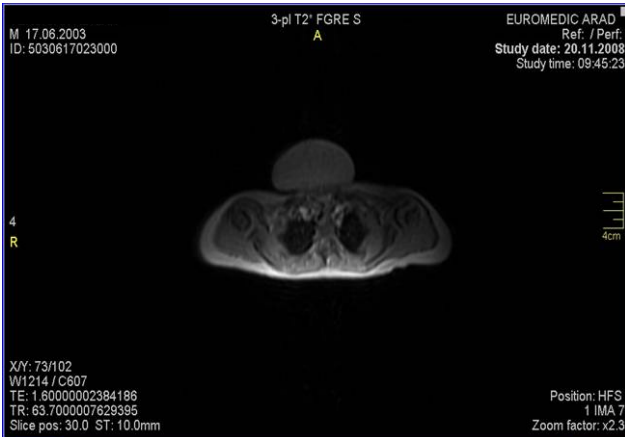


Fig. 2. Pediculate lipom of the anterior neck – MRI aspect.

General anesthesia with orotracheal intubation. Transverse incision about 12cm wide, meticulous dissection of encapsulated lipoma, enucleation of the tumor mass,

followed by excision of the excess skin. Hemostasis by electrocoagulation, drainage tube.

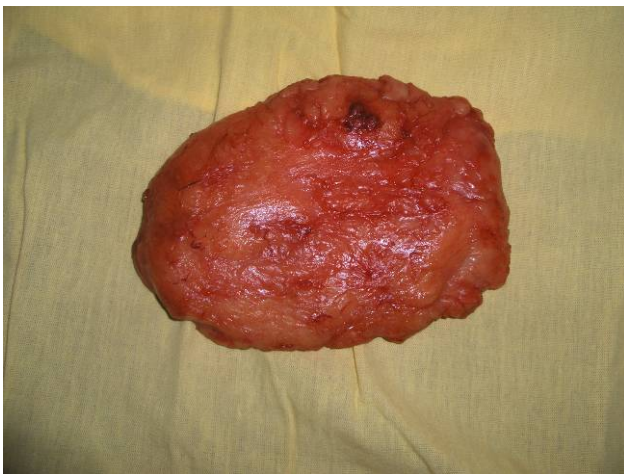

Fig. 3. Resected lipoma.

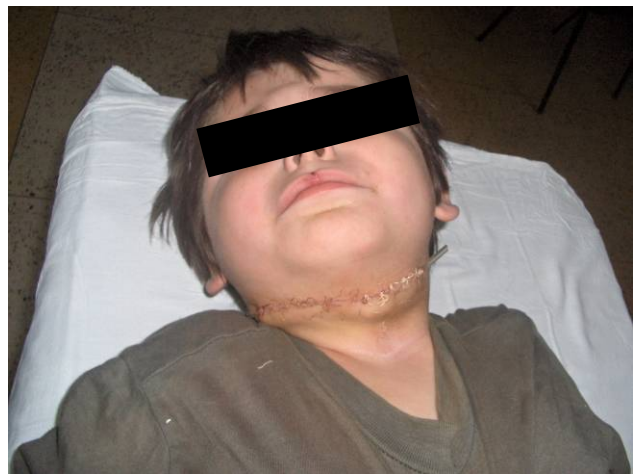

Fig. 4. Postoperative aspect.

The histological finding revealed fibrolipoma, a histological variant of lipoma. The patient had a very good recovery with satisfying neck contour and intact blood vessels and vagus nerve. Tumor recurrence was not observed 6 months after surgery.

Discussion

Lipomas are benign mesenchymal tumors histologically similar to mature adipose tissue, but the presence of fibrous capsule helps to differentiat them from simple fat aggregations⁴. Only 25% of lipomas arise from the head and neck. Lipomas of the anterior neck are extremely rare, they may extend posteriomedially between

the sternocleidomastoidian and digastric muscles sometimes. They may extend to the deep parotid lobe in very rare case.

CT scan or MRI may be helpful in further assessment and diagnosis⁵. Ultrasonography has been used as an initial imaging study in cases suspected to have head and neck lipomas^{6,7}. Compared with CT scan and MRI, ultrasonography is quick, easy, less cost by with the use of right frequency transducers may be more suitable for imaging superficial structures. However the soft tissue characterization is less specific with ultrasonography than with CT scan or MRI.

On CT scan, lipomas have typical characteristics of homogeneous masses with few septations, MRI can also accurately diagnose lipomas preoperatively. Moreover, the margin of a lipoma is clearly defined by MRI as a black rim, enabling lipomas to be distinguished from surrounding adipose tissue, a distinction that cannot be made from CT images. In this reported case, however the high resolution MRI provided enough information with respect to the preoperative planning and contributed to the diagnosis.

Although MRI may prove to be better diagnostics tool regarding tumor margin characteristics, the cost of MRI is nearly three times that of CT and so we believe that although MRI is highly useful, the CT scan with specific radiodensity recording is the preferred operative investigation⁸.

Fine needle aspiration requires an experienced cytologist but it still has a significant false negative rate⁹.

Consecutive follow up might be a valid option for patients with anterior neck lipomas surgical interventions here is challenging and may be reserved for patients with cosmetics and pressure effects. Possible postoperative morbidities such as vascular injury, vagus nerve dysfunction, scar and asymmetric contour must be explained to the patient before operation.

Conclusion

Giant pediculated lipoma of the anterior neck is extremely rare. Although MRI may provide better tumor margin characteristics, the CT scan with specific radiodensity recording is the preferred preoperative investigation. Surgical management of this tumor is challenging and should be performed by an experienced surgeon due to the need for meticulous dissection with respect to the underlying blood vessels and nerve.

References

1. Kransdorf MJ. Benign soft-tissue tumors in a large referral population: distribution of specific diagnoses by age, sex, and location. *AJR Am J Roentgenol.* 1995;164:395–402. [PubMed]
2. El-Monem MH, Gaafar AH, Magdy EA. Lipomas of the head and neck: presentation variability and diagnostic work-up. *J Laryngol Otol.* 2006;120:47–55. [PubMed]
3. Som PM, Scherl MP, Rao VM, Biller HF. Rare presentations of ordinary lipomas of the head and neck: a review. *AJNR Am J Neuroradiol.* 1986;7:657–664. [PubMed]
4. Kim YH, Reiner L. Ultrastructure of lipoma. *Cancer.* 1982;50:102–106. [PubMed]
5. Pensak ML, Gluckman JL, Shumrick KA. Parapharyngeal space tumors: an algorithm for evaluation and management. *Laryngoscope.* 1994;104:1170–1173. [PubMed]
6. Ahuja AT, King AD, Kew J, King W, Metreweli C. Head and neck lipomas: sonographic appearance. *AJNR Am J Neuroradiol.* 1998;19:505–508. [PubMed]
7. Gritzmann N, Schratter M, Traxler M, Helmer M. Sonography and computed tomography in deep cervical lipomas and lipomatosis of the neck. *J Ultrasound Med.* 1988;7:451–456. [PubMed]
8. Chikui T, Yonetsu K, Yoshiura K, Miwa K, Kanda S, Ozeki S, Shinohara M. Imaging findings of lipomas in the orovagus region with CT, US, and MRI. *Oral Surg Oral Med Oral Pathol Oral Radiol Endod.* 1997;84:88–95. 10.1016/S1079-2104(97)90302-4. [PubMed]
9. Layfield LJ, Glasgow BJ, Goldstein N, Lufkin R. Lipomatous lesions of the parotid gland. Potential pitfalls in fine needle aspiration biopsy diagnosis. *Acta Cytol.* 1991;35:553–556. [PubMed]

Correspondence to:

Henry.I.Osakwe
County Emergency Hospital Arad
Calea Victoriei 1-3,
Arad, Romania
E-mail: henrysan2007@yahoo.com