

## NEUROBLASTOMA - A CONCISE REVIEW

R Mejdi<sup>1</sup>, CM Popoiu<sup>1</sup>, ES Boia<sup>1</sup>

<sup>1</sup>Department of Pediatric Surgery – University of Medicine and Pharmacy Timisoara

### Abstract

Far from pretending to be an exhaustive ex-cathedra exposé on neuroblastoma, this article attempts to be a concise review of the literature. It focuses on clinical diagnostic reflexes and staging paradigms. Controversial and hair-splitting issues regarding risk stratification, treatment and prognosis have been discretely and carefully avoided.

**Key words:** neuroblastoma, peripheral neuroblastic tumors, ganglioneuroblastoma, ganglioneuroma, small blue round cell tumors, pathologic classification, paraneoplastic syndromes, tumor markers, clinical staging.

### Introduction

Neuroblastoma (NB) is the fourth most common malignancy of childhood, accounting for roughly 8% of tumors – preceded by leukemia (30%), CNS tumors (22%) and lymphoma (15%). It is nonetheless the first intraabdominal and the first extracranial solid tumor to be encountered in the pediatric population<sup>1,2</sup>.

NB is a neurocristopathy, arising from pluripotent primordial neural crest cells. Though the tumor predilectively involves the adrenal medulla, it may arise anywhere along the sympathetic axis, to involve the neck, posterior mediastinum, retroperitoneal (paraspinal) ganglia, adrenal medulla or pelvis<sup>3</sup>. Figure 1 – illustrates the anatomic distribution of neuroblastoma primary sites.

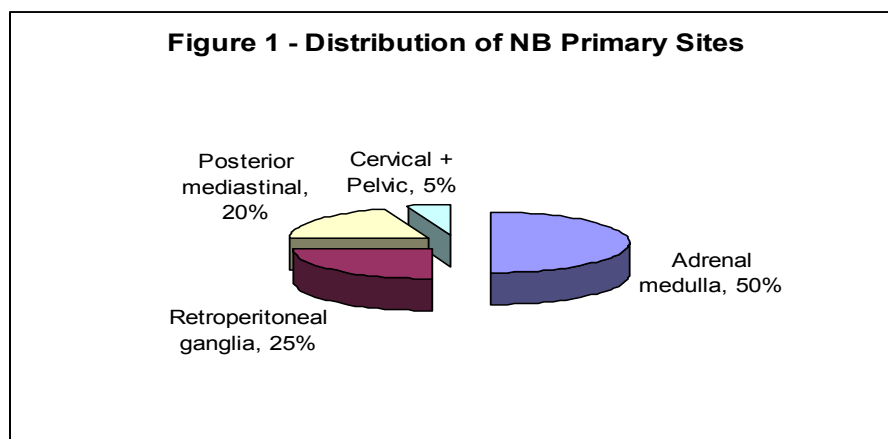


Figure 1 – The anatomic distribution of neuroblastoma primary sites.

### Epidemiology

The incidence of NB is approximately 1 case per 10.000 live births/yr. It has a bimodal distribution with a first peak during infancy and a later peak at the age of 2-4 yrs. It is more common in whites, with a slight male predisposition to develop the tumor (M:F = 1.3:1).

Several epidemiologic studies with conflicting results investigated the contribution of a multitude of risk factors, including maternal obstetric and gynecologic history, preterm birth and low birth weight, breastfeeding, drug and lifestyle exposure during pregnancy, parental occupation and environmental exposures<sup>4,5</sup>.

### Histopathology

NB is a part of a histopathologic continuum, namely Peripheral Neuroblastic Tumors (pNTs) which include neuroblastoma, ganglioneuroblastoma and ganglioneuroma<sup>6</sup>.

Undifferentiated NB consists of small round blue uniform cell tumors with dense hyperchromatic nuclei and reduced cytoplasm. Neuropils or neuritic processes are pathognomic for neuroblastoma. Eosinophilic neuritic processes are surrounded by neuroblasts to form Homer-Wright pseudorosettes, present in 15-50% of bioptic samples. Ganglioneuroma which lies at the differentiated extreme of the spectrum is associated with a benign tumoral behavior. It is composed of mature ganglia, schwann cells and neuritic processes<sup>7,8</sup>.

Shimada et al. devised a histopathological system in 1984, adopting the original concept of age-linked morphological evaluation. It was later modified in 1999 as the International Neuroblastoma Pathology Classification with a strong reliability in predicting tumoral behavior and prognosis<sup>9,10</sup>. Table 1 – summarizes the modified Shimada system of neuroblastic tumors.

The Shimada classification considers age, neuroblast differentiation, Schwannian stromal density, mitosis–karyorrhexis index (MKI) and nodular pattern, to sort out patients into a favorable and unfavorable histology groups.

Joshi et al. introduced an alternate classification system in 1992, based on mitotic rate and calcifications combined patient age at diagnosis. It was later updated in 1996 by substituting MKI for mitotic rate.

Table 1 - Modified Shimada Pathologic Classification of Neuroblastic Tumors.

Morphology		Favorable Histology	Unfavorable Histology
Stroma rich		Well differentiated (ganglioneuroma) Ganglioneuroblastoma, intermixed	Ganglioneuroblastoma, nodular
Stroma poor (neuroblastoma)	Age <18 mo	MKI < 4%	MKI > 4% or undifferentiated
	Age 18-60 mo	MKI < 2% and differentiating	MKI > 2% or Undifferentiated or Poorly differentiated
	Age > 60 mo	None	All

*Clinical presentation:*

NB diagnosis continues to be a challenging enterprise due to the multitude of variables involved in its clinical presentation (primary site, presence of metastatic disease, vasoactive tumoral by-products.)

An intraabdominal primary site is reported in up to 75% of patients. Therefore, it is of paramount importance to elicit a history of recurrent abdominal pain and identifying a palpable, nontender, firm, irregular mass crossing the midline (nephroblastoma in contrast is a smooth mobile flank mass which does not cross the midline.)

Whereas localized disease is hard to pinpoint upon history taking and physical examination, metastatic dissemination (encountered in 50% of children presenting with NB) is associated with malaise, fatigue, irritability, anorexia, weight loss or failure to thrive, fever of unknown etiology and bone pain.

Characteristic paraneoplastic telltale presentations are rare, but they may prove invaluable in clinical practice since they may offer a shortcut to an otherwise evasive diagnosis. Such peculiar clinical presentations include:

1. Kinsbourne syndrome (Opsomyoclonus-ataxia syndrome, OMA), an autoimmune cerebellar disorder, classically described as “dancing eyes and dancing feet” consists of involuntary rapid erratic eye movements and/ or ataxia and polymyoclonus of the palpebrae, the trunk and the limbs, often with behavioral, motor and cognitive developmental deficits.

2. Transverse myelopathy, dumbbell lesions with intraspinal extradural extensions, resulting in motor and sensory deficits, radicular or back pain, and sphincter disturbances.

3. Kerner-Morrison syndrome, a tetrad (affecting serendipitously 4% of cases) associating neuroblastoma, intractable treatment-resistant secretory diarrhea, dehydration and hypokalemia. This sequence is believed to

be initiated by VIP (vasoactive intestinal peptide) oversecreted by maturing neuroblasts.

4. Horner Syndrome, characterized by enophthalmia, ptosis, miosis, heterochromia and anhydrosis. The recruitment of locoregional ganglia by the tumoral process is a plausible explanation of the association with neuroblastoma.

5. Hypertensive syndrome, usually implicates the activation of the renin-angiotensin system by tumor pressure on the renal artery rather than the intuitive mechanism of catecholamine metabolites secretion by the tumor.

6. Pepper syndrome, associated with 4S neuroblastoma, involves infants (<1 yr.) suffering extensive metastatic dissemination, but still limited to skin, liver and bone marrow. Spontaneous regression is the rule. However, massive hepatomegaly, respiratory insufficiency and severe sepsis may pose a fatal threat.

7. “Blueberry muffin” metastatic subcutaneous nodules, associated with 4S neuroblastoma. It is essential to distinguish such nodules from leukemic infiltrates.

8. Hutchinson syndrome, caused by massive metastasis to bone with consequent osteodynia, limping and pathologic fractures.

9. “Raccoon eyes”, or “panda eyes”, reminiscent to bilateral periorbital echymoses consecutive to skull base fracture implicating the anterior fossa, expression of metastasis of an intraorbital tumor.

*Diagnosis:*

It is an undisputable fact that histopathological studies remain the ultimate tool in ascertaining a definitive diagnosis. Nonetheless, it is not a rigid dogma to be used as a pretext to hinder the clinical thinking process. Indeed the convergence of characteristic clinical presentation, mediastinal, intraabdominal or pelvic mass, elevated urinary catecholamines [vanillylmandelic acid (VMA)/

homovanillic acid (HVA)], plain radiographs, ultrasonography, contrast-enhanced CT, MRI, radiolabeled metaiodobenzylguanidine (MIBG), technetium 99 – methylene diphosphonate bone scan and bone marrow biopsy offer invaluable complementary diagnostic and clinical staging data.

*Differential diagnosis:*

- Small Blue Round Cell Tumors:
  - Ewing’s sarcoma
  - Peripheral neuroectodermal tumors (PNET)
  - Rhabdomyosarcoma (RMS)
  - Desmoplastic small round cell tumor (DSRCT)
  - Non-Hodgkin Lymphoma (NHL)
- Neonatal adrenal hemorrhage
- Nephroblastoma
- Esthesioneuroblastoma (= Olfactory neuroblastoma)
- Pheochromocytoma
- Paraganglioma
- Ganglioneuroblastoma
- Ganglioneuroma

*Tumor markers:*

- VMA, HVA and VMA/HVA ratio in urine or serum

- Neuron specific enolase (NSE)
- Ferritin
- Lactate dehydrogenase (LDH)
- Chromogranin A
- Neuropeptide Y
- Chromosomal and molecular markers:
  - N-myc amplification, triploidy, del.1p, TrkB, telomerase RNA correlate with a poor prognosis.
  - diploidy/ tetraploidy, TrkA, TrkC, CD44 correlate with a favorable prognosis.

*Staging:*

A minimal evaluation for clinical staging of NB will necessarily include:

- (1) History and physical examination
- (2) Laboratory studies:
  - CBC, differential, platelets
  - Liver and kidney function studies
  - 24h-urinary metanephrines excretion
- (3) Diagnostic imaging:
  - Chest radiograph
  - Skeletal survey with orbital views
  - Bone scan
  - CT scan of abdomen and pelvis (neck or thorax if primary in these areas)
- (4) Bone marrow aspirate +/- biopsy.

Table 2 - The International Neuroblastoma Staging System (INSS), based on the Evans staging system.

Stage	Definition
<b>1</b>	Localized tumor with complete gross excision, with or without microscopic residual disease; negative ipsilateral lymph node.
<b>2</b>	<b>2A</b> Localized tumor with incomplete gross excision; negative ipsilateral nonadherent lymph nodes.
	<b>2B</b> Localized tumor with or without complete gross excision; positive ipsilateral nonadherent lymph nodes; negative contralateral lymph nodes.
<b>3</b>	Unresectable unilateral tumor infiltrating across the midline, with or without regional lymph node involvement, or Localized unilateral tumor with contralateral regional lymph node involvement, or Midline tumor with bilateral extension by infiltration (unresectable) or by lymph node involvement.
<b>4</b>	Any primary tumor with dissemination to distant lymph nodes, bone, bone marrow, liver, skin or other organs (except as defined for stage 4S.)
<b>4S</b>	Localized primary tumor (as defined for stage 1, 2A, or 2B) with dissemination limited to skin, liver and bone marrow [ $<10\%$ involvement] (limited to infants $< 1$ year old.)

*Treatment - Basic guidelines*

The treatment of neuroblastoma is based on a multimodal, pluridisciplinary approach uniting the efforts of surgeon, pediatrician, pathologist, chemotherapist, radiation therapist and intensive therapist.

Age plays a pivotal role in clinical decision making, therapeutic management and risk stratification of children with neuroblastoma. Infants  $< 1$ yr. usually present with tumors of favorable histology. Spontaneous regression (with no therapeutic intervention) of 4S tumors is the rule; if no major organ function is compromised. This is illustrated by

Pepper syndrome where massive hepatomegaly, respiratory failure and severe sepsis could be fatal.

Complete resection remains an ideal desideratum of surgical treatment since it is curative in 90% of cases. Nevertheless, incomplete excision and tactical debulking enhance the responsiveness to adjunctive therapy.

Popular chemotherapeutic regimens used in NB include: vincristine + cyclophosphamide + doxorubicin, etoposide in combination with carboplatin, cisplatin or ifosfamide. Consolidation regimens include: carboplatin + etoposide + melphalan or cyclophosphamide,

thiotepa + cyclophosphamide, and ifosfamide with total body irradiation (TBI).

Innovative chemotherapeutic strategies are subjected to extensive investigation. These include the use of tumor-targeted biologic agents such as retinoids, tyrosine kinase inhibitors, modulators of apoptotic pathway and angiogenesis, anti-angiogenic agents, arsenic trioxide, demethylating agents, histone deacetylase inhibitors, and

immunologic agents such as anti-GD2, IL-2, tumor necrosis factor, INF and vaccines.

The advent of effective chemotherapeutic regimens eclipsed the role of radiotherapy in the management of neuroblastoma. Nonetheless, it is still useful in 3 therapeutic scenarios: (1) amelioration of outcome in stage III patients > 1 yr., (2) palliative therapy in bone metastasis and persistent primary disease, and (3) TBI in massive chemoradiation therapy prior to bone marrow transplantation.

#### References

1. Stringer MD, Oldham KT, Mouriquand PDE, Pediatric Surgery and Urology, 2nd Edition, Cambridge University Press, 2006, 58: 745-758.
2. Joyner BD, Lopushnyan N, Neuroblastoma, emedicine, Updated: Feb 19, 2010.
3. Arensman RM, Bambini DA, Almond PS, Pediatric Surgery, Landes Bioscience, 2000, 39:169-176.
4. Ashcraft KW, Holder TM, Pediatric Surgery, 2nd Edition, W. B. Saunders Company, 1993, 66:823-839.
5. Cheung N-KV, Cohn SL, Neuroblastoma, Springer-Verlag Berlin Heidelberg, 2005.
6. Grosfeld JL, O'Neill JA Jr., Fonkalsrud EW, Coran AG, Pediatric Surgery, 6th Edition, Mosby, 2006, Volume 1, 28:467-494.
7. Kim S, Chung DH, Pediatric Solid Malignancies: Neuroblastoma and Wilm's Tumor, Surgical Clinics of North America, 2006, 86:469-487.
8. Lacayo NJ, Marina N, Neuroblastoma, emedicine, Updated: Apr 8, 2010.
9. Shimada H, Chatten J, Newton WA Jr, et al, Histopathologic prognostic factors in neuroblastoma: Definition of subtypes of ganglioneuroblastoma and an age-linked classification of neuroblastoma, J Nat Cancer Inst 1984;73:405-416.
10. Shimada H, Stram DO, Chatten J, et al, Identification of subsets of neuroblastomas by combined histopathologic and N-myc analysis, J Natl Cancer Inst 1995;87:1470-1476.

Correspondence to:

Mejdi Rachid  
 Calea Aurel Vlaicu st. N°6, Bl. A7 / C. Apt.7  
 Arad 310141  
 Romania  
 E-mail: mejdirachid@yahoo.com