

TOLERATED CONGENITAL MEGACOLON - CASE REPORT

L Pop¹, Adelina Timofte¹, CM Popoiu², Sorina Taban³, VL David²

¹Department II Pediatrics, University of Medicine and Pharmacy “Victor Babes” Timisoara

²Paediatric Surgery Clinic, “Louis Turcanu “Hospital, University of Medicine and Pharmacy “Victor Babes” Timisoara

³Pathology Department, University of Medicine and Pharmacy “Victor Babes” Timisoara

Abstract

In 1886, Harold Hirschsprung first described Hirschsprung disease as a cause of constipation in early infancy. Early recognition and surgical correction of Hirschsprung disease protects affected infants from enterocolitis and debilitating constipation³. Paper aim is to present the case of an eight months old baby, admitted in Clinic II Pediatrics for abdominal distention, vomiting and chronic constipation.

Key words: Hirschsprung disease, tolerated, delayed diagnose

Background

Congenital megacolon (Hirschsprung disease) results from the absence of enteric neurons within the myenteric (Auerbach) and submucosal (Meissner) plexus of the distal colon resulting in a functional obstruction. Enteric neurons are derived from the neural crest and migrate caudally with the vagal nerve fibers along the intestine. These ganglion cells arrive in the proximal colon by 8 weeks' gestation and in the rectum by 12 weeks' gestation. Multiple loci⁸ appear to be involved, including chromosomes 13q22, 21q22, and 10q. Arrest in migration leads to an aganglionic segment. This results in clinical Hirschsprung disease. The exact worldwide frequency is unknown, although international studies have reported rates ranging from approximately 1 case per 1500 newborns to 1 case per 7000 newborns¹; this disease occurs more often in males than in females, with a male-to-female ratio of approximately 4:1. Hirschsprung disease should be considered in any newborn who fails to pass meconium within 24-48 hours after birth⁷. Most cases are nowadays diagnosed in the newborn period.

Case presentation

A 8 months old baby boy was admitted in our clinic for : abdominal distention, vomiting, chronic constipation. The child was born at 39 weeks gestational age, 2750 g and 9 APGAR score. He received natural alimentation for 1 month, continued with NAN 1 till the admission. We don t have any specific data about the beginning of his symptoms. The mother was not informed about the passage of meconium. The child was sent home with severe abdominal distention and consulted by a paediatric surgeon at the age of 9 days being suspected of Hirschsprung disease. The diagnosis was not confirmed at that time.

Clinical examination revealed an infant with 7.6 kg weight, 70 cm, pale, marked abdominal distention with palpable dilated loops of colon, visible superficial vessels.

Rectal examination revealed an empty rectal vault.

Laboratory investigation revealed hypoproteinemia and mild anaemia.

Abdominal ultrasound showed a bowel filled up with gas and loops.

Sweat test for cystic fibrosis: negativ.

Surgical examination concluded significant suspicion of Hirschsprung disease.

The patient is transfered in the Paediatric Surgery Clinic, “Louis Turcanu “ for further investigation.

Contrast enema demonstrates the transition zone in the rectosigmoid region from dilated, normally innervated bowel to normal caliber, noninnervated bowel (fig 1).

Pathology exam. There were harvested 2 biopsies at 3-5 cm from the dentate line. Hematoxilin-eosin stain reveals hypertrophied nerve trunks in the submucosal layer of the bowel (fig 2).

Imunochemistry (ENS, S-100, CD 117) improved the accuracy of the diagnosis (fig 3,4,5).

Based on these findings, the diagnosis of Hirschsprung disease could be sustained.

For differential diagnosis⁴, many conditions were considered as follow:

1. Chronic constipation, clinically similar to Hirschsprung disease was excluded by rectal examination (rectal vault empty)
2. Abdominal tumors also manifested with abdominal distention, but abdominal ultrasound and exploratory laparotomy revealed no such findings.
3. Cystic fibrosis may associate distal obstruction syndrome. This condition is excluded by the negative sweat test and the absence of steatorrhea
4. Malformative pathology of the digestive tract (Anorectal malformations, Intestinal atresias or stenosis, Intestinal malrotation) excluded by rectal examination and contrast enema.
5. Intestinal motility disorders (Neuronal intestinal dysplasia, Chronic Intestinal Pseudo-obstruction) clinically and radiological similar to Hirschsprung disease. Exclusion: Positivity for ENS and S-100 .

6. Cow milk allergy. Recurrent constipation may occur at 6% of the children with cow milk allergy. Exclusion: Absence of clinical findings such as weight loss, rash, diarrhea. Rectal biopsy shows no specific alteration (eosinophilic infiltration) in the mucosal layer.

Surgical intervention⁵: median laparotomy, rectal amputation, rectosigmoidian resection, left diverting colostomy. After 6 months of favorable outcome, the descendent bowel segment is pulled trouh (Duhamel technique)⁵.

Particularity of the case is the discrepancy between the pathology aspects and tolerated form of the disease for a relatively long time (8 months).

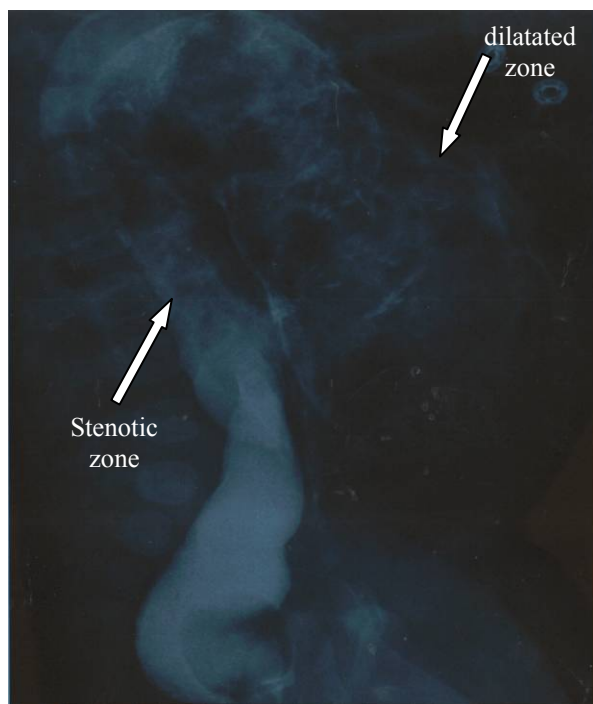


Fig.1 Contrast enema.

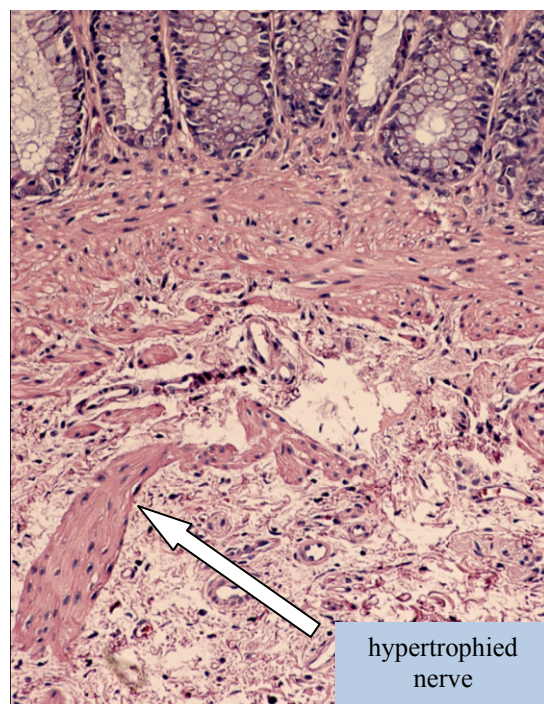


Fig.2. Bowel biopsy HE stain.

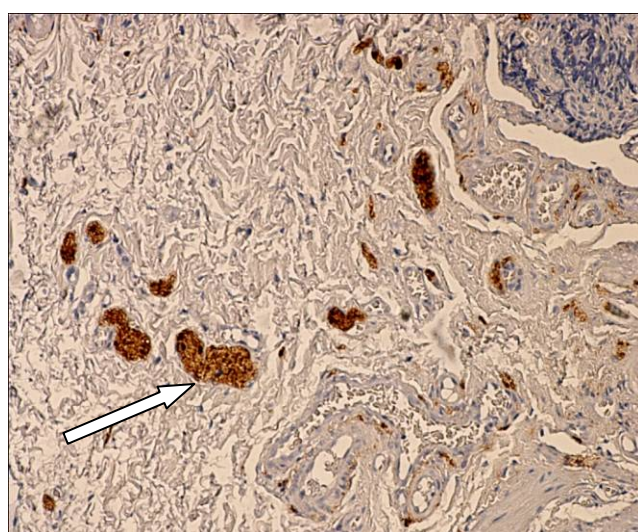


Fig.3 Imunochemistry ENS (reveal hypertrophied nerve trunks).

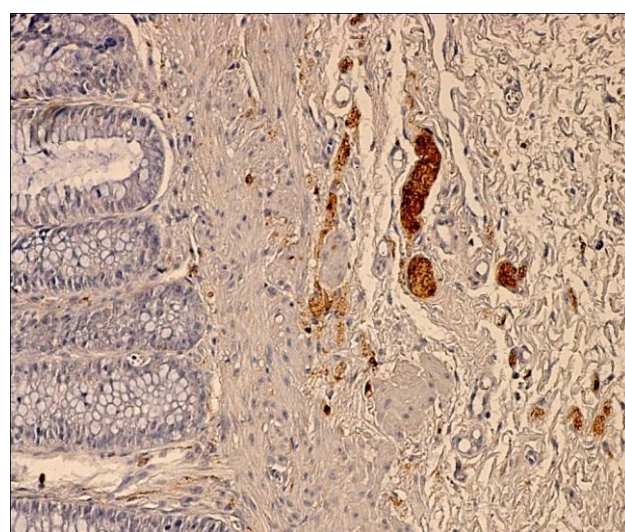


Fig.4. Fig.4 Imunochemistry for S-100 accentuates the absence of ganglionic cells

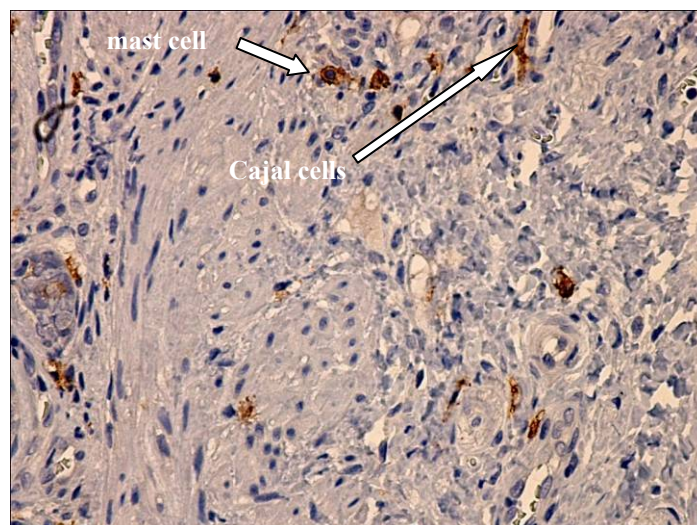


Fig.5 Imunochemistry for CD 117
(rare Cajal cells, frequent mast cells).

Conclusions

The diagnosis of this disease requires multiple investigations. Early diagnosis is important to prevent complications (enterocolitis, colonic rupture)⁶. A rectal suction biopsy can detect hypertrophic nerve trunks and the absence of ganglion cells⁵ in the colonic submucosa, confirming the diagnosis.

Up to one third of patients develop Hirschsprung's-associated enterocolitis, a significant cause of mortality. Patients should be monitored closely for enterocolitis for years after surgical treatment⁷. With proper treatment, most patients will not have long-term adverse effects and can live normally.

References

1. Meza-Valencia BE, de Lorimier AJ, Person DA. Hirschsprung disease in the U.S. associated Pacific Islands: more common than expected. *Hawaii Med J.* Apr 2005;64(4):96-8, 100-1. [Medline]
2. Swenson O, Sherman JO, Fisher JH. Diagnosis of congenital megacolon: An analysis of 501 patients. *J Pediatr Surg.* 1973;8:587-594. [Medline].
3. Belknap WM. Hirschsprung's Disease. *Curr Treat Options Gastroenterol.* Jun 2003;6(3):247-256. [Medline]
4. Kessmann J. Hirschsprung's disease: diagnosis and management. *Am Fam Physician.* Oct 15 2006;74(8):1319-22. [Medline]
5. Daniel H. Teitelbaum and Arnold G. Coran, Hirschsprung disease and other neuromuscular disorders of the Intestine, p.1514 – 1570
6. Feldman T, Wershil BK. In brief: Hirschsprung disease. *Pediatr Rev.* Aug 2006;27(8):e56-7. [Medline].
7. de Lorijn F, Boeckxstaens GE, Benninga MA. Symptomatology, pathophysiology, diagnostic work-up, and treatment of Hirschsprung disease in infancy and childhood. *Curr Gastroenterol Rep.* Jun 2007;9(3):245-53. [Medline].
8. Puffenberger EG, Kauffman ER, Bolk S, et al. Identity-by-descent and association mapping of a recessive gene for Hirschsprung disease on human chromosome 13q22. *Hum Mol Genet.* Aug 1994;3(8):1217-25. [Medline].

Correspondence to:

Adelina Timofte
Sirius Street no7, ap7
Timisoara,
Romania
E-mail: albastru_amb@yahoo.com