

## PRELIMINARY RESULTS OF AN ACUTE OSTEOMYELITIS OF THE FEMUR WITH STAPHYLOCOCCUS AUREUS INFECTION IN A NEWBORN

H Osakwe<sup>1</sup>, RE Iacob<sup>1</sup>, Z Moldovan<sup>1</sup>, M Soiu<sup>1</sup>, Maria Trailescu<sup>1</sup>

### Abstract

Osteomyelitis refers to bony inflammation that is almost always due to infection typically bacterial. This article primarily deals with pyogenic osteomyelitis. Drainage of superosteal abscess at the upper end of the femur (upper ½). Pus found under considerable pressure (subperiosteal abscess) was drained, 1 drill hole down the medulla, bone biopsy, 2 drainage tubes were placed. One for flushing initially with antiseptic solution (Betadine) dissolved in 500 ml of distilled water. Flushing was stop on 14th postoperative day. Pus was taken for culture and antibiotic sensitivity during surgery.

**Key words:** osteomyelitis, epiphysis, metaphysic, femur, hip, newborn, abscess, biopsy.

### Background

Osteomyelitis is inflammation of the bone caused by an infecting organism (3). Although bone is normally resistant to bacterial colonization, events such as trauma, surgery, presence of foreign bodies, or prostheses may disrupt bony integrity and lead to the onset of bone infection. Osteomyelitis can also result from hematogenous spread after bacteremia. Early and specific treatment is important in osteomyelitis, and identification of the causative microorganisms is essential for antibiotic therapy (6,7). The major cause of bone infections is Staphylococcus aureus (5).

Osteomyelitis is often diagnosed clinically with nonspecific symptoms such as fever, chills, fatigue, lethargy, or irritability. The classic signs of inflammation, including local pain, swelling, or redness, may also occur and normally disappear within 5-7 days.

On physical examination, scars or local disturbance of wound healing may be noted along with the cardinal signs of inflammation. Range of motion, deformity, and local signs of impaired vascularity are also sought in the involved extremity. If periosteal tissues are involved, point tenderness may be present.

In children, the clinical presentation of osteomyelitis can be challenging for physicians because it can present with only nonspecific signs and symptoms, and the clinical findings are extremely variable. Children may present with decreased movement and pain in the affected limb and adjacent joint, as well as edema and erythema over the

involved area. In addition, children may also present with fever, malaise, and irritability. Newborns with osteomyelitis may demonstrate decreased movement of a limb without any other signs or symptoms.

Approximately 20% of adult cases of osteomyelitis are hematogenous, which is more common in males for unknown reasons (9).

The incidence of spinal osteomyelitis, as depicted in the image below, was estimated to be 1 in 450,000 in 2001.

Surgery is indicated when the patient has not responded to specific antimicrobial treatment, if there is evidence of a persistent soft tissue abscess or subperiosteal collection, or if concomitant joint infection is suspected. Debridement of necrotic tissues, removal of foreign materials, and sometimes skin closure of chronic unhealed wounds are necessary in some cases (1,2,4,8).

### Case presentation

C.R., a male 30 days old baby was admitted late evening at the county hospital Arad through the ER, with no known history of trauma, according to mum baby was discharged 10 days earlier after receiving treatment at the pediatric department for upper respiratory tract infection on admission mum complained that baby had difficulty sleeping with frequent cries, swelling and redness of the thigh and right hip joint, pain fever and asymmetric movement of the extremities.

Mum observed the swelling 5 days ago, she saw the primary care physician but was told that it is probably an insect bite and given antihistaminic and paracetamol. Babies condition worsened and was sent to us by the primary care physician.

### Physical examination:

*General clinical signs:* low grade fever, pallor, anemia, weight loss, umbilical hernia, no chest rales, no urine infection.

*Local clinical signs:* painful focal swelling with cardinal signs of inflammation of the right thigh, right leg extremity edema, right thigh and focal joint redness, no draining pus, bone deformity (twice enlarged right thigh), restricted movement of right joint, cellulites, no sign of fracture.

<sup>1</sup>County Hospital Arad, Romania, Department of Pediatric Surgery and Pediatric Orthopedic Surgery  
E-mail: henrysan2007@yahoo.com, radueiacob@yahoo.com, zenomold@yahoo.com, mihai\_soiu@yahoo.com, trailescumaria@yahoo.com

Laboratory studies:

X-ray of the affected leg and hip joint shows: focus of infection of the upper end (epiphysis and metaphysis) of the right femur, sub periosteal abscess, periosteal reaction including codman's triangle, peripheral regions of osteolysis and osteosclerosis, no septic joint (fig. 1).

WBC – was elevated

C-reactive protein was elevated

Erythrocyte sedimentation rate (ESR) was elevated.

In view of clinical findings baby was admitted and scheduled for surgery the next day. Patient was placed on i.v. fluids, i.v. antibiotics, antithermic and vitamins.

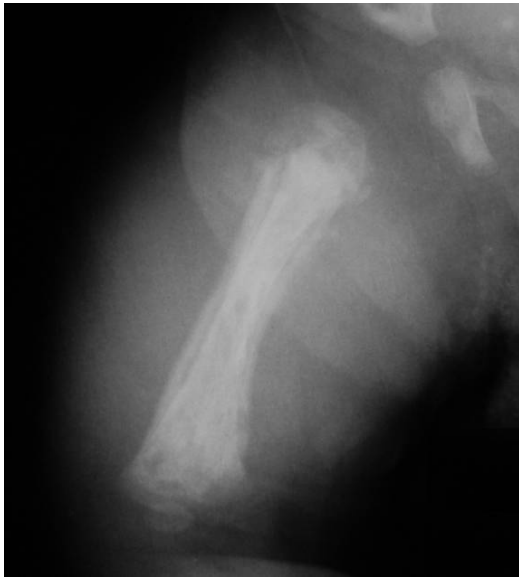

Fig. 1. Preoperative radiological aspect.

Operation:

Cut down of upper ½ of the right femur (epiphysis, metaphysis and diaphysis) through the soft tissues. Periosteum was detached from bone. Pus was found under considerable tension posteriorly. Culture sample was taken, wound washed thoroughly and drained with 2 drainage tubes one placed superiorly through the greater trochanter and the other placed inferiorly at the diaphysis (fig. 2). The upper tube was used for flushing while the low tube was used for drainage.

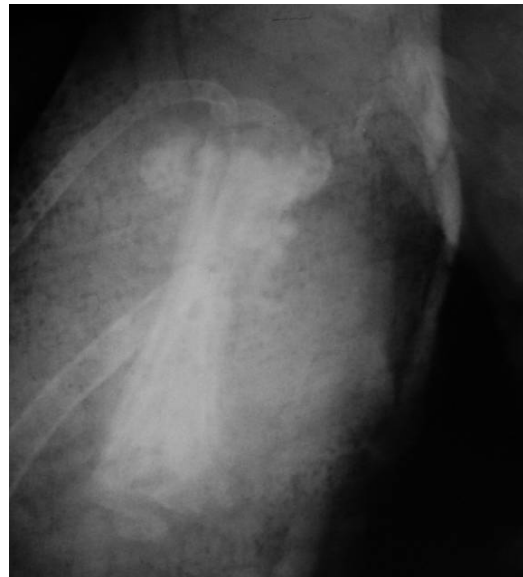

Fig. 2. Postoperative radiological aspect.

Patient was monitored at ICU, i.v. fluid administration continued with i.v. antibiotics (cefert) and gentamycin, antithermic and vitamins for the first 2 days while awaiting the result of culture and sensitivity. Flushing of wound with antiseptic (betadine) solution 10 ml dissolved in 500 ml sterile water, 24 h, for the first 2 days.

Patient post operation remained afebrile, stable, feeding well, Clear chest X-ray, but received blood transfusion because of severe secondary anemia. Negative blood culture, but pus culture was positive for staphylococcus aureus:

- sensitive for the following antibiotics clindamycin, linezolid, ofloxacin, teicoplanin;
- intermediate sensitivity – tobramycin;
- resistant for: meticillin, gentamycin, eritromycin, cefoxitin.

Patient was immediately switched to i.v. linezolid (zyvoxid) 50 mg at 8 h interval systemic antibiotics (gentamycin) was immediately stopped.

Patient right leg was immobilized in a back slab for easy wound access.

Evolution:

Despite baby's good clinical status lab test continued to show elevated WBC, C-reactive protein and Erythrocyte sedimentation rate. On 14th postoperative day Linezolid (zyvoxid) was changed to clindamycin, despite patient being stable, afebrile, feeding well, and clear chest. Change of antibiotics was based on elevated WBC, C-reactive protein and erythrocyte sedimentation rate. Blood work (WBC, C-reactive protein, Erythrocyte sedimentation rate) normalized after 7 days of clindamycin treatment. We waited 4 more days and repeated tests, patient continued to maintain normal WBC, C-reactive protein and Erythrocyte sedimentation rate. Patient was then placed in a plaster of paris (hip abduction position) Lorenz and sent home and asked to continue oral antibiotics. Checkup in a month's time. On checkup patient was admitted for blood work, x-ray and cast was removed. X-ray showed no hip dislocation and an intact growth plate and satisfactory bone regeneration (fig. 3). Normal WBC, C reactive protein and Erythrocyte sedimentation rate. Hip abduction orthosis was then recommended and patient is to be seen again in 2 months time.

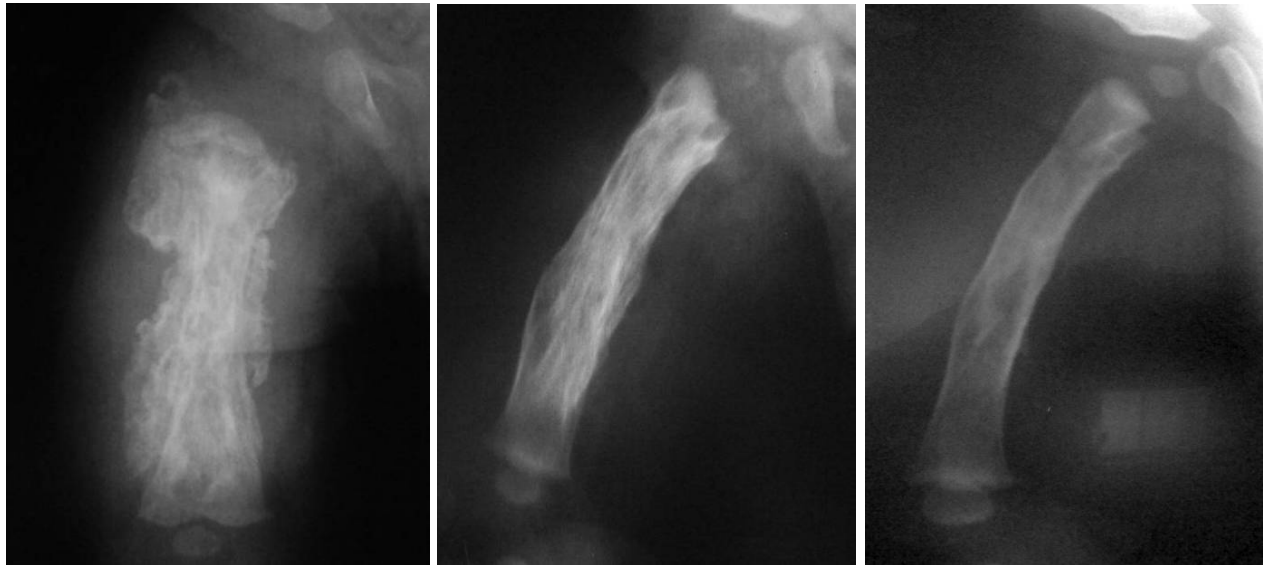


Fig. 3. Postoperative radiological aspect at 1,2 and 4 months.

### Conclusion

The absence of trauma leaves us to believe that osteomyelitis is hematogenous. Even though it is difficult to say when exactly this child fell sick the clinical signs of disease were clear upon admission, we moved fast with the right treatment and at the end everyone is happy. The future looks bright and we will continue to follow our patient. Primary care physicians should be better trained and well informed about this disease and a child with history of trauma or no trauma, fever irritability, swollen reddish extremity should always be considered for osteomyelitis until proven otherwise. Let us also underline the fact that

our patient response well to linezolid when through sensitivity test showed that it should we had to change to clindamycin. Antibiotics should be continued for at least 6-8 weeks. Clinicians should keep in mind to also cover gram negative organisms during antibiotics selection.

Elevated WBC, C-reactive protein and ESR along with x-ray or ultrasonographic changes seen in bone and soft tissues are the most valuable supportive investigations, It was observed that early decompression of the /soft tissue under cover of combinations of antibiotics led to resolution of disease.

### References

1. McAllista T.A Treatment of osteomyelitis Br. J. Hosp. Med 1974; 12:535-545
2. 2Nade S. Choice of antibiotics in management of acute osteomyelitis and septic arthritis in children. Arch Dischild 1977; 52: 679-682
3. 3Mollen RAB, Piggot J, Acute Osteomyelitis in children. J. Bone Surg(Br) 1977; 59:2-7
4. 4Cole W.G Dalziel RE; Leit S. Treatment of acute osteomyelitis in childhood. J. Bone Joint Surg(Br) 1982 64: 218-223
5. T. O'Brien, F. McManus, PH Mac. Autey, J.T Ennis. Acute hematogenous osteomyelitis. J. Bone and joint surg Br. 1982: 450=453
6. Merry Weather R. Acute osteomyelitis Br. Med J 1972; 4:456
7. Dahl L.B Hoyland. A. Dramsdahl H. Kaaresen P.I Acute osteomyelitis in children. A population based study 1965 to 1994. Scand. J infect Dis 1988;30; 573-577
8. Herring J.A editor, Tachdijian pediatric orthopedics 3rd ed. Philadelphia. W.B Saunders Co; 2001: 1841 -1872
9. Craigen M.A, Watters J, Hachett J.S, The changing epidemiology of osteomyelitis. J. Bone Joint Surg (Br) 1992; 74: 541-545

Correspondence to:

Henry Osakwe  
Spitalului Street, No.1-3,  
Arad,  
Romania  
E-mail: henrysan2007@yahoo.com