

MESENTERIC INFARCTION AT A TEENAGER RARE CASE OF ACUTE SURGICAL ABDOMEN IN PEDIATRIC PATHOLOGY

VC Cristea¹, ML Ruja²

Abstract

The mesenteric infarction, named also intestinal infarction, stays one of the world's severe dramas of acute surgical abdomen. It represents one of the main objectives in the field of clinical and therapeutic investigations due to the dramatic clinical phenomena of the disease and adds a high mortality rate, between 80 and 100. Although the symptoms are known, several elements, including the etiology are difficult to determine both clinical and intra-operative, physio-pathology mechanisms are incompletely elucidated, as events that are common with other abdominal diseases, are major difficulties in establishing a diagnosis of certainty, often delaying proper therapeutic attitude. Intense abdominal pain can be accompanied by collapse, where lean peristaltic contractions, may suggest either a hemorrhagic pancreatitis and other diseases of an acute surgical abdomen. The notion of mesenteric infarction is related to total and sudden interruption of blood flow through the superior mesenteric artery or vein. The mesenteric infarction is a maximum emergency of an acute surgical abdomen due to high diagnostic difficulties that often arises later. Rarely, intestinal-mesenteric infarction may occur in very young subjects which do not suffer from heart or vascular diseases.

Clinic study: As I said the condition is extremely rare in a child or teenager. However I intervened surgically to a girl of 16 years, initially hospitalized in pediatric clinic of the hospital. After hospitalization, the patient had diffuse abdominal pain, mainly in the epigastrium (pain which initially has been like a epigastrium distress, the primary cause being the our-days eating habits), vomiting, malaise.

Key words: mesenteric infarction, teenager

Introduction

Mesenteric infarction or intestinal infarction remains one of the world serious dramas of the acute surgical abdomen. Although the symptoms are well known, a series of elements, including the etiology, are hard to predict both clinic and intra-operative; the physiopathology is still not completely elucidated, as well as the clinical manifestations which are a lot like others abdominal diseases; gives a hard time in diagnostic decision making, most of the times delaying the right therapeutic procedure. The very intense abdominal pain which can be accompanied by collapse; muscular contraction without peristaltic wave, can suggest an acute hemorrhagic pancreatitis, volvulus, intestinal

occlusion, but also other diseases if an acute surgical abdomen. [1]H. Mondor (1960) stated that “The mesenteric infarction represents one of the hardest diseases to be diagnosed”. [2]The notion of mesenteric infarction is related to the total and suddenly interruption of the blood flow through the superior mesenteric artery or vein. [3] Classic, the mesenteric infarction, the way it is known in the specific literature, presents, intra-operative, a blood infiltration of the intestinal wall, causing a red-violet or a cyanotic coloration of a portion of bowel related area where blood supply has been stopped. [4]Microscopic, in the affected intestinal wall necrosis and hematic infarction are found, lesions that lead to an implacable evolution towards gangrene, perforation and peritonitis. [5]

Short anatomical considerations

Mesentery support certain portions of the small intestine from the abdomen also serves to movement and nutrition of small intestine, [6] inserted of the posterior wall of the abdomen; its root begins at the level of the flexion of the jejuna-duodenum, at the lateral edge of the lumbar spine at the level of L1-L2 vertebrae and ends in the right iliac fossae corresponding to the sacroiliac joint. [7] It divides the lower abdominal floor in two regions: the right mesenteric-colic space (Right colic niche) and left mesenteric-colic space (Left colic niche). The superior pole of the mesentery is situated at the origin of the superior mesentery artery la the level of the flexion of the jejuna-duodenum, and the inferior pole corresponding to the place where the ileo-caecal valve will be situated (Fig. 1).

The obstruction of the superior mesentery artery or some branches that detach from it stands first place for mesenteric infarction. [8] It's the fourth artery that originate from the abdominal aorta, as size (after the inferior diaphragmatic artery, medium supra-renal artery and the celiac trunk). It irrigates the jejuno-ileum, the caecum, the appendix, the ascendant and transversal colon, physiologically corresponding to the intestinal segment which main function is to absorb. The superior mesentery artery comes from the abdominal aorta in front of the L1 vertebra and ends in the mesentery latch loop, in the place of implantation of the Meckel diverticulum. At the ending place, in full bowel, It divides into two arteries: a left branch, most voluminous and a right branch.

¹Department of Pediatric Surgery and Orthopedics, Children's Emergency Hospital “St. Ioan” Galati

²Pediatric Surgery and Orthopedics Clinic, Children Hospital from Brasov

E-mail: virgilcristea@yahoo.co.uk, mihairuja@yahoo.com

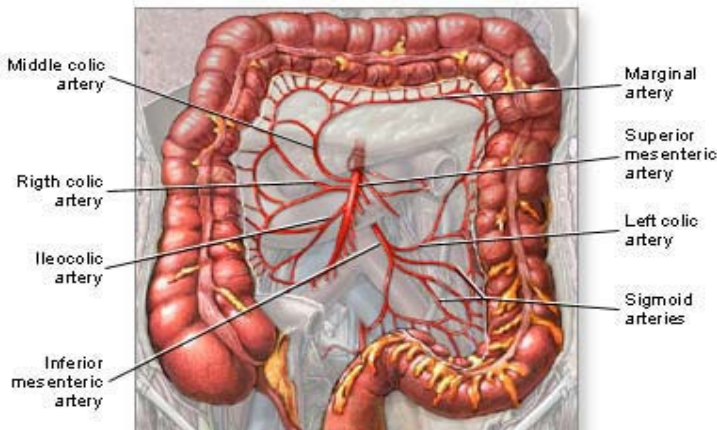


Fig. 1 Superior mesenteric artery and irrigated areas.

The physiopathology of mesenteric infraction

The mesenteric infraction is a major emergency of the acute surgical abdomen and due to difficulties the diagnose is most of the times lately right.

Extremely rare, the intestinal mesenteric infraction can appear to young subjects who do not suffer from heart or vascular diseases. [9] There have been cases of thrombocytopenic purpura which have had died through mesenteric infraction. [10] The mesenteric infraction at a child can also appear in some local diseases. [11] There have been such cases in strangled hernia (inguinal or hiatal), abdominal trauma, volvulus, intussusceptions easy to reduce [12] and generally diseases that needed or have exerted alone the trauma of the intestine. [13] It mostly appears to sick people in their second or third age. [14]

The most frequent causes which facilitate mesenteric infraction at an adult can be:

- sufferings of phlebitis or the phlebitis of the inferior vena cava; [15]
- a significant decrease of the arterial pressure, after a complex surgical intervention, when hipovolemia has occurred; [16]
- the Burrger disease; [17]
- in periarteritis nodosa; [18]
- cardiac patients, with arterial fibrillation. [19]

Although it's not well determined, the intestinal infraction can also occurred due to "visceral apoplexy" [20] (which cannot be ignored) like the vascular spasm and other mechanical factors, [21] even though the patient show any vascular lesions. [22] Mainly, the obstruction of intestinal arteries, veins or only capillaries represent the main cause to the occurrence of mesentery infraction. The sickness slowly determines necrosis of one intestinal segment or more intestinal loops, depending on the irrigated segment of the obstructed bowel.

The gravity, spread and evolution of the infraction differs from the ways of the obstructed bowel (artery or vein) and, specially, of its size.

Not all infractions evolve from the begging with gangrene, perforation and peritonitis; there are also clinical forms of evolution through stages, the process unfolding in

more than a few days, time in which there can be put a firm diagnosis, therapy being efficient, and survival assured.

The disease can be structured in 3 stages:

1. The apoplexy stage – when the dilatation of the capillary begins and shows an interstitial plasmatic exudate, and the affected intestinal loop red, cyanotic, edematiate, the leisure being in this stage irreversible. [23]
2. The true heart – with the loop of the color violet, black, not viable. [24]
3. The gangrene stage – in which the alterations are deep and irreversible, due to parietal vessel thrombosis. [25]

The most frequent mesentery infractions are the ones of arterial origin, in proportion of about 60%, while the vein origin of the disease stands around 35-40% of cases. [26] Judging on the length of the affected intestine, there can be distinguished two forms: the segmentary infraction – the most frequent form, [27] in which the leisure can have a length between a few centimeters to the maximum of 40-50 centimeters. In this form the affected most part is the ileum, also some part of the jejunum and the upward colon and the total or subtotal infraction [28] – which affects all of the irrigated portion of the superior mesenteric artery.

In terms of clinical symptoms, the intestinal infarction caused by the veins is installed less brutal than the one caused by the arteries, only that the differential diagnose between the two forms cannot be made clinical, because both start with a period of digestive discomfort, followed by anorexia, moderate abdominal aches, sometimes vomiting which do not ease the pain. From the moment when the intestinal leisures become irreversible, the symptoms are very noisy.

Clinical, the mesenteric infarction is characterized through the following events:

- abdominal pain of high intensity, generalized, persistent, frequently in the mesogastrium;
- state of shock with tendency of collapse;
- stop of intestinal transit for faeces or gas;
- vomiting.

The X-ray examination, shows the distension of the small intestine which has three specific characterizations:

- equal bubbles of gas,
- air in jejunum,
- lack of peristaltic,

at the opening of the peritoneum we can find a infarcted loop very relaxed, whit thick walls, opaque. In the intestinal lumen we can find modified blood and in the peritoneum we can find flowed fluid.

Clinic study

As I have stated the disease is extremely rare in a child or teenager but there are situations with undetermined etiology that lead to the appearance of this disease.

At a such case I stepped in surgically, the patient being 16 years old. She was initially hospitalized in the pediatric clinic. In the description the patient had diffused abdominal pain, found predominant in the epigastrium (which at the beginning have been like a epigastrium distress, the primary cause being the eating in our days), vomiting, malaise.

With approximately 6 months before, the child had another hospitalization for a stomach pain, being labeled now as a new spurt in the same disease as “antroduodenal dyskinesia”.

After hospitalization there have been made minimum paraclinic and laboratory investigations and there has been established a treatment for electrolyte rebalance and pain removal. The results of the investigation were in normal parameters, only a leukocytosis of 17700/mm and a erythrocyte sedimentation rate of 20/hour. The general state of the patient continued to get worse, the pains from the epigastrium have increased in intensity and have slowly placed themselves in the periumbilical area, vomiting became more frequent, and the intestinal transit for gas and faeces was interrupted. The following day after hospitalization the recomandation was a abdominal X-Ray while standing, which showed a important intestinal distention, without seeing the hydroaeric levels. The abdominal ultrasound also showed a significant dilatation of the intestine, visible intestinal plies, absence of peristaltic,

and at the bottom of the Douglas bag and the Morrison space, a huge quantity of fluid.

The ultrasound diagnose was a recent intestinal occlusion, with transudate liquid in the peritoneum cavity. At the Gynecological Exam there were discovered clots and menstrual blood inside the vagina, utter and impalpable annexes, put together in a enormous tumor mass. In these conditions, a surgical advice was asked for, from which it was determined that it was a teenager, with asthenic constitution, longilina physical constitution , underweight, with a suffering look, ringed, pale, with the nose wing-beats, placed in a antalgic antalgic position. On palpation, was observed an abdomen with both spontaneous pain and especially stylus, located in hypogastrium and periombilical, with generalized muscle contracture. Digital rectal exam showed a sficter sphincter with normal tonicity, additional rectal wall, rectal ampoule blank, Douglas bag bulging bottom, painfully. On bimanual palpation was felt a tumor in hypogastric region who occupy the small pelvis, very sensitive. The examination of skins didn't show scarlet elements or petechiae that could prove that it is a thrombocytopenic purpura. For this reason, and because of palpation of the hypogastrium of that formations, has been a suspected ovarian cyst torsion, whose symptoms are similar, but also took the discussion a bowel obstruction (the radiography didn't revealed the hidroaeric levels), a nefretica colic, one pancreatitis (pain ought to be in the bar) or a ruptured ectopic pregnancy ((negative gynecological examination).

It was decided, after all examinations, emergency surgery.

It entered on a xifopubiana incision, and on opening the peritoneum poured a significant amount of sero-bloody fluid. In the small pelvis was discovered a cluster of bowel loops, black, non viable, with walls edematiate edema filled with blood clots "heavy" because of the content, and the display of necrotic bowel was found that is the chance that the small intestine which corresponded to a necrotic mezou mesentery , in up, based at the mezostenica mesostenic edge of the bowel and the top by the root of mesentery (Fig. 2).

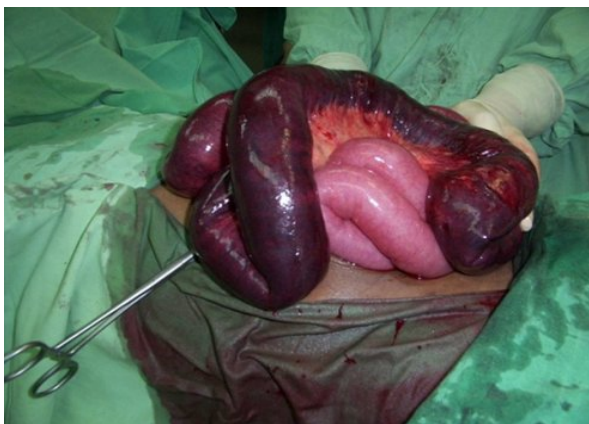

Fig. 2 Intraoperative aspect.

Necrotic bowel ends were clearly demarcated areas of viable. Necrotic area began in the terminal portion of the jejunum and continues with the ileum to about 20-30 cm by

the ileocaecal valve, meaning a segmental bowel infarction. With regard to intestinal necrosis that required resection of non-viable portion was approximately 0.80 to 1 m.

Resection was done in the area viable, above the necrotic portion and even under of the necrotic portion in healthy intestinal. After resection was done anastomosa termino-

terminal in a layer, and bowel resection was sent to the pathological examination (Fig.3).

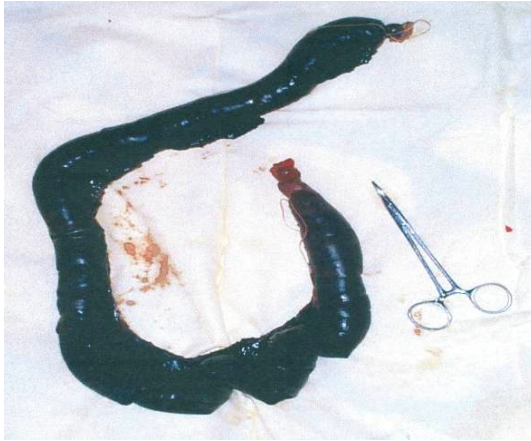

Fig. 3 Snare resection.

Postoperatively, the teenager received electrolyte rebalancing treatment, vitamin-antibiotic therapy, to sustain the general state, diet and protection of the anastomosis.

Intestinal gas transit has been resumed at 5 days postoperatively, and the faeces after 7 days. At 11 days postoperatively, the patient was discharged with diet and life tips. On the first postoperative control, patient's general condition was normal, appetite returned, bowel present. I considered this as a quick adaptation to the small size of the jejuno-ileum, even if the absorption area had decreased.

At about 10 days after discharge, the child readmission, with identical symptoms (vomiting, abdominal pain, intestinal transit stop for gas and faeces), only, at the simple abdominal radiograph, made in standing, is worked out hydroaeric levels, radiographic characteristic of intestinal obstruction. There was surgery and has been found an intestinal obstruction by a bracket, located above the anastomosis which led to suffering. Postoperatively, the evolution was normal and the child was able to be discharged after 14 days. Reviewed periodically for 2 years (first three months every year and next year every 6 months,

then she disappeared from the records), the patient didn't showed "short bowel", its development being normal.

Conclusions

I presented this case rare for pediatricians (surgeons or internists), because is an uncharacteristic affection disease for a child and the specialty literature (pediatric surgery) doesn't mention it. Just the pediatric books mentioned it as a possible complication of thrombocytopenic purpura. Researching the hospital archive I found only one case of a sick girl of 16 years, known with purpura trombocitopenica thrombocytopenic purpura but it all ended in exitus, diagnosis of mesenteric infarction was made when was made the necropsy.

Particularity of the case is that it appeared at a teenager of 16 years age, which may have contribuit contributed and its constitution (asthenic), and perhaps, and last but not least predisposing land.

This diagnosis should be considered in the differential diagnosis when pediatric surgeon or internist is also facing a serious pain.

References

1. Lepadat D. Intestinal infarction. Ed. Medicala, Bucuresti;1973 [1-2,5,14.23-25,27-28]
2. Simici P. Elements of intestinal surgery. Ed. Medicala, Bucuresti; 1976 [3-4,15-19,26]
3. Stoica T. Controversies and dilemmas in digestive surgery. Ed. Litera, Bucuresti; 1985 [6-8,20-22]
4. Vereanu D. Socolescu M. Steinbach T. Emergency Infant Surgery. Ed. Medicala, Bucuresti; 1958 [9-13]

Correspondence to:

Virgil Corneliu Cristea
Gheorghe Asachi Street, No.2,
Galați, Romania
Phone: +4 0236 469100
E-mail: virgilcristea@yahoo.co.uk