

## CONGENITAL RUBELLA SYNDROME – CASE REPORT

I Velea<sup>1</sup>, Corina Paul<sup>1</sup>, Florina Căpitan<sup>2</sup>, A Lăcătușu<sup>1</sup>, Ionela Tămășan<sup>1</sup>, Cezara Mureșan<sup>3</sup>, Luiza Badescu<sup>4</sup>, C Șchiopu<sup>1</sup>

### Abstract

Congenital rubella syndrome is a group of physical abnormalities that have been developed in an infant as a result of maternal infection and subsequent fetal infection with rubella virus. Rubella is a common cause of maculopapular rash illness with fever. The disease has few complications unless it is contracted by a pregnant woman. Rubella infection in pregnancy can lead to miscarriage, stillbirth, or an infant born with congenital rubella infection. The paper presents the case of a patient who came into our service for the first time in 2004 with some severe symptoms and signs. The first diagnostic was diabetic ketoacidosis stage III (ketoacidotic coma), but after that, the child comes into the Hospital several times more along the following years for reevaluation, when other complications are revealed.

**Key words:** Congenital rubella syndrome, diabetes mellitus, cardiac malformations, delayed diagnose

### Background

Congenital rubella syndrome is a consequence of rubella infection that can occur when the virus is transmitted in utero during maternal primary infection [1].

When infection occurs in the first 11 weeks of pregnancy, babies presents heart defects and deafness; between weeks 13 to 16 only deafness. When infection occurs after 16 weeks, newborns don't have any congenital defect [2]. So, fetal pathology is common when infection occurs in the first 16 weeks of pregnancy. Pathogenic mechanisms of teratogenic effect induced by rubella are not well known, the most common hypothesis is to suggest direct involvement of viral replication in cell clones during fetal organogenesis [3]. In classical acceptance, congenital rubella syndrome is the triad consists of: cataracts, deafness and heart defects. Cataracts and microphthalmia occur in 1/3 of cases [4]. Sensory or central deafness is the most common sequel, appears at a rate of 80% of infected children [5]. It is the only event that can come as isolated congenital rubella. In addition to congenital syndromes, maternal infection near term is commonly associated with fatal neonatal diseases, possibly due to fetal exposure to

transplacental viremia in the absence of maternal protector antibodies. Passive immunization with immunoglobulins does not guarantee fetal safety [6].

### Case presentation

#### First hospitalization:

Clinical examination revealed an 12 years old infant with the following parameters: weight = 36 kg, height = 140 cm, ideal waist for age =  $149,32 \pm 7,5$  cm, ideal weight for current waist =  $32,01 \pm 6,6$  kg, age current waist = 10,5 years (Fig. 1).

Family history of child comes from G II, P II, gestational age (GA) = 37 weeks, birth weight 2000 g, 49 cm, 1,69 ponderal index (P.I. =  $G/T3 \times 100$ ), intrauterine growth restriction, breastfed up to 1 year and 6 months.

Clinical examination on admission revealed: general condition deeply altered, obnubilation, pale, warm, dry, rough skin, subcutaneous tissues completely disappeared from the trunk and limbs, dry mucous, dry, friable hair and nails, muscular system - hypotonia, hypotrophy, hypokinetic, cardio-respiratory system- asthenic chest, respiratory rate = 22 breaths/min, pearly white linear scar on the midline from the sternal manubrium to the epigastric region after surgical procedure, pulse rate = 104 beats/min, systolic murmur II degree, closing click, digestive system – oral infection, carmine dry lips, splenomegaly.

Laboratory investigations revealed: total bilirubin - 5.62 mg / dl (N = 0.1 to 1.1), lipids – 3215mg/dl (N = 400-800 mg / dl) cholesterol – 603 mg/dl (n = 0 - 200 mg / dL), triglycerides - 1768mg/dl (N = 28-127 mg / dl), blood sugar – 817 mg% (N = 80-120 mg%), HbA1c - 16% (N = 4,5 - 7%) . Normal eye exam. EKG - sinusal rhythm, HR = 100 beats/min, electric axis deviated to the left, right bundle branch block.

Echocardiography: Bicuspid aortic valve without regurgitation, intact interatrial septum. In the left ventricle, it is highlighted a single posteroinferior pillar. Mitral valve regurgitation to the posterior wall of the left atrium, I/II degree. Without liquid in the pericardium. Conclusion: heart surgery, mitral regurgitation, I/II degree.

<sup>1</sup>Department II Pediatrics, University of Medicine and Pharmacy “Victor Babes” Timisoara

<sup>2</sup>University of Medicine and Pharmacy “Victor Babes” Timisoara

<sup>3</sup>Bega University Clinic, Obstetrics-Gynecology Department, University of Medicine and Pharmacy “Victor Babes” Timisoara

<sup>4</sup>Integrated Ambulatory – Pediatrics Department, County Hospital Timisoara

E-mail: ivelea56@yahoo.com, paulcorina@yahoo.com, capitanflorina@yahoo.com, adilacatusu@yahoo.com, ionilop@yahoo.com, drmuresan@gmail.com, luiza\_afrim@yahoo.com, catalin.cris@yahoo.com

Infantile neuropsychiatry examination: Babinski cutaneous-plantar reflex positive to the left on stimulation. Normal EEG without pathological graphoelements. Psychological evaluation: medium mental retardation, IQ = 57 (Raven Test). Slow thinking. Emotional immaturity.

Genetic consult: particular phenotype, oblique palpebral fissure, hypertelorism. Narrow forehead, septum deviation. Geographic tongue (Fig. 2). Slow writing, chaotic dermatoglyphism, fifth finger clinodactyly (Fig. 3).



Figure 1. Staturponderal delay.

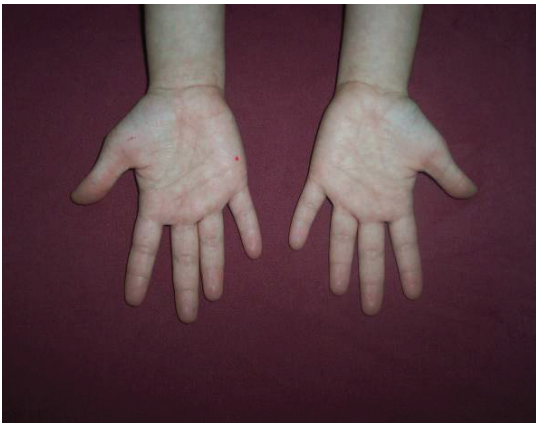

Figure 3. Fifth finger clinodactyly.

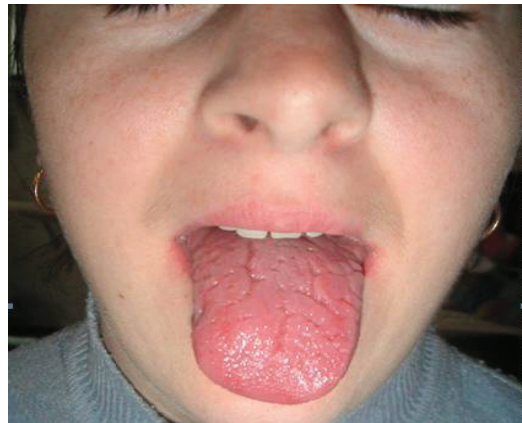

Figure 2. Geographic tongue.

Normal karyotype. The insulin-dependent diabetes mellitus diagnostic is confirmed and it is established venous perfusion with insulin and diet. Only after five days is resorting to subcutaneous injections insulin therapy + diabetes diet type divided into 6 meals/day. Since history shows that classic symptom onset diabetes (polyuria, polydipsia, weight loss) lags behind at least 4-5 months which is a contrast to the way the child onset diabetes!

*Pathological personal history:* Heart surgery in 1997 for: mitral insufficiency by mitral valve cleft of previous ventricular septal defect, persistent foramen ovale, pulmonary hypertension, the aberrant insertion of the secondary tendinous cords of the anterior mitral valve in the right ventricle.

In evolution: laboratory, positive C-reactive protein, positive ELISA HBS Atg, HbA1c = 8,8% oriented towards the diagnosis of chronic hepatitis with B type hepatitis. At 8

months after diagnosis of type 1 diabetes are seen: polynodular goiter, confirmed by ultrasound and hormonal dosages and it has been administered substitution treatment with L-thyroxine.

Simultaneously, the emergence of a progressive and rapidly developing bilateral cataracts which requiring surgery are seen (bilateral lens implant) at just 1 year after the onset of type 1 diabetes (Fig. 4). Pubertal retardation - Tanner I/II at the age of 14,5 years. Menstrual cycles are irregular (oligo/dysmenorrhea) at 4-5 months. Gynecological exam: normal. Bone age corresponding chronological age. Sella turcica X-Ray: normal shape and size. Following insulin replacement therapy in 4 injections/day, diabetes diet type divided into 6 meals/day, associated with thyroid substitution treatment, in the period 2004 to 2010 a weight increase of 5 kg (37-42 kg) and a stature increase of only 0,5 cm occurs.

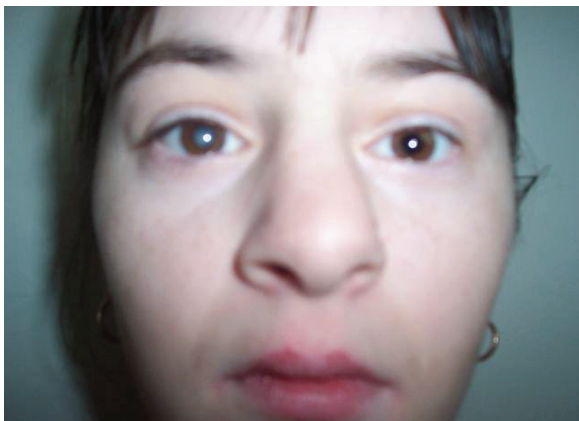


Figure 4. Rapidly progressive cataract (initially on the right eye).

\*Photographs were made with mother agreement, respecting the ethical principles and protection of the minor.

**Discussions**

The presented case is extremely complex both in terms of symptoms presented, a variety of disease complications of the revolving rapidly especially in the first period, and that of the period of time stretches. Accumulating these things, looking back and comparing this case with similar cases in the literature, concludes that in this case the disease is prenatal undiagnosed congenital rubella by PCR of amniotic fluid [7] and involving classical triad:

- ✓ Congenital heart disease, especially patent ductus arteriosus (50% of patients) [8],
- ✓ Eye abnormalities, especially cataract and microphthalmia (43% of patients) [9],
- ✓ Sensorineural deafness (58% of patients) [5].

Other manifestations of CRS may include:

- ✓ Diabetes type III (!) - at this age, type 1 diabetes (insulin dependent diabetes) has classical clinical symptoms duration of maximum 30 days (intermediate onset type). Type 2 diabetes has a genetic load of 80-90% of cases [10], which **has not been found** in our case.
- ✓ Mental retardation
- ✓ Eye defects
- ✓ Low birth weight
- ✓ Developmental delay
- ✓ Growth retardation
- ✓ Learning disabilities
- ✓ Spleen, liver or bone marrow problems (some of which may disappear shortly after birth)

- ✓ Small head size (microcephaly)
- ✓ Thrombocytopenic purpura (presents as a characteristic blueberry muffin rash)
- ✓ Hepatomegaly
- ✓ Micrognathia
- ✓ Schizophrenia
- ✓ Glaucoma

The consequences of congenital rubella syndrome occurs during the whole life, at any time there is a risk for a new diseases to appear, such as thrombocytopenic purpura, paranoid schizophrenia [11], glaucoma or worsening the one that are already present. Once again we must emphasize the importance of preventing maternal-fetal infection during pregnancy because so far no one has developed an effective therapy for congenital rubella virus and the passive immunization with immunoglobulins does not guarantee fetal safety.

According to ISPAD Clinical Practice Guidelines, diabetes is classified as [10]:

**I. Type 1**

β -cell destruction, usually leading to absolute insulin deficiency

- A. Immune mediated
- B. Idiopathic

**II. Type 2**

May range from predominantly insulin resistance with relative insulin deficiency to a predominantly secretory defect with or without insulin resistance.

**III. Other specific types**

Genetic defects in insulin action	Infections	Drug or chemical-induced
1. Type A insulin resistance	<b>1. Congenital rubella</b>	1. Vacor
2. Leprechaunism	2. Cytomegalovirus	2. Pentamidine
3. Rabson-Mendenhall syndrome	3. Others	3. Nicotinic acid
4. Lipoatrophic diabetes		4. Glucocorticoids
5. Others		5. Thyroid hormone
		6. Diazoxide
		7. β-adrenergic agonists
		8. Thiazides

Table 1. Specific types of diabetes, (Craig ME, Hattersley A, Donaghue KC. Definition, epidemiology and classification of diabetes in children and adolescents. Pediatric Diabetes 2009).

**Conclusions**

This case presentation wants to be a looking back, a review of the case and an alarm sign pulled by us according to rubella congenital syndrome which can be very difficult to anticipate and to be diagnosed on a child in this stage.

The facts that we discussed in this paper are pleading for rubella congenital syndrome diagnose and unfortunately this doesn't change anything in the medical evolution of the

case. This is why we tried to expose the facts chronologically to clarify other diagnostic possibilities, to explain for the clinicians the options, to understand, to recognize and to treat a similar case when they are in the position to do it.

Nevertheless, we want to highlight once more the importance of the screening for bacterial and viral infections in pregnancy.

**References**

1. Robert-Gnansia E, Congenital rubella syndrome. Orphanet Encyclopedia, November 2004
2. Jenkins KJ, Correa A, Feinstein JA, et al. 2007. Noninherited risk factors and congenital cardiovascular defects: current knowledge: a scientific statement from the American Heart Association Council on Cardiovascular Disease in the Young: endorsed by the American Academy of Pediatrics. *Circulation* 115(23):2995–3014.
3. De Oliveira SA, Camacho LA, de Medeiros Pereira AC, et al. Performance of rubella suspect case definition: implications for surveillance. *Rev Saude Publica*, 2006; 40:450–6.
4. Robinson JL, Lee BE, Preiksaitis JK, et al. 2006. Prevention of congenital rubella syndrome—what makes sense in 2006? *Epidemiol Rev* 28:81–87.
5. Griffin DE (2006) Alphaviruses. In: Knipe DM, Griffin DE, Lamb RA, Martin MA, eds. *Fields Virology*. 5th edition. Philadelphia: Lippincott, Williams & Wilkins. pp 1023–1068.
6. Wong LM, Medrano J (2005) Real-Time PCR for mRNA quantification. *Bio- Techniques* 39: 75–85.
7. Mace M, Cointe D, Six C, Levy-Bruhl D, Parent du Chatelet I, Ingrand D, Grangeot-Keros L. Diagnostic value of reverse transcription-PCR of amniotic fluid for prenatal diagnosis of congenital rubella infection in pregnant women with confirmed primary rubella infection. *J Clin Microbiol.* 42 : 4818-20 (2004)
8. Matthew E. Oster, Tiffany Riehle-Colarusso, Adolfo Correa. An Update on Cardiovascular Malformations in Congenital Rubella Syndrome. *Birth Defects Research (Part A)* 88:1\_8 (2010)
9. P Vijayalakshmi, T Amala Rajasundari, Noela Marie Prasad, et al., Prevalence of eye signs in congenital rubella syndrome in South India: A role for population screening. *Br J Ophthalmol* 2007; 91:1467–1470.
10. Surveillance Guidelines for Measles, Rubella and Congenital Rubella Syndrome in the WHO European Region, World Health Organization 2009, pp 1-48
11. Alan S Brown, Prenatal Infection as a Risk Factor for Schizophrenia, *Schizophr Bull* (2006) 32 (2): 200-202

Correspondence to:

Iulian Velea  
V. Babes Street, No.12,  
Timisoara, Romania  
Phone: +4 0256 491747  
E-mail: ivelea56@yahoo.com