

## DENTAL AND CRANIOFACIAL ANOMALIES IN A PARTICULAR CASE OF TURNER PHENOTYPE

C Capitaneanu<sup>1</sup>, Valerica Belengeanu<sup>1</sup>, Ioana Micle<sup>2</sup>, Ioana Maris<sup>2</sup>, Mihaela Cernica<sup>2</sup>, D Belengeanu<sup>1</sup>, Noemi Meszaros<sup>1</sup>, Eugenia Capitaneanu<sup>3</sup>

### Abstract

Turner syndrome (TS) is a genetic disorder associated with abnormalities of the X chromosome, occurring in about 50 per 100 000 liveborn girls. We present the case of a 9 year old girl, admitted to the Children's Hospital "Louis Turcanu" Timisoara, Pediatric Clinic I in november 2008, because of short stature and particular phenotype, in order to establish a complete diagnosis. The clinical and paraclinical features for the diagnosis of Turner syndrome were represented by: dysmorphic dwarfism, particular phenotype, karyotype - homogenous total X monosomy, renal malformation, hearing impairment. Dental clinical examination, extraoral and intraoral orthodontic investigation, cephalometric examination and pantomographic investigation revealed the following modifications: high palate, macroglossia, hypoplastic low face level, enamel hypoplasia, dental-alveolar dysarmony with squashing at the mandibular arch level, simple superficial caries of the occlusal face. Therapy included correction of short stature with growth hormone administration, treatment of caries and orthodontic treatment. Particularity of this case is due to the extremely rare renal malformation – "pancake kidney", and to the uterine agenesis, which is not characteristic for this syndrome.

**Key words:** Turner syndrome, dental and craniofacial anomalies, child

### Introduction

Turner syndrome (TS) is a genetic disorder associated with abnormalities of the X chromosome, occurring in about 50 per 100 000 liveborn girls. TS is usually associated with reduced height, gonadal dysgenesis and thus reduce levels of female sexual hormones and sterility/infertility. The average intellectual performance is within the normal range.

The genetic background of the TS phenotype is highly variable, but includes complete or partial absence of the sex chromosomes (the X and/or Y chromosomes). In addition, mosaicism with two or more cell lines may be present. The first described cases were with the 'classical' karyotype 45,X. In more recent series the classical karyotype only

accounts for 50% of cases; the remaining cases comprise mosaic karyotypes (i.e. has cells with 45,X and cells with 46,XX), karyotypes with an isochromosome of X—for example i(Xq) or i(Xp)—or karyotypes with an entire or part of an Y chromosome<sup>1</sup>. The genetic basis for the findings in TS is being further unravelled as the functions of the *SHOX* gene become clearer. Haploinsufficiency of *SHOX* explains the reduction in final height, changes in bone morphology, sensorineural deafness and other features. However, additional genes are thought to be involved in the pathogenesis of TS, but await new discoveries.

### Case presentation

*Giulia B.*, 9 years old, with a history of recurrent urinary tract infections (UTI), diagnosed with horseshoe kidney in 2003, is first admitted to the Nephrology Department, Paediatric Clinic I, Children's Hospital "Louis Turcanu" Timisoara, in 19.11.2008, presenting short stature and particular phenotype, in order to establish a complete diagnosis.

She is the first borne of a young, healthy couple, with good socio-economic background, pregnancy with abortion risk, periodically hospitalized for treatment, birth age 40 weeks, normal birth in cranial presentation, birth weight = 2000 g, height = 48 cm, Apgar score 8, no physiologic jaundice, formula nutrition from birth, ricketts prophylaxy and immunisation scheme complete.

Family history is not significant, personal medical history reveals a suspicion of malabsorption syndrome at 1 year of age, recurrent UTIs between 2 and 4 years of age (horseshoe kidney diagnosed by CT), at the age of 9 subperiosteal fracture of 1/3 inferior right tibia, and an adenoidectomy before the admission; the otorhinologist also diagnosed hearing impairment and noticed the short stature, recommending further investigations.

**1. Physical examination** at admission reveals (Fig. 1,2):

- Real Height = 110 cm ; Age Height = 131,61+/-6,1 cm; Growth deficit = -16% (under 3<sup>rd</sup> percentile 3, -3,5 SDS)
- Chronological Age = 9 years 5 month; Height Age = 5 years

<sup>1</sup>University of Medicine and Pharmacy "Victor Babes" Timisoara

<sup>2</sup>Children's Hospital "Louis Turcanu" Timisoara, Pediatric Clinic I

<sup>3</sup>Dental Practice "Dr. Eugenia Capitaneanu", Braila

E-mail: capitaneanucezar@yahoo.co.uk, belvtim@yahoo.com, ioanamicle@yahoo.co.uk, ioanadmaris@yahoo.co.uk, miha\_cernica@yahoo.com, dragosbele@yahoo.com, noemi\_my@yahoo.com, medartes\_clinique@yahoo.co.uk

- Real Weight = 24 kg; Weight corresponding to real Height = 18,59±2,76 kg; BMI = 19,8 kg/m<sup>2</sup> (over 97<sup>th</sup> percentile)
- Morphogram reveals a dysmorphic dwarfism: Cranial perimeter = 53 cm (+0,8 SD); Thoracal perimeter = 66 cm (+0,7 SD); Abdominal perimeter = 63 cm (+1,4 SD) ; Pelvic perimeter = 66 cm (-0,7 SD); Biacromial distance = 29 cm (+0,4 SD) Manubrium-ground distance = 90 cm (-3 SD), Pubis-ground distance = 55 cm (+2,8 SD), Bitrochanterian distance = 27 cm (+2,3 SD).

- Phenotype features: microretrognathia, dental anomalies, high-arch palate, assymmetric low-set ears, with a larger left ear, low M-shaped hairline, short neck, biacromial diameter > bitrochanterian diameter, Kosowitz sign present, broad chest (*shield chest*) and widely spaced nipples, genu valgum, increased weight. The rest of the physical exam revealed no modifications regarding the different organs and systems.

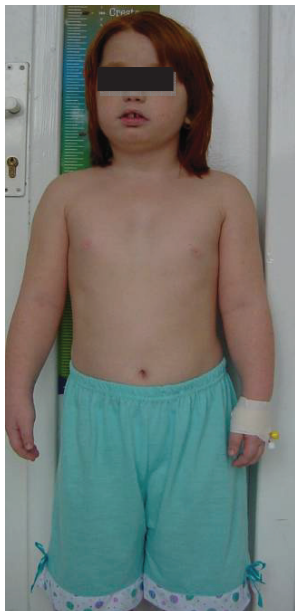


Fig. 1. Dysmorphic Short Stature.

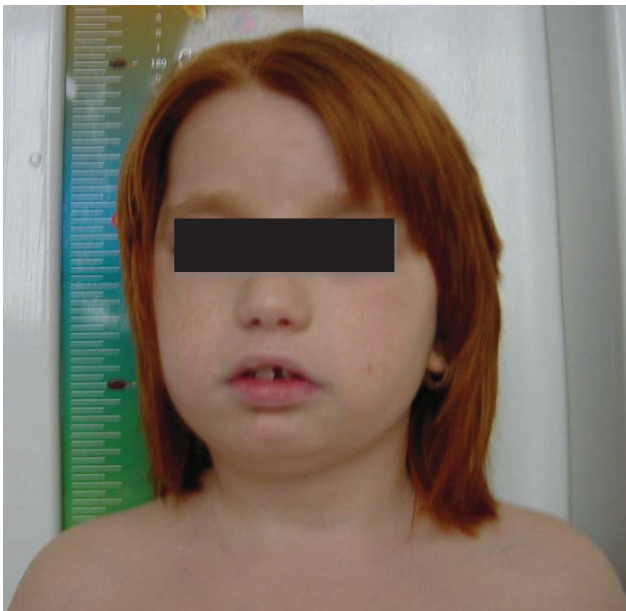

Fig. 2. Particular Phenotype.

2. Clinical diagnosis raised the suspicion of Turner syndrome (TS), based on the association of short stature + particular phenotype + hearing impairment + renal malformation.

3. Differential diagnosis was mainly made between the following syndromes, considering clinical features that are for or against the suspected diagnosis:

	FOR	AGAINST
<b>TURNER SYNDROME</b>	<ul style="list-style-type: none"> <li>• only female affected</li> <li>• short stature</li> <li>• dental anomalies, high-arch palate</li> <li>• asymmetric, low-set ears, low M-shaped hairline</li> <li>• short neck</li> <li>• biacromial diameter &gt; bitrochanterian diameter, Kosowitz sign present</li> <li>• shield chest</li> <li>• widely spaced nipples</li> <li>• genu valgum</li> <li>• renal malformations, horseshoe kidney, ovarian dysgenesis, karyotype 45x</li> </ul>	<ul style="list-style-type: none"> <li>• transient lymphedema of hands and feet</li> <li>• cranio-facial dysmorphism (triangular face shape, epicanthal folds)</li> <li>• pterigium coli</li> <li>• short metacarpian of finger IV, hyperconvex, soft upturned nails</li> <li>• cardiac malformations, karyotype 45x/46xx, 46xdel(x)</li> </ul>
<b>NOONAN SYNDROME</b>	<ul style="list-style-type: none"> <li>• short stature 25 %</li> </ul>	<ul style="list-style-type: none"> <li>• both sexes equally affected</li> <li>• drooping of the eyelids, epicanthal folds, strabismus, hypertelorism</li> <li>• pectus excavatum or carinatum</li> <li>• normal karyotype</li> </ul>

	FOR	AGAINST
<b>DOWN SYNDROME</b>	<ul style="list-style-type: none"> <li>• short stature</li> <li>• short neck</li> <li>• bilateral hearing impairment</li> </ul>	<ul style="list-style-type: none"> <li>• up slanting palpebral fissures, small nose, microgenia, macroglossia, protruding tongue</li> <li>• strabism</li> <li>• short and wide hands, bradidactilia, clinodactilia of finger V, simian crease</li> <li>• visceral malformations (duodenal atresia, anal imperforation), cardiac malformations, severe mental retardation, karyotype 47xx/47xy</li> </ul>
<b>GH DEFICIENCY</b>	<ul style="list-style-type: none"> <li>• short stature</li> </ul>	<ul style="list-style-type: none"> <li>• doll face, retrognathia, thin skin with freckles</li> <li>• high voice</li> <li>• small genitalia</li> <li>• sexual development can be normal</li> </ul>

We also took in consideration for the differential diagnosis several disorders such as: achondroplasia, pure gonadal dysgenesis, hypothyroidism, cortisole excess, chronic cardiac, pulmonary, renal and digestive diseases, all of them associated with growth failure.

4. In order to establish a complete and correct diagnosis we performed the following investigations:

- *Karyotype*: indirect method of chromosomes analyse was performed, using the GTG banding technique, a number of 20 metaphases were cytogenetically evaluated, and the karyotype was performed computer-assisted. The presence of a numeric chromosomal anomaly was established by the standard cytogenetic method: homogenous total X monosomy, no presence of any cell with normal karyotype, so a mosaicism is excluded. *Cytogenetic Diagnosis: homogenous total X monosomy.* (Fig. 3)
- *Bone age Xray*: bone age corresponding to the chronological age of 7,9 years, growth cartilages present.
- *Evaluation of glucides metabolism*: oral glucose tolerance test with 45 g glucose: a jeun glicemia = 57mg% (venous blood), 2h glicemia = 122,5mg% (venous blood)
- *Hormonal status* – to exclude GH defficiency – normal values for IG F1 = 139 ng/ml (november 2008), and basal GH = 0,06 ng/dl were detected, insulin stimulation test with 0,1U/kgc showed no modifications.
- *Biologic investigations*: Leukocytes = 8.670/mm<sup>3</sup>, RBC = 5.030.000/mm<sup>3</sup>, Hb = 13,2 g/l, Ht = 41,2 %, Trombocytes = 418.000/mm<sup>3</sup>, ESR = 10 mm/h, GPT = 16 U/l, GOT = 40 U/l, Na = 140 mmol/l, K = 5 mmol/l, Ca++ = 1,17 mmol/l, Alkaline phosphatase = 156 U/l, pH = 7,38, pCO<sub>2</sub> = 30,2 mmHg, pO<sub>2</sub> = 54,3 mmHg, HCO<sub>3</sub> = 17,5 mmol/l, BE = -7,5 mmol/l, BUN = 5,2 mmol/l, Creatinine = 40µmol/l, Uric acid = 334µmol/l, Cl creatinine = 134,4 ml/min, Urinalysis: albumine traces, frequent leukocytes, rare epithelia, frequent bacteria, Urine culture: >100000 germs/ml E.coli
- *Otorhynologic exam*: left chronic mucous otitis media, mild right chronic otitis media. Audiogram: *severe mixte hearing loss left ear.*

- *Cardiologic exam*: normal cardiac rhythm, 110-120 beats/min, systolic murmur grade I in Erb focus, perypheric puls present, BP=100/60 mmHg; *EKG*: sinusal tachycardia, 130/min, intermediary QRS axes, PR=0,12 sec.; *Cardiac Ultrasound*: normal.
- *Ophthalmologic exam*: hypermetropic astigmatismus
- *Psychologic exam*: polymorphic dislalia, anxious disposition, concentration deficit, QI=74 (Raven)
- *Abdominal ultrasound* (Fig. 4): liver with normal structure, right hepatic lobe = 95 mm, portal vein = 4,24 mm, free gallbladder, right kidney with no differentiated structure, situated anterior to the spinal cord, 50/20 mm, left kidney normal situated, 47/13 mm. Spleen with normal structure, splenic axe = 109 mm. Urinary bladder with normal walls. Conclusion: bilateral renal hypoplasia, ectopic right kidney. *Pelvis ultrasound*: no evidence of internal genitalia.
- *MRI*: reveals the "pancake" kidney, an extremely rare anomaly of renal ascent and subsequent fusion (Fig. 5a, 5b).
- *Pelvis MRI*: no visualisation of uterus and ovaries. Urinary bladder without parietal or intracavitary modifications. No ascites. No intrapelvic or inguinal adenopathies. Conclusion: agenesis of uterus and ovaries.
- *Dental examination* – clinical examination, extraoral and intraoral orthodontic investigation, cephalometric examination and pantomographic investigation revealed the following modifications (Fig. 6):
  - Dynamic and static occlusion instability, sagital inoclusion
  - High palate, small retrogenic mandible, macroglossia, hypoplastic low face level
  - Hypoplasia of enamel and changes in the shape of teeth's roots
  - Dental formula: mixt dentition, 21 rotated mesio-distal, 22 palatinised eruption, diastema
  - Dental-alveolary dysarmony with squashing at the mandibular arch level
  - 16, 26, 36, 46 – simple superficial caries of the occlusal face



Fig. 3. Karyotype 45,X.

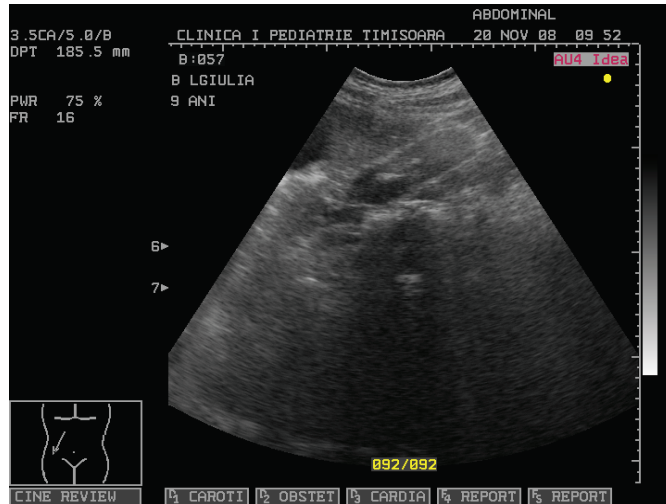


Fig. 4. Abdominal ultrasound.

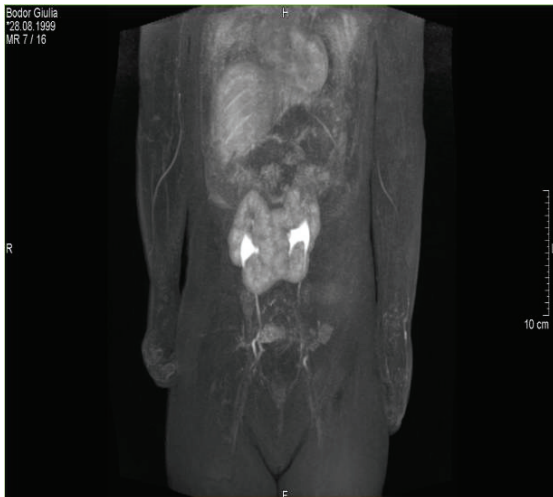

Fig. 5a. MRI.

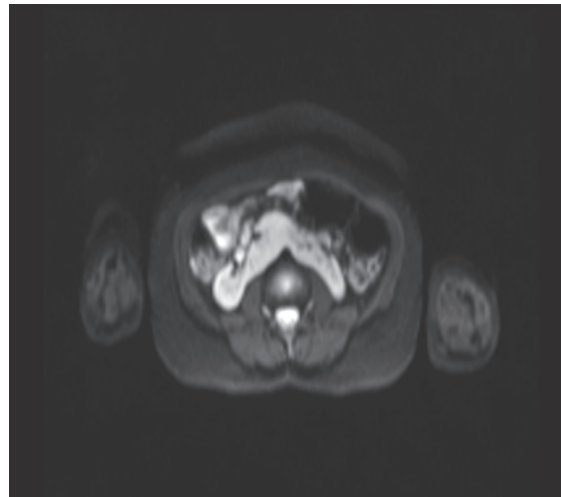


Fig. 5b. MRI.

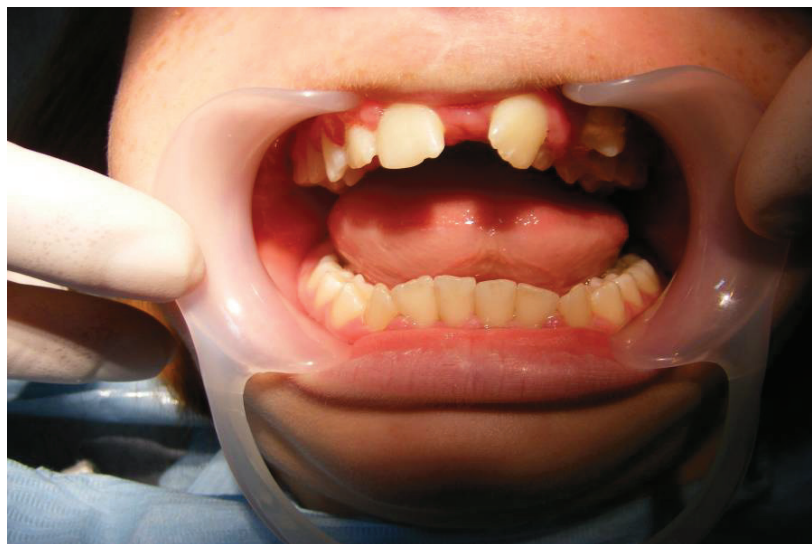

Fig. 6. Dental anomalies.



5. Diagnosis: 1. Turner Syndrome 2. "Pancake" Kidney 3. Urinary Tract Infection with E Coli 4. Severe Mixt Hearing Loss Left Ear 5. Obesity grade I 6. Uterine Agenesia 7. Hypermetropic Astigmatismus 8. Polymorphic Dislalia, sustained by :

1. Turner Syndrome: characteristic clinical features, karyotype, renal malformation, hearing loss
2. "Pancake" Kidney: abdominal MRI
3. Urinary Tract Infection with E Coli: urine culture
4. Obesity grade I: BMI = 19.8 kg/m<sup>2</sup>
5. Uterine Agenesia: pelvic MRI
6. Hypermetropic Astigmatismus: ophthalmologic exam
7. Polymorphic Dyslalia: psychological exam

#### 6. Treatment

- *prophylactic* – prenatal diagnosis:
  - couples that already have a child with TS have a no significant risk of giving birth to another child with the same disease, but a genetic counseling before another pregnancy is recommended
  - Turner syndrome may be diagnosed by amniocentesis during pregnancy, chorionic villus biopsy, or percutaneous umbilical cord blood sampling, followed by chromosomal analysis using classical or cytogenetically methods.
  - triple test - second trimester maternal serum screening can check levels of alpha fetoprotein, β-hCG, inhibin-A, estriol, and h-hCG in the woman's serum. When alpha fetoprotein and estriol are low and hCG is high triple test is positive for TS.
- *diet*: hypocaloric, hypolipidic, avoiding food products with > 50% glucides, normoproteic
- *hormonal therapy* – there are different treatment schemes, related to age and possible complications, the main clinical features that will be concerned are *short stature and feminisation deficit*
- correction of short stature is made considering 3 age periods:
  - childhood (2-10 years) overdoses of growth hormone (GH) are administered – initiation in January 2009 in our case
  - after 11 years – Oxandrolone therapy for 1 – 1,5 years, (stimulates bone length growth)
  - after 12-13 years - estrogen and progesterone administration, continuous replacement therapy up to normal menopause age (40-50 years)
  - GH dose: 0,045mg/kg/day
- *feminisation deficit - etinilestradiole* - 0,025µg/kg/day
- role in developing secondary sexual features, puberty onset (spontaneous in less than 10% of the cases), social integration, osteoporosis prophylaxis, uterine growth improvement.
- *dental therapy* – preventive measures of dental hygiene, caries treatment performed at 6 year molars level, orthodontic treatment was recommended.

7. Evolution – Life expectancy is almost normal, exceptions are the cases with severe cardiac anomalies or renal malformations with risk for developing chronic renal failure.

8. Complications - In the adult period the patient can develop high blood pressure, obesity, diabetes mellitus, cataract, Hashimoto thyroiditis.

#### 9. Prognosis

- The only aspect that can not be corrected is infertility.
- Pregnancy is possible in cases with X monosomy mosaicism.
- Short stature and feminisation deficit can be corrected with proper therapy.
- Hearing impairment can be corrected by hearing aid - prosthesis
- Recurrent UTIs need prevention and follow-up.

10. Particularity of this case is due to the extremely rare renal malformation – "pancake kidney", and to the uterine agenesia, which is not characteristic for this syndrome.

#### Discussions

Turner's syndrome is defined as a congenital disease determining by quantitative and/or structural aberrations of one from two X chromosomes with frequent presence of mosaicism. Clinically it is characterized by growth and body proportion abnormalities, gonadal dysgenesis resulting in sexual infantilism, primary amenorrhoea, infertility, characteristic stigmata, anomalies of heart, renal and bones and the presence of some diseases like Hashimoto thyroiditis with hypothyroidism, diabetes mellitus type 2, osteoporosis, hypertension. Turner's syndrome occurs in 1:2000 to 1:2500 female livebirth. The most frequent X chromosome aberrations in patients with phenotype of Turner syndrome are as follows: X monosomy - 45,X; mosaicism (50-75%), including 45,X/46,XX (10-15%), 45,X/46,XY (2-6%), 45,X/46,X,i(Xq), 45,X/46,X,del(Xp), 45,X/46,XX/47,XXX; aberration of X structure: total or partial deletion of short arm of X chromosome (46,X,del(Xp)) isochromosom of long arm of X chromosome (46,X,(i(Xq)), ring chromosome (46, X,r(X)), marker chromosome (46,X+m). Searching of X chromosome and mapping and sequencing of genes located at this chromosome (such as SHOX, ODG2, VSPA, SOX 3) have made possible to look for linkage between phenotypes and adequate genes or regions of X chromosome<sup>2</sup>.

The loss of the X chromosome in girls with Turner syndrome (TS) affects the shape and the size of craniofacial structures. Comparative studies performed on groups of TS patients versus control subjects have followed clinical parameters completed with caphalometric examination on teleradiogram of the head, periapical, oclusal, panoramic, and orthopantomograms<sup>3,4,5</sup>. The decayed, missing, and filled permanent surfaces index for teeth was statistically higher in TS patients versus control subjects. Orthodontic anomalies were more frequent and more severe in TS patients. Approximately 78% of TS patients presented hypoplasia of enamel, 65% shortening of the roots and bifurcated roots, and 100% high arch palate. Incisor asymmetry, reduced crown size, narrower but of normal length alveolar arch of the maxilla and shorter and broader mandibular arch were also observed.

Females with Turner syndrome (TS), are characterized with palates that are narrow in width, normal in height and which are commonly associated with the presence of lateral palatine ridges<sup>6</sup>. The distance of the tongue from the palate is significantly longer in the TS subjects compared with the controls, indicating a low tongue position in TS. The TS subjects with prominent lateral palatine ridges have significantly narrower posterior palates compared with the TS subjects without lateral palatine ridges.

Another study performed on a group of 25 patients affected by TS, aged from 4 to 18 years, was selected and the data were compared to those of an age matched control healthy group. The caries index values in TS patients are higher in the permanent (6.4 vs. 3.9), mixed (0.5 vs. 0.75) and primary dentition (0 vs. 1). The mesio-distal diameter in

TS patients was significantly reduced for every tooth measured, in particular for the lower first permanent molar<sup>7</sup>.

The investigations confirm that numeric aberration of the X chromosome most likely affects the quantitative and qualitative excretion of amelogenin, so that teeth often present enamel defects – reduced crown size and enamel hypoplasia. High caries index values (DMFT) highlight the demand of early preventive measures mostly focused on special care patients.

A broad cooperative effort is ideal with the involvement of a large number of specialties; for example, we enjoy the participation of departments of pediatry, genetics, cardiology, gynaecology, dentistry, otorhinology, ophthalmology, nephrology and gastro-enterology.

#### References

9. Baena N, De Vigan C, Cariati E, et al. Turner syndrome: Evaluation of prenatal diagnosis in 19 European registries. *Am J Med Genet* (2004) 129A:16–20.
10. Lacka K, Turner's syndrome--correlation between karyotype and phenotype, *Endokrynol. Pol.*, 2005 Nov-Dec;56(6):986-93.
11. López ME, Bazán C, Lorca IA, Chervonagura A, Oral and clinical characteristics of a group of patients with Turner syndrome, *Oral Surg Oral Med Oral Pathol Oral Radio Endod*, 2002 Aug;94(2):196-204.
12. Szilagyi A, Keszthelyi G, Nagy G, Madlena M, Oral manifestations of patients with Turner syndrome, *Oral Surg Oral Med Oral Pathol Oral Radio Endod*, 2000, 89(5):577-84.
13. Pospieszynska M, Korman E, Abnormalities of the masticatory organ in Turner syndrome, *Endokrynol Diabetol Chor Przemiany Materii Wieku Rozw.*, 1998;4(1):39-43.
14. Perkiömäki MR, Alvesalo L, Palatine ridges and tongue position in Turner syndrome subjects., *European Journal of Orthodontics* 30 (2008) 163-168.
15. Faggella A, Guadagni MG, Cocchi S, Tagariello T, Piana G, Dental features in patients with Turner syndrome, *Eur J Paediatr Dent*, 2006, 7(4):165-8.

Correspondance to:

Cezar Capitaneanu  
 Letea 25,  
 Timisoara 300501,  
 Romania  
 E-mail: capitaneanucezar@yahoo.co.uk