

UNUSUAL PRIMARY HYDATID CYST FROM SOFT TISSUE IN CHILDREN: FOUR CASES AND REVIEW OF LITERATURE

Muazzez Cevik¹

Abstract

Objective: Hydatid cyst (HC) is a zoonosis caused by the larval stage of the Echinococcus tapeworm. The location of HC is usually hepatic and/or pulmonary. In the present study was evaluated 4 patients with primary HC (PHC) related the literature. The present first the largest series of PHC of the soft tissue in the literature

Cases and Presentation: An experience of a single surgeon was conducted of 4 cases of primary HC of unusual regions of the body treated between 2004 and 2011. Locations were axillary fossa, popliteal fossa, and thoracic wall. Patients were admitted with an initial diagnosis of lipoma, lymphadenitis, or other cystic lesions. The definitive diagnosis of PHC was made peroperatively and related histopathological examination.

Conclusion: A PHC disease should be considered in the differential diagnosis of cystic lesions in every anatomic location, especially when patients have spent time in endemic areas for HC.

Key words: Hydatid cyst; primary; soft tissue; children; echinococcus

Introduction

The term “hydatid” has Greek origins and means “watery vesicle.” Human echinococcosis was first described in ancient times by Hippocrates as “cysts full of water” in a human liver.^{1,2} There are six species of *Echinococcus* tapeworm, including *E. granulosus* (which causes cystic

echinococcosis), *E. multilocularis* (which causes alveolar echinococcosis), *E. vogeli* and *E. oligarthus* (which cause polycystic echinococcosis), *E. shiquicus*, and *E. felidis*. *E. granulosus* is the most common *Echinococcus* parasite to infect man.³ Dogs are the primary host of echinococcal infection, while intermediate hosts include sheep, cattle, and, occasionally, man. Hydatid cyst (HC) is most often found in rural areas.^{4,5} HC is endemic in Mediterranean countries, the Middle East, Far East, and south America.^{2,6} Primary HC (PHC) from soft tissue is very rare.

Despite several important advances in the control of HC, this disease remains a major health problem in some countries. The PHC located in extremely rarely is seen in soft tissues even in which echinococcal infestation is frequent. In this report were reported to four rare cases had PHC in soft tissue as an uncommon site and review the literature.

Material and Methods

The medical records of unusual presentation primary HC as subcutaneous were reviewed. In addition, the English language literature was reviewed. We retrospectively identified all cases of HC managed by the pediatric surgery department at Sanliurfa public hospital, Sanliurfa, Turkey, a funding hospital, Mombasa, Kenya, Harran University, Medical Faculty hospital, Sanliurfa, Turkey during the years 2004 to 2011 (Table 1).

Table 1: Demographics and clinical features in patients related literature

Cases	Age/ Gender	Rural enivorment	Symptom	Location of HC	Previous diagnosis	Diagnosed with
Cangiotti L, et al. ¹⁰		Yes	Mass	Lumbar	No	After Surgery
Nath K et al. ⁸	12/M	Yes	Mass	Neck	No	After Surgery
Marwah S et al. ¹²	8/M	Yes	Mass	the thigh	Yes	USG, serology
Duygulu F, et al. ¹³	8/F	Yes	Mass	The wall of thoraxThorax	Yes	MRI
Erol B, etal. ⁶			Mass	tissue of calf mass	Yes	MRI
Ok E et al. ³	12/f	unknown	Mass	neck	No	After Surgery
Cankorkmaz L et al. ⁷	4/M	No	Mass	lumbar	Yes	MRI
Gupta R et al. ²	12/F	Yes	Mass	Shoulder	No	Needle aspiration
Arslan S et al. ¹¹	5/M	No	Mass	Lumbar	Yes	USG
Our Case 1	7/F	Yes	Mass	Left axillar fossa	No	After Surgery
Our case 2	11/F	Yes	Mass	Right ant thorax wall	No	After Surgery
Our case 3	4/M	Yes	Mass	Popliteal Fossa	No	After Surgery
Our case 4	6/M	Yes	Mass	Left axillar Fossa	No	After Surgery

¹Department of Pediatric Surgery Harran University Faculty of Medicine, Sanliurfa, Turkey
E-mail: cevikmuazzez@gmail.com

Case 1: A 7-year-old girl presented with a two-month history of a gradually enlarging swelling in the left axillary fossa and lived in a rural area. On physical examination, an about 3 cm in diameter a swelling was palpated at the left axillary fossa. It was ovoid in shape, painless, and mobile. Superficial ultrasonography (US) showed a 4 x 3.5cm mass in the subcutaneous tissue. Diagnosis with US was lymphadenopathy, and revealed no pathology in the internal organs. All laboratory tests were normal. The patient received antibiotic therapy and follow up for 1 month. In this period, the patient showed no clinical improvement. Therefore, the patient underwent elective surgery for mass excision. Surgical excision of the mass under general

anesthesia and an elliptic incision was performed. And the mass was dissected with sharp dissection and perforated of capsule of mass and seen germinative membrane (Figure 1), and therefore a sponge soaked in povidone- iodine was placed around the cyst and cystic lesion was removed totally with capsule. The cavity was irrigated with povidone-iodine, and followed with saline. Histopathological examination of specimen revealed a HC. Albendazole 15 mg/kg was given for 3 months. Further investigations for other organ involvement were performed postoperatively to identify additional HC in different regions, and no other focus was found. No recurrence occurred for 12 month follow up.

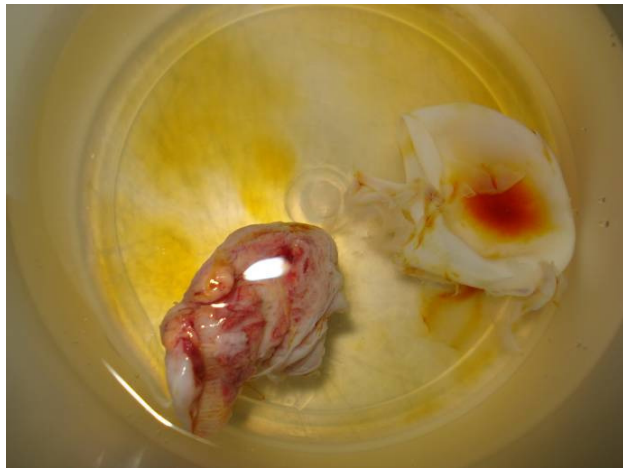


Figure 1: View of the Germinative Membrane.

Case 2: An 11-year-old girl was admitted with 3-month history of a gradually enlarging swelling in the right side of the chest wall and lived in a rural area. On physical examination, a mobile mass situated right anterior thoracic wall between the fifth and sixth rib (Figure 2), with no other findings. Laboratory findings were nonspecific. Superficial US showed a 2 x 3 cm cystic mass, which was reported as lipoma (Figure 2). The patient underwent elective surgery for mass excision. Surgical excision of the mass performed with elliptic incision under general anesthesia and the mass was dissected with sharp dissection. During operation

capsula of cystic mass was perforated and seen germinative membrane with cystic liquid. Therefore a sponge soaked in povidone- iodine was placed around the mass and cystic lesion was removed totally with capsule. The cavity was irrigated with povidone- iodine, and followed with saline. Histopathological examination confirmed the presence of hydatid cyst. Albendazole 15 mg/kg was given for 3 months. Further investigations were performed to identify additional HC in different regions, but none were found. No recurrence occurred for 12 month follow up.

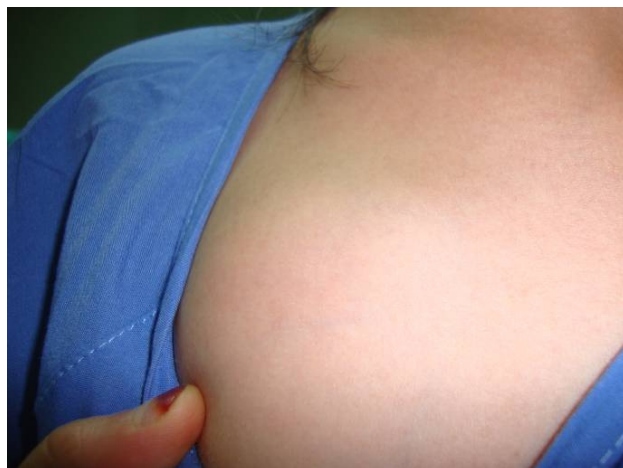

Figure 2: View of preoperative of the patient.

Case 3: A 4-year-old boy presented with a three-month history of a painless mass located in the right popliteal fossa. The patient had had undergone needle aspiration one month prior to admitted into our clinic, and the mass continued to swelling. On physical examination, there was a soft mass and about 1.5 cm mass in diameter, round shape, and localize in the popliteal fossa. The patient underwent elective surgery for mass excision. Surgical excision of the mass performed with elliptic incision with sedoanalgesia and local anesthesia and the mass was dissected with sharp dissection, the mass was originated from under subcutaneous tissue and peroperation was perforated capsule of mass and seen germinative membrane and the macroscopic appearance suggested a HC. Therefore a sponge soaked in povidone- iodine was placed around the cyst and cystic lesion was removed totally with capsule. The cavity was irrigated with povidone- iodine, and followed with saline. Histopathological examination confirmed the presence of hydatid cyst. Albendazole 15 mg/kg was given for 3 months. No recurrence occurred for 1 month follow up.

Case 4: A 6-year-old male presented with a six-month history of a slow-growing swelling in the left axillar fossa and lived in rural area. Upon physical examination, a round, soft mass was observed. Laboratory findings were nonspecific. Superficial US demonstrated a 6 x 4 cm cystic mass arising from the subcutaneous tissue and diagnosed to cystic hygroma by US. The patient underwent elective surgery for mass excision. Surgical excision of the mass performed with elliptic incision with general anesthesia and the mass was dissected with sharp dissection. At surgical exploration, the cyst was arised from subcutaneous tissue. Peroperatively, the mass was without perforated took from tissue and a sponge soaked in povidone- iodine was placed around the cyst to prevent enfestation and cystic lesion was removed totally with capsule. The cavity was irrigated with povidone- iodine, and followed with saline. Histopathological examination confirmed the presence of hydatid cyst (Figure 3). Albendazole 15 mg/kg was given for 3 months. Further investigations were performed to identify additional HC in different region, but none were found. No recurrence occurred for 12 month follow up.

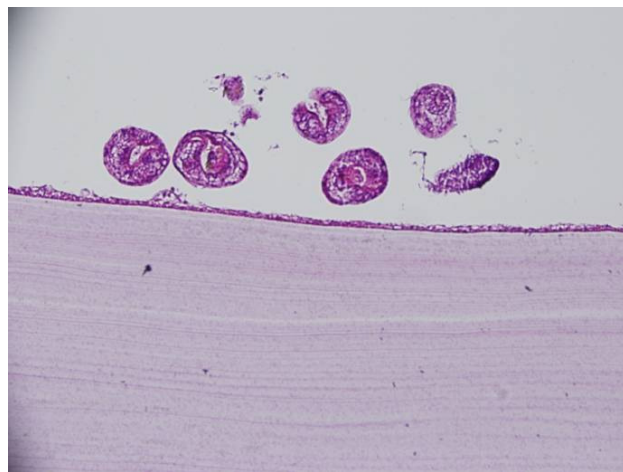


Figure 3: Histologic specimen of HC tissue; at the bottom, eosinophilic stained laminated and germinal membrane with many protoscolices in the lumen (stained H&E x 200).

Discussions

In Pubmed, there was not any case under searching keywords : "Primary Cyst Hydatid, Subcutaneous, Children" in english but there were 176 literature was about cutaneous, subcutaneous, muscle, with primary cyst hidatid that we assessed. This review yielded 9 reports of subcutaneous or smooth tissue with PHC in children. Most of them from neck, secondarily from lumbar, and then it may occur any part of body in muscle and diagnosed preoperatively by MRI.⁶ In our series most of HC was seen in axillar region and all of them no preoperative diagnosis as HC. And also all our cases were from subcutaneous tissue (Tablo 1).

HC is mostly diagnosed in adults.¹ Only a small percent of cases (10-20%) are diagnosed in patients younger than 16 years.^{1,3} However, HC often infected to people during childhood and slow-growing (1-5 cm/year). HC located subcutaneously may see easily even when they are a

small diameter. Therefore, the majority HC from soft tissue is diagnosed in children.^{2,4,7,8}

Primary cysts are most often located in major organs, such as liver, lung, whereas HC located in other tissues typically occur in addition to primary cysts and are called secondary HC. The mechanism of primary subcutaneous HC is unclear.⁷ The parasitic life cycle starts in the host after the accidental oral intake of *E. granulosus* eggs. Gastric and intestinal enzymes then help to release the oncosphere, which penetrates the duodenal wall and reach the liver via the portal vein.⁵ After they trapped in the sinusoid of the liver therefore, the liver mostly involved organ (70%). The larvae which pass through this first filter, reach the lung via directly enter the bloodstream via anastomoses between intestinal vessels and the caval system, therefore, the lung is secondary involved organ (10-15%). As well as, the larvae travel along the lymphatic system into systemic circulation or some larvae escape the hepatic-pulmonary filter and

cause HC in other end organs (5-15%).^{9,10} The incidence of subcutaneous HC is unknown; however, the incidence of soft tissue involving subcutaneous HC, is low and ranges from 1 to 5.4% of all HC cases.^{5,3} Most frequently of these cases are associated with involvement of other organs such as liver, lung. PHC of soft tissue without involvement of liver and lung is extremely rare. Therefore, we found a few case in the literature and illustrated Table 1.

HC cause several clinical symptoms due to size of the HC and involved organ. Patients with PHC of soft tissue have nonspecific symptoms, so their accurate diagnosis is challenging. The diagnosis of HC is made with anamnesis, physical examination, imaging techniques, serological tests (hemagglutination, complement fixation or enzyme linked immunosorbent assay, E.granulosus-specific IgE).^{11,12} In the present study, patients had no signs of HC in the liver, lungs, or other parts of body and were misdiagnosed before the operation. The definitive diagnosis of HC was made preoperatively, when the germinal membrane of the cysts was seen and revealed the histopathology.

The basic treatment of HC is combined medical and surgery treatment.^{11,13} Because of, removal of the primary cyst may not be totally effective, as smaller cysts can be left behind. Therefore, antihelminthic therapy is routinely prescribed to prevent recurrence. Recently, albendazol with

percutaneous treatments have become widely available.¹¹ Several reports have demonstrated that only mebendazole is a highly effective treatment, as it penetrates deeply into the cyst and is known to reduce the risk of recurrence.⁴ If we known preoperatively that our patients had HC, we would have treated them with albendazole, which would have avoided the need for surgery.

Easier, more effective, and more economic treatments are needed to prevent HC. Strategies, such as public education, strive to change risk behaviors and are succeeding in limiting and, in some cases, preventing the spread of the disease in humans.⁴ Control of HC also entails treating infected dogs with antihelminthics and controlling illegal slaughtering of potentially infected livestock. The feeding of livestock entrails to dogs is a common way that these tapeworms are spread and should be avoided.⁴

In conclusion, HC should be considered in the differential diagnosis of cystic masses in endemic areas. Preoperative diagnosis of HC enables treatment by chemotherapy and avoids the need for surgery. In addition to good hygiene, prophylaxis of hydatidosis is very important, particularly in children, as most cases of HC start in childhood.

References

1. Turgut AT, Altin L, Topçu S, Kiliçoğlu B, Aliinok T, Kaptanoğlu E, et al. Unusual imaging characteristics of complicated hydatid disease. *Eur J Rad.* 2007;63: 84-93.
2. Gupta R, Mathur SR, Agarwala S, Kaushal S, Srivastav A. Primary soft tissue hydatidosis: aspiration cytological diagnosis in two cases. *Diagn Cytopathol.* 2008;36(12):884-6.
3. Celik A, Turanli M, Kutun S, Delibasi T, Mengi N, Comert E, et al. Unusual location of hydatid cyst: soft tissue mass in the neck. *Eur Arch Otorhinolaryngol.* 2006;263(12):1147-50.
4. Shah OJ, Robbani I, Zargar SA, Yattoo GN, Shah P, Ali S, et al. Hydatid cyst of the pancreas. An experience with six cases. *J Pancreas.* 2010;11:575-81.
5. Ok E, Sözüer EM. Solitary subcutaneous hydatid cyst: a case report. *Am J Trop Med Hyg.* 2000;62(5):583-4.
6. Erol B, Tetik C, Altun E, Soysal A, Bakir M. Hydatid cyst presenting as a soft-tissue calf mass in a child. *Eur J Pediatr Surg.* 2007;17(1):55-8.
7. Cankorkmaz L, Ozturk H, Koyluoglu G, Atalar MH, Arslan MS. Intermuscular hydatid cyst in a 4-year-old child: a case report. *J Pediatr Surg.* 2007;42(11):1946-8.
8. Nath K, Prabhakar G, Nagar RC. Primary hydatid cyst of neck muscles. *Indian J Pediatr.* 2002 ;69(11):997-8.
9. Safioleas M, Nikiteas N, Stamatakos M, Safioleas C, Manti CH, Revenas C, et al. Echinococcal cyst of the subcutaneous tissue. A rare case report. *Parasitol Int.* 2008;57:236-8.
10. Cangiotti L, Muiesan P, Begni A, Cesare V, Pouchè A, Giulini SM, et al. Unusual localizations of hydatid disease: a 18 year experience. *1994;15(3):83-6.*
11. Arslan S, Turan C, Sezer S, Tuna IS. Primary lumbar hydatid cyst: a case report. *Turk J Pediatr.* 2010;52(5):556
12. Marwah S, Subramanian P, Marwah N, Rattan KN, Karwasra RK. Infected primary intramuscular echinococcosis of thigh. *Indian J Pediatr.* 2005 Sep;72(9):799-800.
13. Duygulu F, Karaoğlu S, Erdoğan N, Yildiz O. Primary hydatid cyst of the thigh: a case report of an unusual localization. *Turk J Pediatr.* 2006;48(3):256-9.

Correspondance to:

Muazez Cevik
 Department of Pediatric Surgery
 Harran University Faculty of Medicine
 TR-63000, Sanliurfa, Turkey
 Fax: +90 (414) 318 33 50
 E-mail: cevikmuazzez@gmail.com