

POLYORCHIDISM: A CASE REPORT AND REVIEW OF THE LITERATURE

I Skondras¹, C Velaoras¹, C Erikat¹, I Alexandrou¹, E Christianakis¹

Abstract

We report the case of a 21-month-old boy who was referred for the surgical management of a left undescended testis. A preoperative ultrasound examination was negative for supranumerary testis. Surgery revealed complete separation of the epididymis from the testis; one well-developed testis was found in the internal ring of the inguinal canal. A second atrophic testis was also detected in the inguinal canal and this was removed. Histological evaluation revealed the presence of an atrophic, undeveloped testis with its own epididymis and spermatic duct. The risk of malignancy in polyorchidism warrants the removal of an atrophic and ectopic testis.

Key words: Undescended testis, polyorchidism

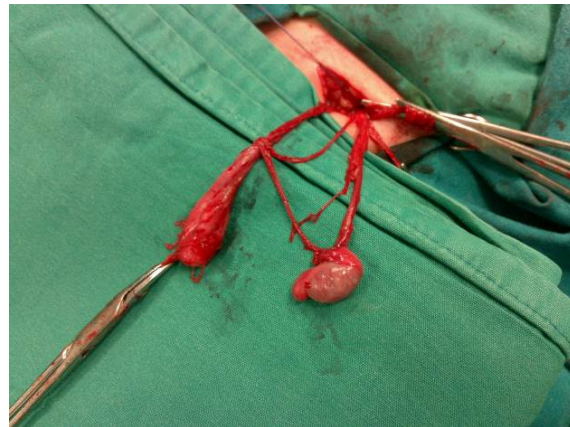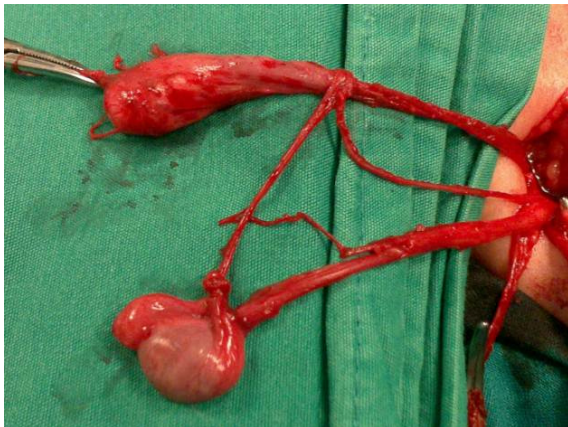Introduction

The presence of more than two testes confirmed by histopathology is known as polyorchidism. The first histologic reference to this condition was made in 1880 and the first confirmed case was described by Lane in 1895 [1]. The majority of cases involve triorchidism with occasional bilateral duplication [2]. Over 100 histologically confirmed cases have been reported in the literature, of which half had spermatogenic potential [3]. Despite advancements in imaging modalities and their widespread use, diagnosis is usually incidental as polyorchidism is generally identified during surgery. It is not uncommon for the condition to be associated with other anomalies including cryptorchidism

(40%), inguinal hernia (30%), testicular torsion (15%), hydrocele (9%) and neoplasia (6%) [4]. Fifty per cent of cases are diagnosed between the age of 15 and 25 years [1].

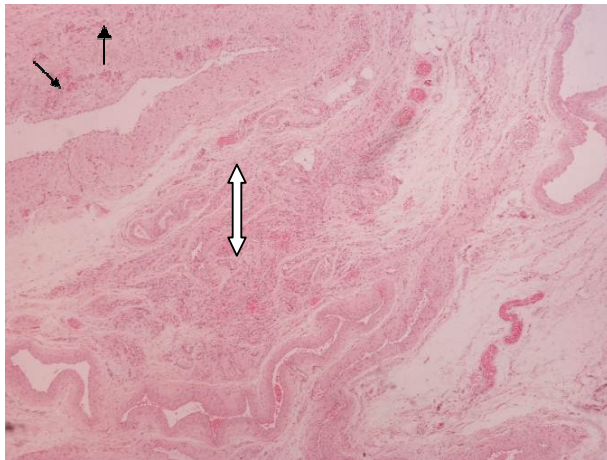
Case presentation

A 21-month-old boy was admitted to our department for surgical management of left cryptorchidism. He had undergone surgery 3 months earlier for right orchidopexy due to congenital cryptorchidism. On clinical examination the right testis was found within the hemiscrotum while the left was palpable in the upper third of the inguinal tract, which concurred with the finding of the preoperative ultrasound examination. At surgery, an incision was made to the inguinal canal. Surgical preparation of the spermatic cord elements uncovered the presence of a small atrophic testis with vestigial epididymis and normal spermatic duct. Despite the evident testicular hypoplasia, the preoperative findings prompted us to explore the internal inguinal ring for a palpable mass. Downward traction of the spermatic cord elements and the pressure exerted along the inguinal canal revealed another testicle of standard size with normal epididymis and duct which apparently was a third testis (pics. 1,2); fortunately, after surgical dissection and mobilization to the ipsilateral hemiscrotum it had achieved fixation, following excision of the atrophic testis. Histologic examination confirmed the presence of an undeveloped testis with its own epididymis, spermatic cord and duct but without testicular cannulas (pics. 3,4)

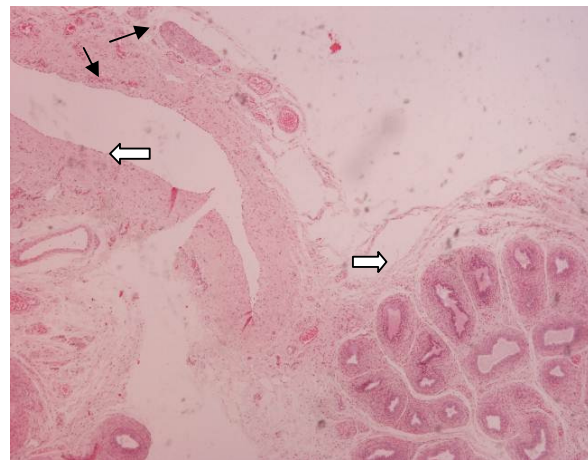

Pictures 1, 2. Surgical specimen.

¹Paediatric Surgical Department, Penteli Children's Hospital
E-mail: skondras@yahoo.gr, kvelaoras@yahoo.gr,erikatkhil@yahoo.gr,
Inalexantrou@hotmail.com, xristianakis@yahoo.gr



Picture 3: Surgical specimen of cryptorchidism. Undeveloped testis in the place of which a dense capillary network can be seen in a substroma of connective tissue (double arrow).Visceral tunica vaginalis lined by mesothelial cells (thin arrows H-E x400).



Picture 4: Surgical specimen of cryptorchidism. Epididymis (right arrow), vascular connective tissue (undeveloped testis) (left arrow) and thin stroma of mesothelial cells that line visceral tunica vaginalis. (thin arrows H-E x400).

Discussion

With only 100 cases reported in the literature, polyorchidism constitutes a rare condition that is thought to stem from the abnormal division of the genital ridge during fetal development [5]. Generally an incidental finding at surgery, its most common form is thriorchidism, although there are some reported cases of as many as five or even six testes [6] About 75% of supranumerary testes are intrascrotal and patients normally present with an unusual scrotal mass. Another 20% are found within the inguinal canal while 5% are located in the retroperitoneal space [7]. Testicular duplication must be differentiated from transverse testicular ectopia where both healthy testes migrate from the inguinal canal to the same hemiscrotum [8]. Polyorchidism is often associated with other anomalies including cryptorchidism (40%), inguinal hernia (30%), testicular torsion (15%), hydrocele (9%) and neoplasia (6%) [4] without any evidence to date of chromosomal abnormality [9]. A 66% prevalence is noted for left-sided lesions and 20% for the right while 14% are bilateral [1].

Thirty-seven per cent of numerary testes display tubular atrophy and lack of spermatogenic potential [1,10]. According to the literature, malignancy has been reported in 4-7% of cases [11]. However, it is difficult to establish its precise incidence given the rarity of the condition and frequent coexistence of congenital cryptorchidism [12]. Theories surrounding the embryologic origin of polyorchidism include the degeneration of mesonephric components and duplication or division of the genital ridge [13-16]. The most plausible explanation is the transverse division of the urogenital ridge at 4th to 6th week of pregnancy. The theory related to degeneration of mesonephric components has been rejected on the basis that this does not appear to influence the genital ridge nor the developing testicle [14,16,17]. Duplication can only account

for some of the anatomic variations whereas division can justify all anatomic diversities.

In 1988, Leung maintained that transverse division or duplication of the genital ridge and tubules by peritoneal bands could explain all forms of polyorchidism and went on to describe anatomic variations on the basis of embryological development. More specifically, type I supranumerary testis lacks an epididymis, spermatic duct or contact with the healthy testis, type II shares a common epididymis and spermatic duct with the healthy testis, type III has its own epididymis and shares the spermatic duct of the ipsilateral healthy testis whereas type IV represents the complete duplication of testes, epididymis and spermatic duct. The most common presentation is that of type II; types II and III together account for 90% of cases of polyorchidism [5].

The management of polyorchidism remains a subject of controversy, particularly when the supranumerary testis is viable, asymptomatic and only identified incidentally. Formerly, the traditional approach was the surgical excision of the smaller in size testicle [18]. However, Bhogal et al, favour conservative management that entails regular follow-up with magnetic resonance imaging, a non-invasive and sensitive method, providing that the condition is not accompanied by other disorders and does not pose a risk for malignancy [11,14].

Nonetheless, it should be noted that surgical management enables testis fixation and formation of a single testicular mass, thereby protecting it from possible torsion and facilitating biopsy if needed. Furthermore, it enables us to confirm the presence of an outflow tract and the potential for spermatogenesis [10,17]. Malignancy, dysplastic changes or absence of spermatogenic potential, as shown by biopsy, are absolute indications for excision [3].

Some authors advocate excision on the grounds that the majority of cases involve supranumerary testes with reduced or total lack of spermatogenic potential and display an increased incidence of neoplastic disease. Their surgical removal is particularly recommended if the testis is not viable or is associated with cryptorchidism or testicular ectopia, all of which increase the risk for malignancy [19,20].

Others favour the preservation of supranumerary testes as two thirds of cases do not present any histological changes or increased risk for malignancy [1]. Excision of the ectopic supranumerary testis in our patient was decided by virtue of its atrophic nature combined with the malignant risk associated with every undescended or dysplastic testis.

Conclusion

All patients displaying cryptorchidism should be examined for the likely presence of a second ipsilateral testicle. Should the supranumerary testis be healthy, fixation is recommended to prevent torsion and to preserve spermatogenesis. Surgical removal is indicated in cases of atrophy or dysplasia. When in doubt, a biopsy is recommended. Depending on his age, the personal view of the patient, in terms of his psychological and cosmetic needs, should also be taken into consideration before reaching a decision.

References

1. Spranger R, Gunst M, Kuhn M. Polyorchidism; a strange anomaly with unsuspected properties. *J Urol* 2002; 168:198
2. Wolly B, Youndson GG. Polyorchidism. *Pediatr Surg Int* 1998; 13:65-66
3. Kharrazi SM, Rahmani MR, Sakipour M, Khoob S. Polyorchidism: a case report and review of the literature. *Urology* 2006;3:180-183.
4. Yenyol CO, Nergiz N, Tuna A. Abdominal polyorchidism: a case report and review of the literature. *Int Urol Nephrol* 2004; 36:407-408
5. Leung AK. Polyorchidism. *Am Fam Physician* 1988; 38:153-166
6. Paolo Repetto , Pierluca Ceccarelli, Anastasia Bianchini, et al. Three small testes in left hemiscrotum: a rarer case of polyorchidism. *Journal of Pediatric Surgery* (2010) 45, E21–E23
7. Bostwick DG. Spermatic cord and testicular adnexa. In: *Urologic Surgical Pathology*. Bostwick DG, Eble JN(eds). Mosby, Pt Louis 1997;140:582-583
8. Leung AK, Wong AL, Kao CP. Duplication of the testis with contralateral anarchism. *South Med J* 2003;96:809-810
9. Nacey JN, Urquhan Hay D. Polyorchidism. *Br J Urol* 1987;59:280
10. Ozok G, Taneli C, Yazici M, Herek O, Gokdemir A. Polyorchidism: a case report and review of the literature. *Eur J Pediatr Surg* 1992;2:306-307
11. Bhogal RH, Palit A, Prasad KK. Conservative management of polyorchidism in a young man: a case report and review of the literature. *Pediatr Surg Int* 2007;23:689-691
12. Umeda H, Yoshimura Y, Ishibashi K, Yamaguchi O. A case report of polyorchidism with embryonal carcinoma. *Nippon Hinyokika Gakkai Zasshi* 1998;89:441-444
13. Thum G. Polyorchidism: case report and review of literature. *J Urol*. 1991;145: 370–2.
14. Singer BR, Donaldson JG, Jackson DS. Polyorchidism: functional classification and management strategy. *Urology* 1992;39: 384–8.
15. Nocks BN. Polyorchidism normal spermatogenesis and equal sized testes: a theory of embryological development. *J Urol*.1978; 120: 638-40.
16. Wilson WA, Littler J. Polyorchidism: a report of two cases with torsion. *Br.J.Surg.*1952;41: 302–7.
17. O’Sullivan DC, Biyani CS, Heal MR. Polyorchidism: causation and management. *Postgrad. Med. J.* 1995; 71: 317–18.
18. Kale N, Basaklar AC. Polyorchidism. *J. Pediatr. Surg.* 1991;26:1432–4.
19. Scott KWM. A case of polyorchidism with testicular teratoma. *J. Urol.* 1980;124: 930.
20. Abbasoglu L, Salman FT, Gun F, Ascioglu C. Polyorchidism presenting with undescended testes. *Eur J Pediatr Surg* 2004;14:355–357

Correspondance to:

Ioannis K Skondras
 Ivis 11, Chalandri,
 Athens
 15234
 Tel/Fax: 210-6825625, 6932572226, 2106834338
 E-mail: skondras@yahoo.gr