

LEFT-SIDED PNEUMONECTOMY IN ONE-YEAR OLD CHILD A RESULT OF COMPLICATED PLEUROPNEUMONIA

A Uchikov¹, P Stefanova², B Ivanov²

Abstract

Pleuropneumonia in children with heavy complications often requires surgical treatment. In the accessible literature a couple of cases with pneumonectomy in children of different ages are described. Procedure is not often done because of intervention difficulty and the high risk of intra and postoperative complications. A clinical case of one-year old child with left-sided pneumonectomy because of chronic pleuropneumonia is presented. Taking the decision for removal of a pair organ is difficult and responsible, but in the presented case it solves a number of complications and improves the quality of patient's life.

Key words: pleuropneumonia, pneumonectomy, child

Introduction

The inflammatory lung process in children has a tendency to quickly progressing destructive pleural and parenchymal complications.(1) Pleuropneumonia in children with life threatening condition is usually supported with parenchymal damage of lung as: necrotizing pneumonia, pulmonary abscess, fungal infection or gangrene of lung (1,2) Surgical treatment includes thoracocentesis, thoracotomy with decortication, atypical resections, segmentectomies or when the whole lobe is affected - lobectomy and in non-working lung pulmonectomy is required.(2)

Pneumonectomy in early pediatric age in case of inflammatory lung diseases is considered a procedure of high risk because of the complex operative technique and postoperative complications.(5) In a couple of publications the authors consider that the procedure should be avoided when is possible. (6) Despite that, there are situations when pneumonectomy and pleuropneumonectomy continue to be the only way of treatment in inflammatory destructive lungs diseases. (1,6)

Children, who underwent pneumonectomy have less functional disturbances compared with adults. (7)

Clinical case:

A one year old boy was admitted in the Department of Pediatric surgery of UMHAT St. George with diagnosis: complicated left-sided pleuropneumonia with difficult respiratory insufficiency. On the chest X-rays is total left-sided pneumothorax – fig. 1

Thoracocentesis was done in the 6th intercostal space and 100 ml. purulent exudate was evacuated, and the Bulau chest drainage was put fig.2 The condition of the boy remained serious and second thoracocentesis is done - fig.3

Condition of child remained still serious. A CT /computer tomography/ of lung is done - Fig.4

The child stayed in serious condition. Clinical process of disease and data from computer-tomography check-up imposed taking a decision for thoracotomy. With lateral thoracotomy in 6th intercostal space the chest cavity is opened. The thick coalesced visceral to parietal pleura was separated as well as from the diaphragm and pericardium. The pulmonary tissue is atelectatic in the phase of hepatization. The attempt for unfolding the lung is without result. The decision of left pneumonectomy is taken. A thoracic drainage was put in the 7th intercostal space. Histopathology – atelectatic pulmonary parenchyma with hyperemia and subpleural haemorrhages and interstitial fibrosis. After intensive care and antibiotic therapy the condition of child significantly improves and he gradually recovered and was discharged from the hospital.

After 4 mounts, a radiology control and physical examination is done –fig.5 and fig.6

Argument

The destructive diseases of lung supported by necrosis of pulmonary parenchyma are the final stage of deteriorated passing pneumonia leading to serious complications and inconvertible changes in parenchyma which are seldom met in children.(1) The inflammatory lung diseases such as bronchiectasis, tuberculosis, necrotizing pneumonia, pulmonary abscesses, fungus infections, pulmonary gangrene, bronchial structure and congenital malformations , the affected lung doesn't have proper function, with visible lack of perfusion and ventilation (1, 2) In the literature data bronchiectasis remain the most frequent reason for chronic suppurative destructive diseases in children's lungs, followed by tuberculosis. (1,3,4,5,13) In our case the presented child hasn't prior congenital or gained lung pathology and the destructive processe develop on the base of complicated pleuropneumonia, uninfluenced by applied standard conservative and operative therapy.

¹ Department of Thoracic Sugery, Uviversity Hospital "St. George" – Plovdiv, Bulgaria

² Department of Pediatric Surgery, Uviversity Hospital "St. George" – Plovdiv, Bulgaria

E-mail: pepi_stef@hotmail.com, bisi_sam@abv.bg

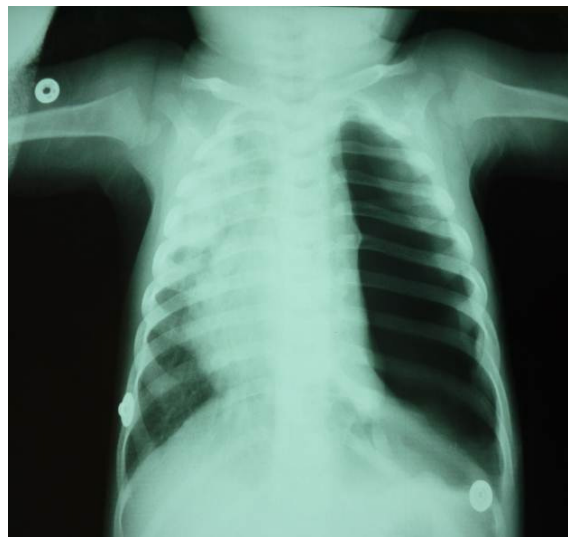

Fig.1 Total left-sided pneumothorax

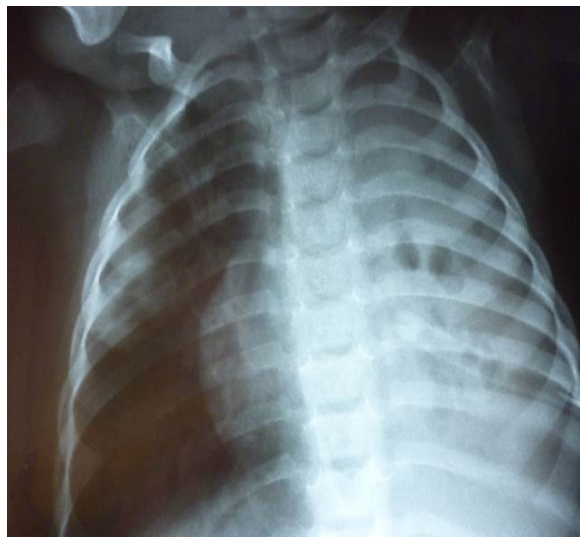

Fig.2. Left lung half is almost completely dimmed. Presence of inflammatory changes in the pulmonary parenchyma with taking on the pleural cavity

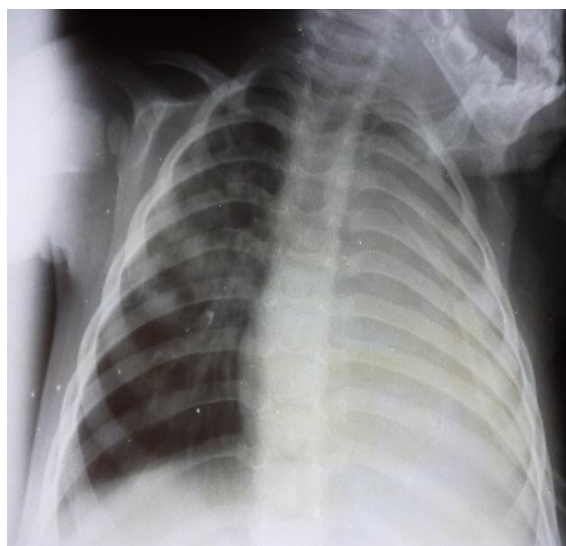


Fig.3 Extra-alveolar air collections were not estimated in the left side. The same chest half is homogeneously shaded. Combination of pleural effusion and atelectasis

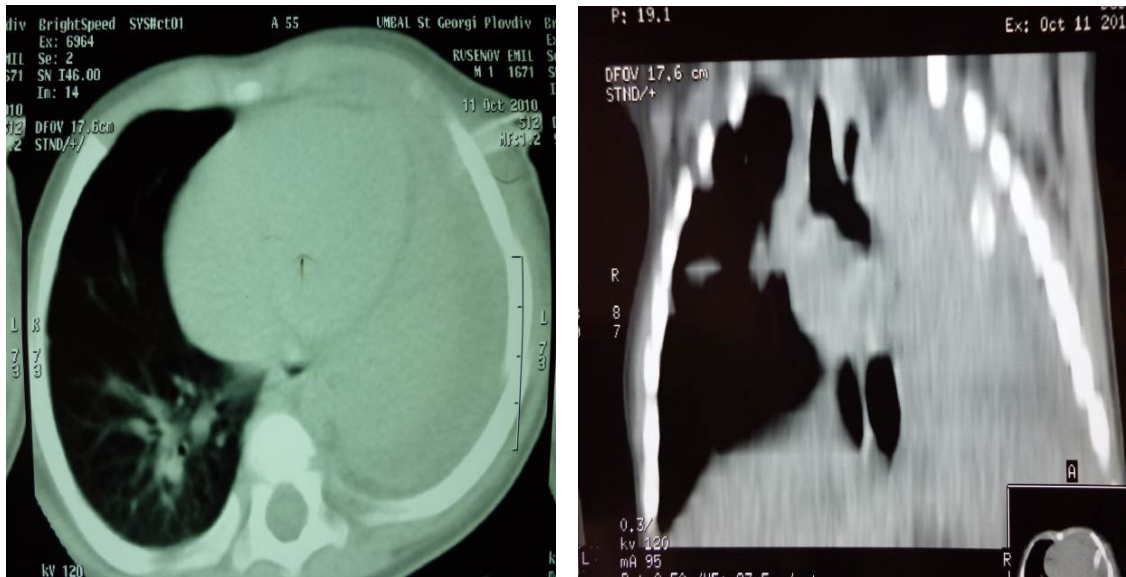


Fig.4 The whole left lung is with disturbed aeration and is presented with homogeneous structure with density about 45 HE and missing air bronchogram –finding corresponds to atelectasis. Small effusion basally.

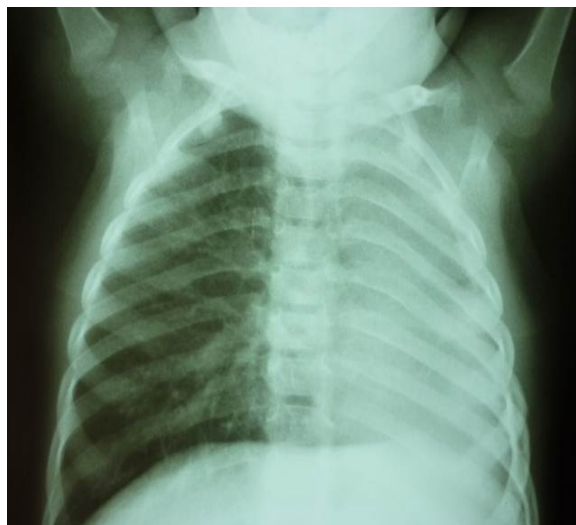

Fig.5 4 mounts, a radiology control

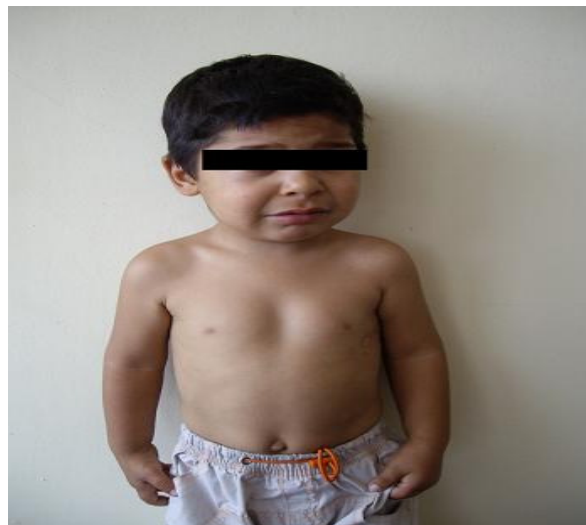

Fig.6 After 4 mounts physical examination

Nissen in year 1931 in Europe and Haight in year 1932 in North America did the first successful pneumonectomies with children (3) In 1956 F. J. Sambrook Gower, reports for pneumonectomy with new born on the occasion of congenital cystic malformation of

right lung.(10) In the accessible literature publications about pneumonectomy are very rare, especially in children under one year.(1, 9, 12). According to authors, pneumonectomy as a choice of treatment is one of the quickest and effective means preventing organism from coming serious

complications as: massive spitting blood, secondary fungus infections, secondary amyloidosis, pussy infections, septicemia, pulmonary hypertonia and chronicle respiratory insufficiency. (1, 8)

Pneumonectomy in children because of inflammatory lung diseases is a high risk procedure connected with intra and postoperative complications.(1, 2, 3, 8, 9, 11, 12) This operative intervention in children is much more complicated, compared with adults.(1, 3, 4, 8, 9, 11, 12) The difficulty in the presented case is mainly due to the patient's age, the small chest, the tightly covered lung and the applied endotracheal anesthesia.

After total pneumonectomy, the often met complications are post-pneumonectomy empyema, bronchial, bronchial-pleural fistula and post-pneumonectomy syndrome.(1, 3, 11, 12) In some of the cases after removal of one lung the remaining one is predisposed to edema and 100% mortality is registered (1,11,13)

In our case such complications are not observed. Preoperative application of the antibiotic therapy, anti-tuberculosis patent medicines with proven case of tuberculosis and multiple lavage of the chest cavity after pneumonectomy contribute to decrease the percentage of sick and death rate in children (1,8,9), algorithm to which we keep also.

Despite the high risk which pneumonectomy hides with the vast destructions of lung is not expected to be avoided as a method of treatment when all the other means are spent. (1, 8, 9, 12) A couple of authors share that children who went through pneumonectomy as an operative intervention have good physical growth. (7, 8, 10, 11, 12) Children who underwent similar operations grow and develop normally and according to the Stiles and co. have bigger potential of growth, they tolerate better dully pulmonectomy as a result of which have lesser functional disturbances compared with adults (7), as we estimated during control check-ups in our case does not show diversion from the norm.

References

1. Altug Kosar, MD, Alpay Orki, MD, Hakan Kiral, MD, Recep Demirhan, MD; Pneumonectomy in Children for Destroyed Lung: Evaluation of 18 Cases. *Ann Thoracic Surg.* 2010;89:226-231
2. Westphal FL, Lima LC, Lima Netto JC, Tavares E, Andrade EO, Silva MS; Surgical treatment of children with necrotizing pneumonia. *J Bras Pneumol.* 2010;36(6):716-723
3. D.F. Blytha, N.J. Buckelsa, R. Sewsunkera; Pneumonectomy in children. *Soni European Journal of Cardio-thoracic Surgery.*22(2002).587-594
4. Conlan AA, Moyes DG, Schutz J, Scoccianti M, Abramor E, Levy H; Pulmonary resection in the prone position for suppurative lung disease in children. *J Thorac Cardiovasc. Surg.*1986;92:890-893
5. Fisher WW, del Missier PA; The surgical treatment of tuberculosis in children. *J Thorac. Cardiovasc. Surg.*1959;38:501-22
6. Le Roux BT. Respiratory infection which requires surgical management. *S .Afr. Med. J.*1973;47:419-26
7. Stiles QR, Meyer BW, Lindesmith GG, Jones JC. The effects of pneumonectomy in children. *J. Thorac Cardiovasc. Surg.*1969;58:394-400

8. S, evval Eren MD , Mehmet Nesimi Eren MD, Akin Eraslan Balci MD. Pneumonectomy in children for destroyed lung and the long-term consequences. *The Journal of Thoracic and Cardiovascular Surgery.* August 2003. Volume 126, Number 2 575
9. David Featherstone Blyth. Pneumonectomy for inflammatory lung disease. *Eur. J. Cardiothorac. Surg.*2000;18:429-434
10. N. S. Clark, R. C. Nairn, F. J. Sambrook Gowarcystic. Disease of the lung in the newborn treated by pneumonectomy. *Arch. Dis. Child.*1956 October;31(159):358-363
11. Christopher Soll, Dieter Hahnloser, Thomas Frauenfelder, Erich W. Russi, Walter Weder, Peter B. Kesetenholz. The postpneumonectomy syndrome: clinical presentation and treatment. *Europen Journal of Cardio-thoracic Surgery* 35;(2009):319-324
12. Carolyn E. Reed. Pneumonectomy for chronic infection: Fraught with danger. *Ann. Thorac. Surg.*1995;59:408-411
13. Gowri Shankar, Paras Kothari, Dinesh Sarda, Bharati Kulkarni, Alka Kalgutkar. Pneumonectomy in a child with congenital bronchiectasis: A case report and review of literature. *Annals of Thoracic Medicine-Vol 1, Issue 2, December 2006:*81-83

Correspondence to:

Biser Ivanov
 Medical University - Plovdiv
 University Hospital "St. George"
 bul. Peshtersko shosse, 66, fl. 10
 tel + 359 32 602 977
 fax: +359 32 240 737
 E-mail: bisi_sam@abv.bg