

## PROPRANOLOL TREATMENT OF INFANTILE HEMANGIOMA: OUR PRELIMINARY RESULTS

Corina Stănculescu<sup>1,2\*</sup>, CM Popoiu<sup>1,2</sup>, Anca Popoiu<sup>1,2</sup>, Șt. Lazea<sup>1,2</sup>, A. Lăcătușu<sup>1,3</sup>, Patricia Cristodor<sup>1,4</sup>, VL David<sup>1,2</sup>, Emanuela Verenca<sup>1</sup>, ES Boia<sup>1,2</sup>

### Abstract

Infantile hemangiomas (IH) are the most common benign vascular tumors in childhood, affecting 4-5 % of Caucasian infants in their first year of life.

We performed a prospective study of 34 cases of IH treated with propranolol from May 2010 to December 2012. Beta blocker treatment was administered in 21 girls and 13 boys aged 2 to 14 months (mean age 5.4 months). All patients were evaluated with electrocardiography and echocardiography prior to start of treatment. Propranolol was administrated at a dose of 1mg/kg/day divided in 3 equal parts (day 1) and 2mg/kg/day divided in 3 equal parts (day 2), continuing with this dose throughout the rest of the treatment. The treatment was initiated during a 24- 48 hours hospitalization, time during which blood pressure and heart rate were measured every 6 hours. After 24 hours of hospitalization we performed an EKG and measured the blood glucose level. None of our patients developed hypotension, hypoglycemia or bronchospasm.

The results are: very good-70.96%, good-16.12%, partial-6.45%, no response- 6.45%. Three patients were uncooperative and after 1 month to treatment they have not presented to control and stop the treatment.

**Keywords:** infantile hemangioma, propranolol, treatment, beta blocker

### Introduction

What is hemangioma? What is infantile hemangioma? What is congenital hemangioma? The terminology used for vascular lesions has been very confusing until 1982, when Mulliken and Glowacki classified the common cutaneous vascular lesions of childhood into two categories, based on endothelial cell characteristics: hemangiomas and vascular malformations [1,2,3,4].

In 1996, the International Society for the Study of Vascular Anomalies (ISSVA) accepted the classification of vascular anomalies into vascular tumors and vascular malformations, based on clinical, radiological and pathological characteristics [5,6]. Hemangiomas represented the most vascular tumor of infancy and can be divided into

two categories: infantile hemangiomas and congenital hemangiomas. IH is the most common benign vascular tumor of infancy, occurring in an estimated 4–5% of Caucasian infants [7,8].

The typical IH is not present at birth, appearing a few days postnatally, it rapidly grows during the first year and regresses slowly by the age of 7 years. One third of IH may be apparent as a stain at birth. They are more common in females (3:1) and premature babies with birth weight of less than 1500 grams. The lesions may be classified by clinical type into superficial, deep and mixed [9]. Medical history should focus on determining whether or not the lesion is present at birth, its growth rate (proportional versus disproportional), and if episodic enlargement occurred at any point [10].

The diagnosis of IH is based on medical history and physical examination. Imaging techniques are sometimes used to evaluate the extent of the lesion, differential diagnosis and follow-up of response to treatment [4].

Two approaches can be adopted in the management of infantile hemangiomas: the expectant “wait and see” attitude or the therapeutic (either medical or surgical) attitude. The methods of treatment include: systemic corticosteroid therapy, intralesional corticosteroids, interferon  $\alpha$ , Vincristine, laser therapy, cryotherapy, surgical excision [10].

By a chance, Leaute-Labreze C et al. [11] discovered the propranolol's effects for infantile hemangioma. They treated for hypertrophic cardiomyopathy an infant with a nasal infantile hemangioma with enlarging lesion despite corticoid treatment and observed propranolol's inhibitory effect on hemangioma proliferation.

Synthesized by James W. Black [12] in the early 1960s, propranolol has been used extensively in children and neonates in pediatric cardiology. The indications for propranolol use have now exceeded the spectrum of cardiology, as the drug has been proven useful in pathologies like migraines, infantile hemangiomas, portal hypertension, post-traumatic stress and cancer [11,13,14,15].

<sup>1</sup>University of Medicine and Pharmacy “Victor Babeș” Timișoara, România, \*PhD Student

<sup>2</sup>Emergency Children's Hospital “Louis Țurcanu” Timișoara, România

<sup>3</sup>Department of Pediatrics No. 2, Timișoara, România

<sup>4</sup>Dermatology Clinic of Timișoara, România

E-mail: stanciulescucorina@yahoo.com, mcpopoiu@yahoo.com, apopoiu2004@yahoo.com, stefanlazea@yahoo.com, adilacatusu@yahoo.com, patricia.cristodor@gmail.com, david.vlad@yahoo.com, emma\_ver@yahoo.com, boiaegen@yahoo.com

No	Gender	Localization	Type of IH	Age at onset	Age at end	Duration	Response
1.	F	Periorbital	Deep	9 mo	15 mo	6 mo	Very good
		Capillary malformation of major labia	-				No response
2.	M	Periorbital	Deep	5 mo	13 mo	8 mo	Very good
3.	M	Face (cheek)	Deep	14 mo	20 mo	6 mo	Very good
4.	M	Scalp (occipital) and lower lip	Mixed	5 mo	13 mo	8 mo	Very good
5.	F	Forearm and scalp	Superficial	6 mo	16 mo	10 mo	Very good
6.	M	Periorbital	Deep	6 mo	14 mo	8 mo	Very good
7.	F	Cervical area and forearm	Superficial	6 mo	-	Ongoing	Good
8.	M	Right calf	Superficial	7 mo	15 mo	8 mo	Very good
9.	F	Face (chin)	Superficial	5 mo	6 mo	1 mo Retract	Uncooperative patient
10.	F	Forehead	Superficial	5 mo	8 mo	3 mo Retract	No response Surgical excision
11.	F	Forearm and abdominal wall	Superficial	3 mo	12 mo	9 mo	Very good
12.	M	Fingers	Superficial	5 mo	11 mo	6 mo	Very good
13.	F	Left hand	Superficial	5 mo	-	Ongoing	Very good
14.	F	Right breast	Mixed	2 mo	-	Ongoing	Good
15.	F	Left breast and scalp	Superficial	6 mo	-	Ongoing	Good
16.	M	Ear lobe	Superficial	2 mo	8 mo	6 mo	Very good
17.	F	Labia major	Superficial	7 mo	8 mo	1 mo Retract	No response Uncooperative patient
18.	F	Face	Superficial	5 mo	6 mo	1 mo Retract	No response Uncooperative patient
19.	F	Upper eyelid, thorax, fingers	Superficial	2 mo	-	Ongoing	Good
20.	F	Upper eyelid	Superficial	4 mo	12 mo	8 mo	Very good
21.	F	Abdominal wall	Superficial	8 mo	16 mo	8 mo	Very good
22.	M	Shoulder	Superficial	8 mo	9 mo	1 mo Retract	No response Surgical excision
23.	M	Abdominal wall	Superficial	2 mo	8 mo	6 mo	Very good
24.	F	Face	Mixed	5 mo	-	Ongoing	Very good
25.	F	Scalp and right calf	Superficial	4 mo	-	Ongoing	Very good
26.	M	Scalp and thorax	Superficial	8 mo	-	Ongoing	Very good
27.	M	Lower lip	Mixed	14 mo	-	Ongoing	Very good
28.	F	Lower eyelid	Superficial	3 mo	9 mo	6 mo	Very good
29.	F	Left calf	Superficial	6 mo	12 mo	6 mo	Very good
30.	F	Thorax	Mixed	2 mo	14 mo	12 mo	Partial
31.	M	Forehead	Superficial	5 mo	-	Ongoing	Partial
32.	F	Right ankle	Superficial	2 mo	-	Ongoing	Very good
33.	M	Scalp	Superficial	2 mo	-	Ongoing	Very good
34.	F	Face and cervical	Mixed	6 mo	-	Ongoing	Good

Table 2. Characteristics of the patients

**Materials and methods**

We present our preliminary data from 34 children with 44 infantile hemangioma treated with oral propranolol, during the May 2010 to December 2012 timeframe. (Table1.)

Informed consent from the parents/guardians of each patient was obtained in all cases. Clinical pictures have been taken before the start of treatment and at each subsequent

visit. Inclusion criteria were infants newly diagnosed with IH who had not been previously treated with local or systemic corticosteroids.

Beta blocker treatment was administered to 21 girls and 13 boys aged between 2 months and 14 months (mean age 5.4 months). Treatment was discontinued if the lesion completely disappeared, if parents decided to cease the

medication or if after 1 or 3 month of treatment there was no improvement, and the family was offered surgical treatment.

Prior to administration of the drug, all patients were clinically evaluated by a pediatric cardiologist, then underwent electrocardiography (EKG) and echocardiography.

We have used the Prof. Dr. Cremer therapeutic scheme: propranolol was administrated at a dose of 1mg/kg/day divided in 3 equal parts (day1) and 2mg/kg/day divided in 3 equal parts (day 2), continuing with this dose throughout the rest of the treatment[16,17].We have initiated the treatment during a hospitalization of 24- 48 hours. The blood pressure, blood glucose and the heart rate were

carefully monitored every 6 hours. After 24 hours we have remeasured child blood glucose and registered the EKG profile. In all cases, the drug was well tolerated and the treatment was continued at home. Monthly, we have evaluated the clinical and photographic evolution of the hemangioma, and we monitored the heart rate, blood pressure, blood glucose and performed an EKG. A repeat echocardiogram was performed after 2 months of treatment.

During the period of observation, the family was instructed to report any evidence of evolution, and none reported or received other therapies for other medical problems.

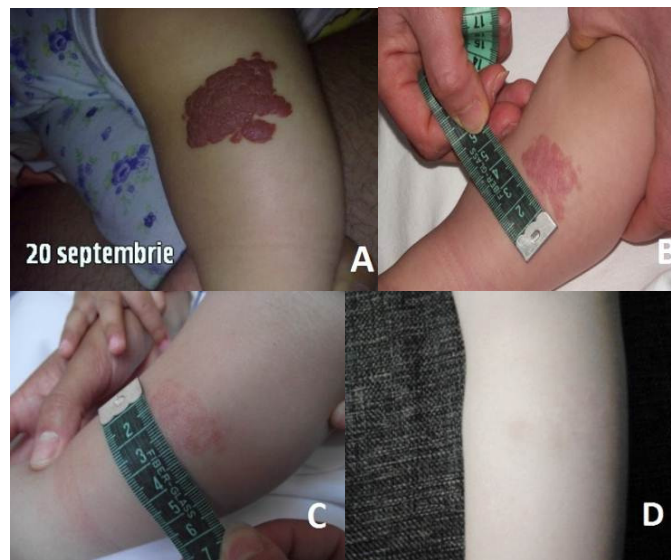


Fig. 1. Case 1: A. Before treatment; B. After 5 months; C. After 8 months; D. After 9 months from treatment cessation.

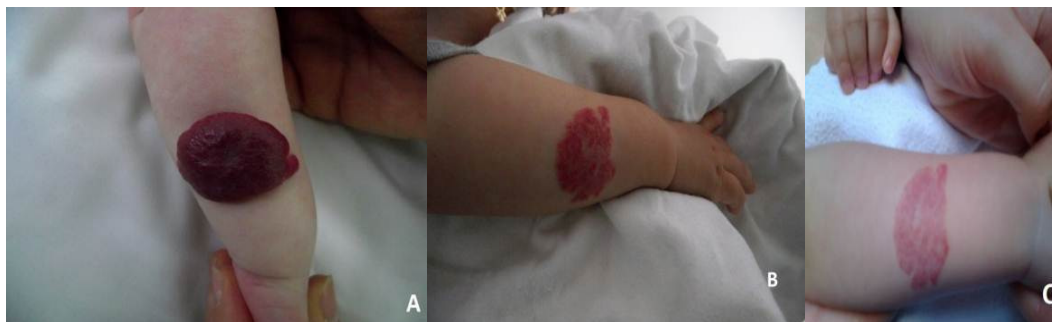

Fig. 2. Case 2: A. Before treatment with Propranolol; B. After 9 months; C. After 12 months.

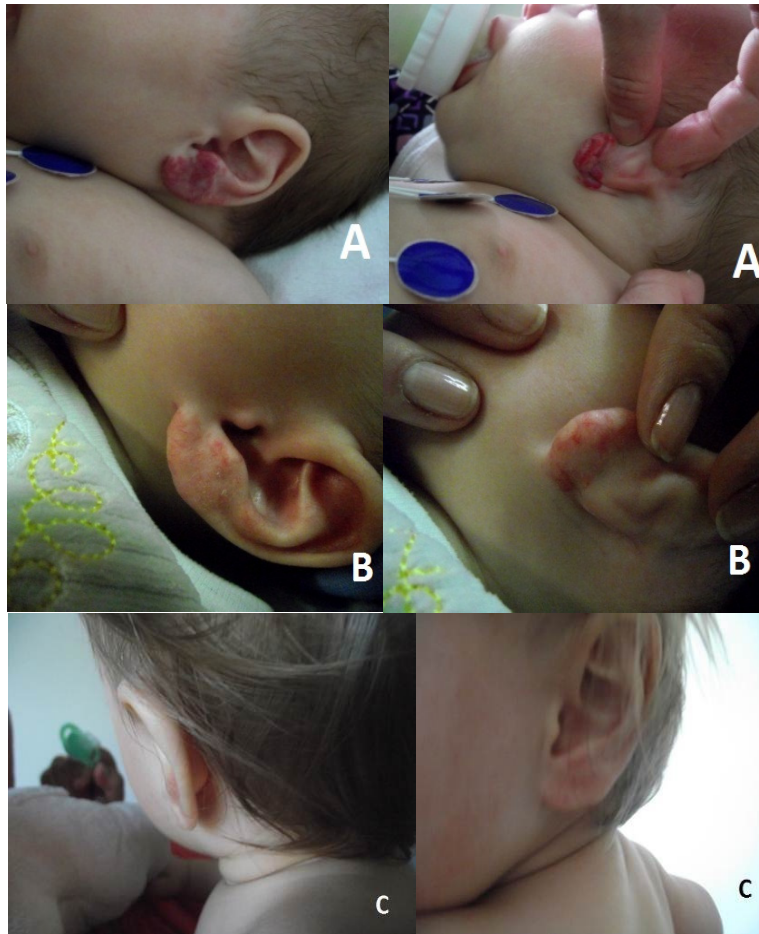


Fig. 3. Case 3: A. Before treatment; B. After 3 months; C. After 6 months.

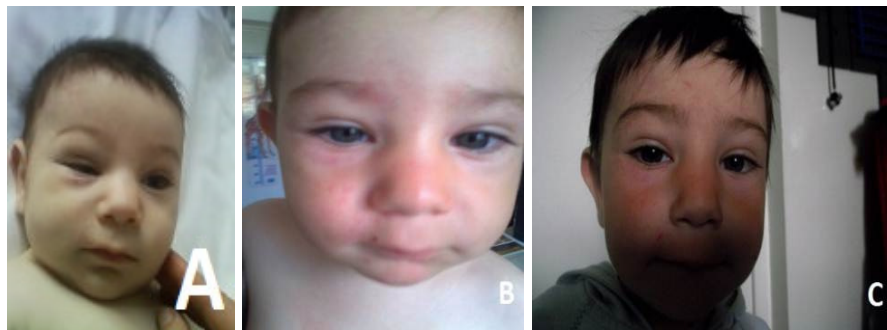

Fig. 4. Case 4: A. Before; B. After 8 months; C. After 1 years and 6 month.

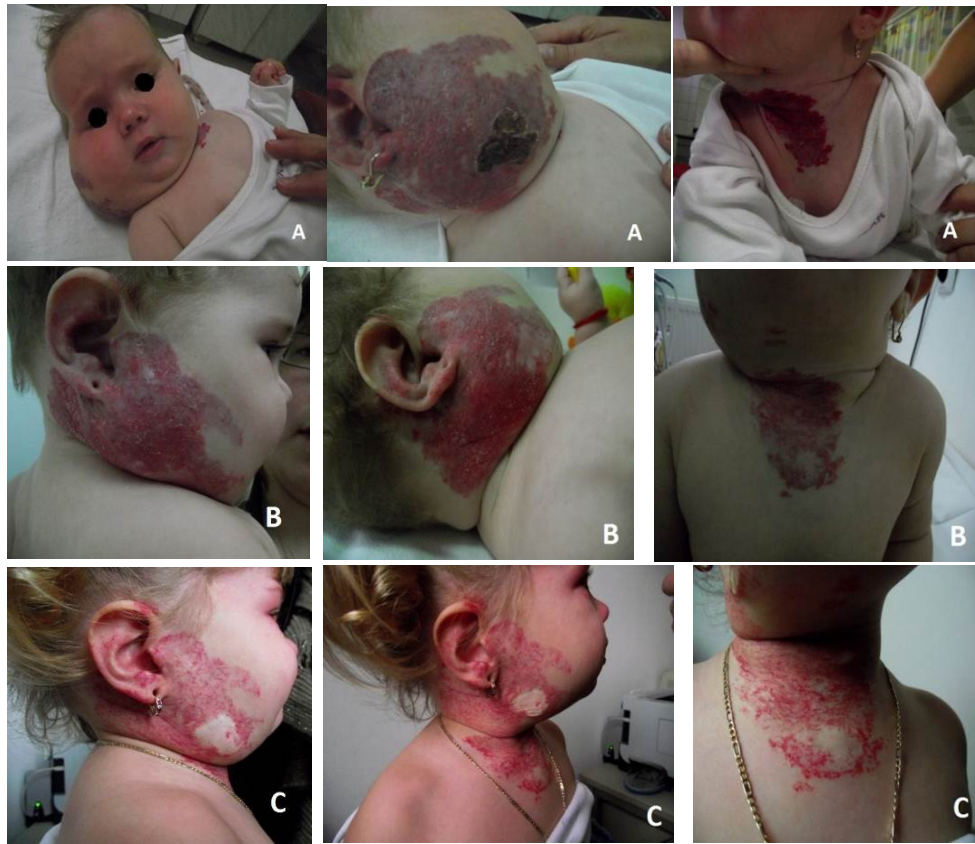

Fig. 5. Case 5: A. Before treatment B. After 10 week; C. After 14 months.

The outcome of each lesion was defined by its status at the last recorded patient visit. Outcomes are classified as: 1-very good if the final observation indicates that the lesion has more than 90% disappeared, 2-good if the lesion has more than 70% disappeared, 3-partial if the lesion has less than 50% disappeared, 4-early removing from study by parents.

### Results

The distribution of the 44 hemangiomas was as follows: 24 cases on the head and neck (2 forehead, 3 periorbital, 2 upper eyelid, 1 lower eyelid, 2 lower lip, 5 facial, 2 cervical, 1 at ear lobe, and 6 scalp); 8 cases on the trunk (3 thorax, 2 breast and 3 abdominal wall); 11 cases on the extremities, and 1 case in the anogenital region. Lesion type was multifocal in 9 cases.

Three patients left the study after only 1 month of treatment, based on parent's decision.

The treatment did not affect blood pressure and heart rate. None of the parents reported wheezing, and food intake was regular.

Outcomes are: 22 cases (16 completed treatment)-very good (70.96%), 5 cases (still in treatment)- good (16.12%), and 2 cases –partial response (6.45%).

In two cases (6.45%) after 1 month and 3 months of treatment, the lesions did not respond to propranolol and the surgical excision was performed.

One case present one deep infantile hemangioma of the periorbital area and a capillary malformation of the major labia. After 6 months the treatment with propranolol, the periorbital infantile hemangioma present total regression, but the capillary malformation is unchanged.

Only one patient, with a large facial and cervical infantile hemangioma, received another form of treatment (cryotherapy) before propranolol. No relapses were observed in the 16 cases who completed the treatment.

### Case presentation

Case 1: 8 month old boy with a calf IH having a rapid growth over a month. Hemangioma was present in the first week of life as a small red stain. Noteworthy to mention, patient also has dextrocardia. After 8 months of treatment solely a teleangiectasia remained on the spot of the hemangioma. 9 months after treatment cessation, the color of skin became normal (Fig. 1).

Case 2: 3 month old girl with an forearm IH present at 3 week of life in the form of little red stains, and having a rapid growth during the last 2 months prior to treatment initiation. After 12 months of treatment the result was very good (Fig. 2).

Case 3: two month old boy with IH of left ear lobe which began growing during the first week of life and entered an accelerated growth phase 2 weeks prior to initiating therapy, time during which the parents noted bleeding of the hemangioma. After 6 months of treatment the result was very good (Fig. 3).

Case 4: 6 months old girl with a large facial and cervical mixed infantile hemangioma. The lesion was present at birth as a two small red stains and began growing after the first month of life. The patient was treated with cryotherapy, without good result. At 6 months of life start the treatment with Propranolol 2mg/kg body/day. The results is very good, the treatment is still ongoing (Fig. 4).

Case 5: Six months old boy with deep infantile haemangioma, who started in the second month of life. A. The photo is at 4 months of age, with 2 days before started treatment with propranolol. B. After 8 month of propranolol treatment at 2 mg/kgbody/day the eye is open and we stoped the therapy. C. After 1 year and 6 months at the cessation the treatment. The right eye is open (Fig. 5).

### Discussion

IH are composed of multiple cell types: a majority of endothelial cells associated with pericytes, dendritic cells, and mast cells. Histological analyses of IH have generated many developmental theories suggesting an embryonic or primitive cell origin and these debates will finally determine the best treatment for children [18].

North reported on the GLUT-1 positive staining of IH, suggesting a relation of hemangioma to placental tissue [19].

Bree speculated that invasive angioblasts, differentiated by a type of placental cells, or embolized placental cells may initiate the vascular tumors. However, the study does not demonstrate that placental trophoblast is the cell of origin for IH [20].

The new theories focus on progenitor cells, derangement of angiogenesis, mutation in the cytokine regulatory pathway, and developmental field defects [21,22].

The etiology and pathogenesis of hemangiomas remains unknown. Most IH regress without therapy, so for small and uncomplicated hemangiomas the “wait and see” approach may suffice [23].

The methods of treatment, when required, includes: systemic corticotherapy, intralesional corticosteroids, cytotoxic drugs (bleomycin, vincristine, cyclophosphamide), systemic pharmacologic treatments (interferon  $\alpha$ , vincristine and cyclophosphamide), laser therapy, cryotherapy, surgical excision, radiotherapy [10]. Until recently, the first line therapy for complicated IH was systemic corticosteroids [24-26]. The second and third line treatments are vincristine

and interferon  $\alpha$ , both of which were however linked to severe neurotoxic side effects [26]. In spite of the belief that systemic corticosteroid treatment of IH is very safe [27,28] numerous complications (aseptic necrosis of the femoral head, diabetes, osteoporosis, adrenal insufficiency, cataracts, glaucoma, infection, gastric irritation, elevated blood pressure, cushingoid like aspect, and hypothalamic-pituitary-adrenal axis suppression) have been described [29-33].

After Léauté-Labrèze observation [11] of propranolol's effects on hemangiomas, numerous reports describing the same effects have appeared [18,34,35,36,37].

The new treatment for severe IH is a noncardioselective beta adrenergic receptor blocker: propranolol [38,39]. The mechanism of action of propranolol on IH remains unknown. Regulators of hemangioma growth and involution are poorly understood. During the growth phase, two major proangiogenic factors are involved: basic fibroblast growth factor (bFGF) and vascular endothelial growth factor (VEGF). During the involution phase, apoptosis has been shown [40,41]. Potential explanations for the therapeutic effect of propranolol on IH include vasoconstriction, which is immediately visible as a change in color, associated with a palpable softening of the hemangioma; decreased expression of VEGF and bFGF genes through the down-regulation of the RAF–mitogen-activated protein kinase pathway [42,43] (which explains the progressive improvement of the hemangioma); and the triggering of apoptosis of capillary endothelial cells [43].

The mechanism of action of propranolol on IH is open for research but the results obtained seem encouraging.

### Conclusion

For the past 40 years, the use of propranolol has been shown to be safe in children with cardiac disease.

In 70,96% of cases, we observed the fading in color and softening of the hemangioma following the administration of propranolol, with no adverse reactions. We consider that systemic therapy with the nonselective beta-adrenergic receptor antagonist propranolol is an effective treatment for IH, due to its rapid therapeutic effect and good drug tolerability.

We believe that the propranolol will become the first line of treatment for IH, although randomized controlled trials should be developed to compare propranolol and corticosteroid therapy.

Ongoing research is bringing us closer to an understanding of the cause of hemangiomas, which will provide opportunities for personalized therapies.

### References

1. Mulliken JB, Glowacki J. Hemangiomas and vascular malformations in infants and children: A classification based on endothelial characteristics. *Plast Reconstr Surg* 1982;69:412-22

2. Finn MC, Glowacki J, Mulliken JB. Congenital vascular lesions: clinical application of a new classification. *J Pediatr Surg*. 1983 Dec;18(6):894-900.
3. Enjolras O, Mulliken JB. Vascular tumors and vascular malformations. *Adv Dermatol*. 1997; 13:375-423.

4. Restrepo R, Palani R, Cervantes LF, Duarte AM, Amjad I, Altman NR. Hemangiomas revisited: the useful, the unusual and the new. Part 1: overview and clinical and imaging characteristics. *Pediatr Radiol*. 2011; 41: 895-904.
5. Enjolras O. Classification and management of the various superficial vascular anomalies: hemangiomas and vascular malformations. *J Dermatol*. 1997 Nov;24(11):701-10.
6. Enjolras O. Les angiomes de l'enfant a un tournant dans leur comprehension et dans leur prise en charge. *Arch Pediatr* 1999 ; 6: 1261-1265
7. Azizkhan RG. Vascular anomalies of childhood. In: Baker RJ, Fischer JE, eds. *Mastery of Surgery*, chap 28. Philadelphia, PA: Lippincott Williams & Wilkins, 2001:389-403.
8. Kilcline C, Frieden IJ. Infantile hemangiomas: how common are they? A systematic review of the medical literature. *Pediatr Dermatol* 2008;25:168–173.
9. Hamel-Teillac D. Classification des angiomes *Arch Pediatr*. 2007 Jun;14(6):705-8. Epub 2007 Apr 6.
10. Fay A, Nguyen J, Waner M Conceptual Approach to the Management of Infantile Hemangiomas *J Pediatr*. 2010 Dec;157(6):881-8.e1-5
11. Léauté-Labrèze C, Dumas de la Roque E, Hubiche T, Boralevi F, Thambo J-B, Taïeb A. Propranolol for severe hemangiomas in infancy: *N Engl J Med* 2008;358:2649-51
12. Rachel Hajar, MD, FACC\*. The invention of propranolol: history of medicine. *Heart views*. Vol.1 No. 8; June - August 2000: 321-323
13. Al-Wadei HA, Al-Wadei MH, Schuller HM. Prevention of pancreatic cancer by the beta-blocker propranolol. *Anticancer Drugs*. 2009 Jul; 20 (6):477-82
14. Plummer HK 3rd, Yu Q, Cakir Y, Schuller HM. Expression of inwardly rectifying potassium channels (GIRKs) and beta-adrenergic regulation of breast cancer cell lines. *BMC Cancer*. 2004 Dec 16;4:93
15. Brunet A, Orr SP, Tremblay J, Robertson K, Nader K, Pitman RK. Effect of post-retrieval propranolol on psychophysiologic responding during subsequent script-driven traumatic imagery in post-traumatic stress disorder. *J Psychiatr Res*. 2008 May;42(6):503-6. Epub 2007 Jun 22
16. Cremer Hj., Kosel Ch, (2008) Hämangiome (vaskuläre Tumoren) – neue Klassifizierung: Kinder- und Jugendarzt, 39. Jg. Nr. 9,
17. Cremer Hj., Hämangiome, Klassifizierung und Therapie-Empfehlungen: pädiatrie hautnah 2 • 2009, 134-146
18. Sans V, de la Roque ED, Berge J, Grenier N, Boralevi F, Mazereeuw-Hautier J, Lipsker D, Dupuis E, Ezzedine K, Vergnes P, Taïeb A, Léauté-Labrèze C - Propranolol for severe infantile hemangiomas: follow-up report *Pediatrics*. 2009 Sep;124(3):e423-31. Epub 2009 Aug 10.
19. North PE, Waner M, Mizeracki A, Mihm MC Jr GLUT1: a newly discovered immunohistochemical marker for juvenile hemangiomas. *Hum Pathol*. 2000 Jan;31(1):11-22.
20. Bree AF, Siegfried E, Sotelo-Avila C, Nahass G. Infantile hemangiomas: speculation on placental trophoblastic origin. *Arch Dermatol*. 2001 May; 137(5):573-7.
21. Williams RL, Risau W, Zerwes HG, Drexler H, Aguzzi A, Wagner EF. Cells expressing the polyoma middle T oncogene induce hemangiomas by host cell recruitment. *Cell*. 1989 Jun 16;57(6):1053-63.
22. Condtantijn G, Bauland, Maurice A.M. van Steensel, Peter M. Steijlen, Paul N.M. A. Rieu, Paul H. M. Spauwen. The Pathogenesis of Hemangiomas: A Review *Plast. Reconstr. Surg*. 117:29e, 2006
23. Frieden IJ, Eichenfield LF, Esterly NB, Geronemus R, Mallory SB-Guidelines of care for hemangiomas of infancy. American Academy of Dermatology Guidelines/Outcomes Committee. *J Am Acad Dermatol*. 1997 Oct;37(4):631-7
24. Boon LM, MacDonald DM, Mulliken JB. Complications of systemic corticosteroid therapy for problematic hemangioma. *Plast Reconstr Surg*. 1999 Nov;104(6):1616-23
25. George ME, Sharma V, Jacobson J, Simon S, Nopper AJ. Adverse effects of systemic glucocorticosteroid therapy in infants with hemangiomas. *Arch Dermatol*. 2004 Aug;140(8):963-9.
26. Drolet BA, Esterly NB, Frieden IJ Hemangiomas in children. *N Engl J Med*. 1999 Jul 15;341(3):173-81
27. Greene AK, Couto RA. Oral prednisolone for infantile hemangioma: efficacy and safety using a standardized treatment protocol. *Plast Reconstr Surg* 2011;128:743-752
28. Greene AK. Systemic corticosteroid is effective and safe treatment for problematic infantile hemangioma. *Pediatr Dermatol* 2010;27:322-323
29. Bennett ML, Fleischer AB, Chamlin SL, et al. Oral corticosteroid use is effective for cutaneous hemangiomas: an evidence based evaluation. *Arch Dermatol* 2001;137:1208-1213
30. Boon LM, MacDonald DM, Mulliken JB. Complications of systemic corticosteroid therapy for problematic hemangiomas. *Plast Reconstr Surg* 1999;104:1616-1623
31. George ME, Sharma V, Jacobson J, et al. Adverse effects of systemic glucocorticosteroid therapy in infants with hemangiomas. *Arch Dermatol* 2004;140:963-969
32. Lomenick JP, Bacheljauw PF, Lucky AW. Growth, bone mineral accretion, and adrenal function in glucocorticoid-treated infants with hemangiomas. A retrospective study. *Pediatr Dermatol* 2006;23:169-174
33. Lomenick JP, Reifschneider KL, Lucky AW, et al. Prevalence of adrenal insufficiency following systemic glucocorticoid therapy in infants with hemangiomas. *Arch Dermatol* 2009;145:262-266
34. Rosbe KW, Suh KY, Meyer AK, et al. Propranolol in the management of airway infantile hemangiomas. *Arch Otolaryngol Head Neck Surg* 2010;136:658-665
35. Lawley LP, Siegfried E, Todd JL. Propranolol treatment for hemangioma of infancy: risks and recommendations. *Pediatr Dermatol* 2009;26:610-614

36. Frieden IL, Drolet BA. Propranolol for infantile hemangiomas: promise, peril, pathogenesis. *Pediatr Dermatol* 2009;26:642-644
37. Bonini FK, Bellodi FS, Souza EM. Propranolol treatment for hemangioma of infancy. *An Bras Dermatol*. 2011 Aug; 86(4):763-616.
38. Storch CH, Hoeger PH. Propranolol for infantile hemangiomas: insights into the molecular mechanism of action. *Br J Dermatol*. 2010 Aug; 163(2):269-74. Epub 2010 May 8.
39. Love JN, Sikka N. Are 1-2 tablets dangerous? Beta-blocker exposure in toddlers. *J Emerg Med*. 2004 Apr; 26(3):309-14.
40. Greenberger S, Bischoff J. Infantile Hemangioma- Mechanism(s) of Drug Action on a Vascular Tumor. *Cold Spring Harb Perspect Med*. 2011 Sep;1(1):a006460
41. Boye E, Yu Y, Paranya G, Mulliken JB, Olsen BR, Bischoff J. Clonality and altered behavior of endothelial cells from hemangiomas *J Clin Invest*. 2001 Mar; 107(6):745-52.
42. D'Angelo G, Lee H, Weiner RI. cAMP-dependent protein kinase inhibits the mitogenic action of vascular endothelial growth factor and fibroblast growth factor in capillary endothelial cells by blocking Raf activation. *J Cell Biochem* 1997; 67:353-366.
43. Sommers Smith SK, Smith DM. Beta blockade induces apoptosis in cultured capillary endothelial cells. *In Vitro Cell Dev Biol Anim* 2002; 38:298-304.

Correspondence to:

Calin Popoiu  
Pediatric Surgery and Orthopaedics Clinic  
Children's Emergency Hospital "Louis Turcanu"  
Timisoara  
tel +40256203373  
E-mail: mcpopoiu@yahoo.com