

MISDIAGNOSED MECKEL'S DIVERTICULUM CAUSING SEVERE HEMORRHAGE - CASE REPORT

H Gocan¹, A Surd¹, Rodica Muresan¹

Abstract

Meckel's diverticulum was first described by Fabricius Hildanus in 1598. The name derives from the German anatomist Johann Friedrich Meckel who described the embryological and pathological features in 1809 [1]. Although it generally remains silent but life threatening complications may arise making it an important structure for having a detailed knowledge of its anatomical and pathophysiological properties to deal with such complications. Meckel's diverticulum has varied presentations in children and often becomes a diagnostic challenge. We present a 14-year-old boy with a history of recurrent periumbilical pain and one episode of melena. His symptoms were undervalued during a previous hospitalization in a pediatric units until he was brought to our clinic for abdominal pain and massive rectal bleeding. The intervention performed in emergency identified a perforated bleeding Meckel's diverticulum with massive hemoperitoneum, that was resected. Our observation shows that severe hemorrhage due to a Meckel's diverticulum although exceptional, is possible.

Key words: Meckel diverticulum, abdominal pain, rectal bleeding, hemoperitoneum

Introduction

Meckel's diverticulum (MD) occurs in about 2% of the population, making it the most prevalent congenital abnormality of the gastrointestinal tract. It can be asymptomatic or mimic common abdominal disorders. We report a case of a child with an intraoperative diagnosis of MD, with a long history of recurrent abdominal pain, vomiting and one episode of melena misdiagnosed as a cyclic vomiting syndrome.

Case report

A 14-year-old boy was referred to one of our pediatric unit with a one month history of periumbilical colicky pain with associated alimentary vomiting. The pain usually spontaneously disappeared within a few hours. During the period before our visit, the painful episodes lasted longer and were reported to occur also at night. No diarrhoea was reported, the boy was rather constipated. Previous medical investigations, abdominal ultrasonography and plain abdominal film were negative.

Neither abdominal tenderness, nor liver or spleen enlargement, nor abdominal masses were identified at palpation. Complete blood cell count, electrolytes, glycemia, blood ammonia, renal and hepatic function, pancreatic enzymes, C-reactive protein, erythrocyte sedimentation rate, and gamma globulins were within normal ranges.

A plain abdominal film was unremarkable, and a small bowel enema indicated normal transit and normal appearance of the intestinal loops. During the hospitalisation the patient presented one episode of melena. The upper and lower digestive endoscopy were negative. The patient was hydrated and received antibiotics. He was discharged after 5 days of hospitalisation.

On the 4th day he was referred to our clinic with severe abdominal pain, vomiting and fresh blood in stool. Full blood count showed mild leucocytosis with white blood cell count of 11500 and PCR 4,5.

The ultrasound revealed distended bowel loops with slow peristalsis and containing fluid. Also free abdominal fluid was found. The plain abdominal film revealed air-fluid levels and opacification of the pelvic region.

Emergency laparotomy was performed. The intraoperative macroscopic finding was that of a perforated MD with hemoperitoneum and appendiceal reaction. Segmental resection of the small bowel along with appendectomy was performed (Fig.1).

Discussions

MD is the most common congenital anomaly of the gastrointestinal tract. The "rule of two" can remind us of some of its main features: occurs in 2% of the population; usually discovered before 2 years of age; occurs within 2 feet of the ileocecal valve; is 2 inches long and 2 cm in diameter [2]. It is the result of an incomplete atrophy of the omphalomesenteric duct. The location of the diverticulum is on the antimesenteric border of the small intestine, most frequently between 30 cm and 90 cm from the ileocecal valve; there can be a fibrous connection to the umbilicus, as the remnant of the partially obliterated vitelline duct.

MD is a true diverticulum, composed of all layers of the intestinal wall, and is lined by normal small intestine epithelium. Gastric heterotopias can be found in roughly 50% of cases, and pancreatic, duodenal, colonic, or biliary mucosa have rarely been reported.

¹Emergency Children's Hospital, Department of Pediatric Surgery, Cluj-Napoca
E-mail: horatiugocan@yahoo.com, adisurd@yahoo.com, muresanrodicaana@yahoo.com

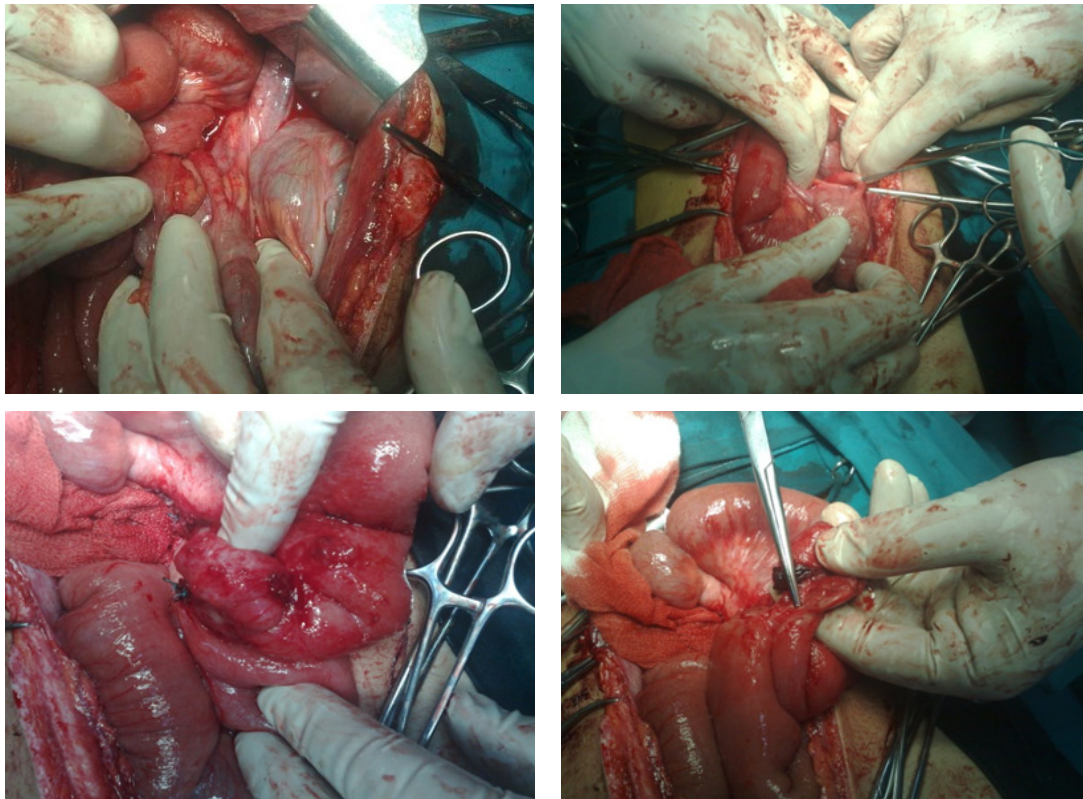


Fig 1. Intraoperative aspects.

MD can be silent all through a lifetime: clinical symptoms arise from complications (MD carriers have a 4% lifetime risk of developing a complication) [3]. Hemorrhage is the result of peptic ulceration of the ileal mucosa next to an acid-producing gastric mucosal heterotopia: the presentation of the blood loss varies from recurrent minimal intestinal bleeding, to a massive, shock-producing hemorrhage, and it is usually painless. Diverticulitis can mimic an acute appendicitis: pain is frequently localized in the midline or slightly to the right and, as in appendiceal disease, inflammation can progress until perforation. The diverticulum can invert into the ileal lumen and become the starting point of an ileo-ileal or ileo-ileo-colic intussusception: symptoms can not be discriminated from those ascribed to idiopathic intussusception, even though the onset of the former is described to occur at an earlier age. A further mechanism by which MD can produce intestinal obstruction is to turn around a fibrous remnant: symptoms may vary from intermittent recurrent subocclusive episodes, as in our patient, to frank occlusion with strangulation features if a complete volvulus occurs [4]. Preoperative diagnosis of a complicated MD can be challenging and often difficult to establish because clinical symptoms and imaging features overlap with those of other disorders causing acute abdominal pain or gastrointestinal bleeding [5].

Initially, our case was misdiagnosed as a cyclic vomiting syndrome and a functional abdominal pain, since

neither inflammatory nor bleeding clinical features were present, and laboratory tests were substantially within normal ranges. Considering the episode of melena, although a single one, a ^{99m}Tc -pertechnetate scintigraphy would have been indicated: the principle is that a bleeding diverticulum consists of ulcerated ectopic gastric mucosa that can be revealed with ^{99m}Tc -pertechnetate. This concentrates in gastric tissue leading to a reported sensitivity of between 60% and 80% [6].

The clinical findings at the second hospitalisation, along with the US and plain radiograph suggested that emergency surgery must be performed. Complicated MD has a spectrum of radiological features which may help in the preoperative investigations, but are not always diagnostic [7-9]. Final diagnosis is almost always done at surgery: exploratory laparoscopy or laparotomy is recommended because it affords the possibility of simultaneous surgical resection, which is the definitive cure of a symptomatic MD.

In conclusion, Although MD is the most prevalent congenital abnormality of the gastrointestinal tract, it is often difficult to diagnose. The diagnosis of MD should be considered in children with intestinal bleeding, unexplained recurrent abdominal pain, and nausea and vomiting suggestive of cyclic vomiting syndrome.

References

1. Pollak Raymond: Adjunctive Procedure in Intestinal Surgery. In *Mastery of surgery* Fifth edition. Edited by Fischer JE. 2007, 1392-1393.
2. Skandalakis PN, Zoras O, Skandalakis JE, Mirilas P. Littre hernia: surgical anatomy, embryology, and technique of repair. *Am Surg* 2006; 72: 238-743
3. Martin JP, Connor PD, Charles K. Meckel's diverticulum. *Am Fam Physician* 2000; 61: 1037-1042, 1044
4. Yahchouchy EK, Marano AF, Etienne JC, Fingerhut AL. Meckel's diverticulum. *J Am Coll Surg* 2001; 192: 658-662
5. McCollough M, Sharieff GQ. Abdominal pain in children. *Pediatr Clin North Am* 2006; 53: 107-137,
6. Poulsen KA, Qvist N. Sodium pertechnetate scintigraphy in detection of Meckel's diverticulum: is it usable? *Eur J Pediatr Surg* 2000; 10: 228-231
7. Elsayes KM, Menias CO, Harvin HJ, Francis IR. Imaging manifestations of Meckel's diverticulum. *AJR Am J Roentgenol* 2007; 189: 81-88
8. Thurley PD, Halliday KE, Somers JM, Al-Daraji WI, Ilyas M, Broderick NJ. Radiological features of Meckel's diverticulum and its complications. *Clin Radiol* 2009; 64: 109-118
9. Daneman A, Lobo E, Alton DJ, Shuckett B. The value of sonography, CT and air enema for detection of complicated Meckel diverticulum in children with nonspecific clinical presentation. *Pediatr Radiol* 1998; 28: 928-932

Correspondence to:

Horatiu Gocan
Moșilor Street, no.68
Cluj-Napoca
Romania
E-mail: horatiugocan@yahoo.com