

## RETINOPATHY OF PREMATURITY - RISK FACTORS FOR EVOLUTION

Ramona Albulescu<sup>1</sup>, Florina Stoica<sup>1</sup>, Nicoleta Andreescu<sup>1</sup>, Maria Puiu<sup>1</sup>

### Abstract

Retinopathy of prematurity (ROP) is a disorder characterised by abnormal retinal vascular development, and several risk factors are involved. The condition may be in mild form or it may result in retinal detachment which may eventually cause blindness. The management of the risk factors involved in the disease etiopathogenesis and the treatment by laser photocoagulation performed in early stages of the disease are important factors that contribute to less premature infants with retinopathy of prematurity.

**Key words:** retinopathy of prematurity, risk factors, retinal detachment

### Introduction

Retinopathy of prematurity (ROP) is a disorder characterised by abnormal retinal vascular development due to the disorganized growth of retinal blood vessels and several risk factors are involved. ROP affects prematurely-born babies with low birth weight. The incidence of the retinopathy of prematurity is inversely related to the gestational age and the weight at birth. The condition may be in mild form or it may result in retinal detachment, which may eventually cause blindness. (1)

Retinopathy of prematurity may be described according to location, stage and extent (1,2).

For the purpose of defining the location, three concentric zones were defined, centred on the optic disc:

- zone I: a circle, the radius of which extends from the centre of the optic disc to twice the distance from the centre of the optic disc to the centre of the macula,

- zone II: retinal zone which extends centrifugally from the edge of zone I to the nasal ora serrata (at 3 o'clock in the right eye and 9 o'clock in the left eye), the circle reaching the area of the anatomical equator on the temporal side.

- zone III: the residual crescent-moon retina, anterior to the edge of zone II. (1,2)

According to extent, retinopathy of prematurity is quantified as number of clock-hours of involvement, as if the top of the eye were 12 on the face of a clock. Therefore, pathology at the 3 o'clock position corresponds to the right and nasal side of the right eye and the temporal side of the left eye, while the 9 o'clock position corresponds to the left and temporal side of the right eye and the nasal side of the left eye, as the examiner looks at the patient's eyes (1,2).

There are several stages of retinopathy of prematurity:

- stage 0: the retinal vascularisation is incomplete or "immature";

- stage 1: a thin, but well-defined white division line, at the junction between the posterior vascularised and anterior avascular retina. There may also be noticed an abnormal vascular tortuosity, stopping at the division line;

- stage 2: an elevated ridge, specific to the stage 2, replacing the line. It is characterised by volume in height and width, extending out of the plane of the retina. The ridge may change colour from white to pink, and the vessels may proliferate outside the plane of the retina, beyond the ridge and into the vitreous. It should be noted that the presence of these retinal vessels, elevated outside the plane of the retina and into the ridge, do not represent a posterior retina detachment.

Sometimes, small isolated tufts of neovascular tissue lying on the surface of the retina, commonly called "popcorn" may be seen posterior to this ridge structure. These do not constitute the degree of fibrovascular growth that is a necessary condition for stage 3;

- stage 3: extraretinal fibrovascular proliferation or neovascularization, specific to stage 3, is mainly localised as follows: a) continuous with the posterior edge of the ridge, causing a ragged appearance of the ridge; b) into the vitreous, perpendicular to the plane of the retina; c) immediately after the posterior edge of the ridge, however not always connected to it;

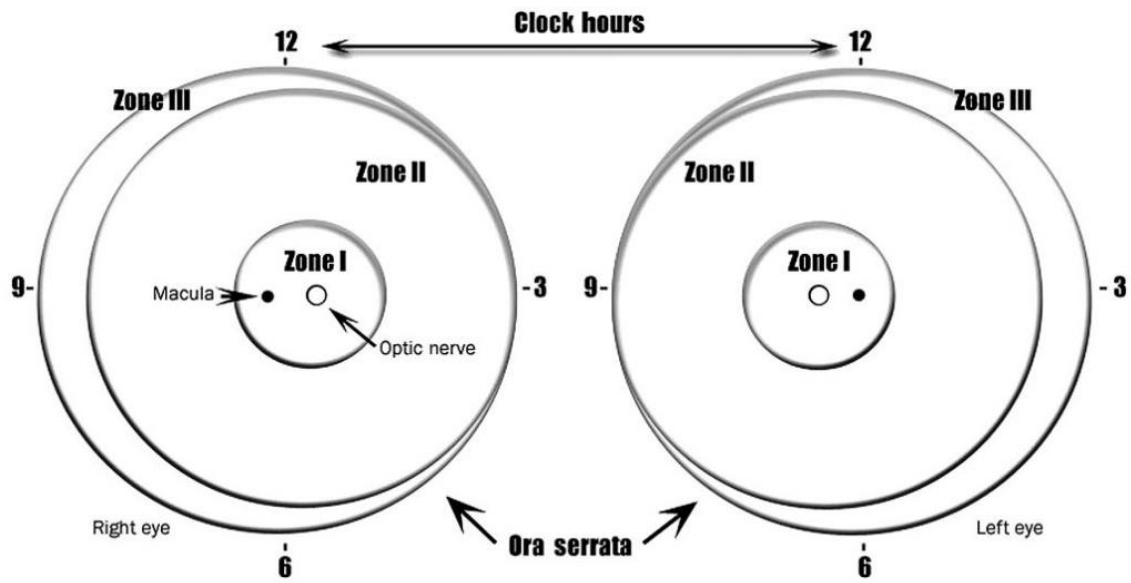
- stage 4: partial retinal detachment, which can be further divided into: stage 4A, which includes extra-foveal retinal detachment, and stage 4B, where the partial retinal detachment includes the fovea. Stage 4 retinal detachments are generally concave and most are circumferentially oriented. Its localization and extent need further analysis. Usually, retinal detachments begin at the point of fibrovascular attachment to the vascularised retina and then advance both towards the anterior and the posterior edges;

- stage 5: total retinal detachment, generally tractional and usually funnel-shaped, being sometimes exudative; according to the funnel configuration, it can be subdivided depending if the anterior and posterior portions are open or narrowed.(1,2)

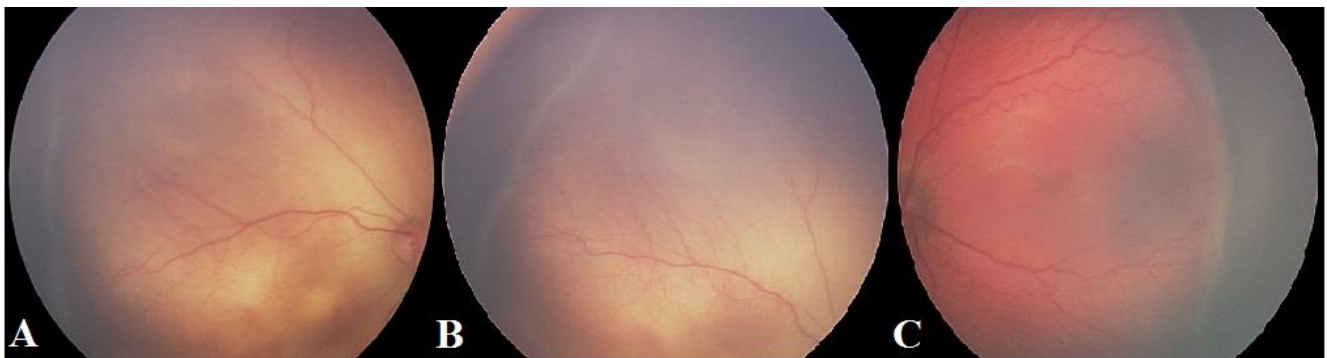
As more than one stage may be present in the same eye, staging the ROP for the eye as a whole is determined according to the most severe stage present (3).

<sup>1</sup>“Victor Babes” University of Medicine and Pharmacy, Timisoara, Romania

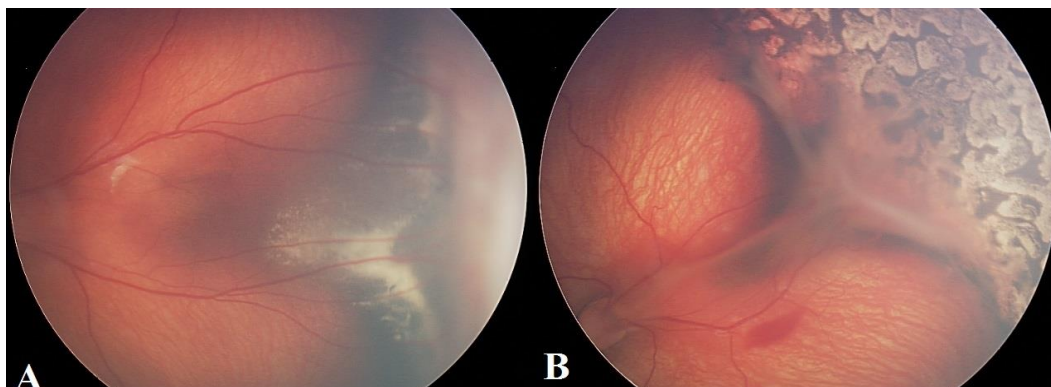
E-mail: albulescu.ramona@gmail.com, florinastoica@gmail.com, nicollandreescu@yahoo.com, maria\_puiu@umft.ro



**Graphic 1.** Reference zones used for ROP classification ([www.eophta.com](http://www.eophta.com))



**Figure 1.** A. - ROP stage 1, B. - ROP stage 2, C. - ROP stage 3+ ([www.intechopen.com](http://www.intechopen.com))



**Figure 2.** A. - ROP stage 4A, B. - ROP stage 4B ([www.ejournalophthalmology.com](http://www.ejournalophthalmology.com))

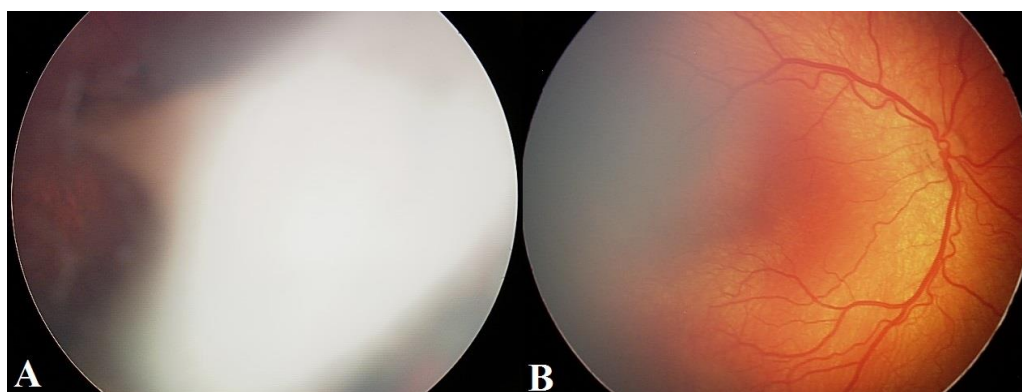
Besides the lesions described above, ROP may be characterised by additional signs of disease development, called “plus-disease” (PD) factors, which include increased venous dilatation and arteriolar tortuosity of the posterior retinal vessels which can increase in severity to include iris vascular engorgement, poor pupillary dilatation (pupillary rigidity), and vitreous haze. A "plus" sign is added to the disease stage when more than one of the above signs of severity is identified (3).

**Aggressive posterior retinopathy of prematurity**

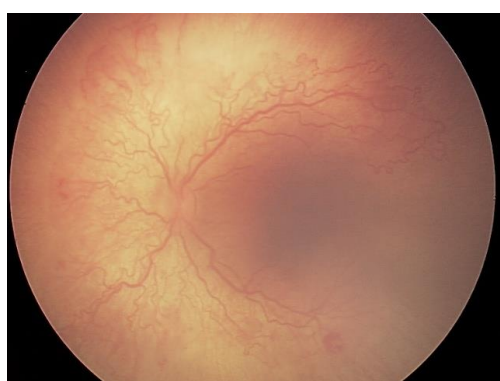
The gravity ROP in zone I and the different aspect of severe disease in this area have required recent definition by the international committee composed of ROP classification, the concept of aggressive posterior retinopathy of prematurity. This is a severe form of ROP, which is progressing rapidly and has the characteristics: posterior location (zone I or posterior zone II), the gravity factor as opposed to the addition of poorly defined

peripheral retinopathy (a system of new blood vessels, with hard features said, at the junction with the avascular retina vascular). Aggressive posterior retinopathy of prematurity extends circumferentially, the vascular changes rapidly evolving and requiring emergency treatment setting. Alternatively, the disease reaches Stage 5 of the ROP (3).

Objective: Monitoring the evolution of the retinopathy of prematurity when risk factors are involved. The screening programme for the diagnosis of ROP aims at determining the optimum timing for treatment administration in prematurely-born infants which are suspected to develop severe forms of the disease, and at reducing, as much as possible, the number of examinations in children with ROP risk, as such examinations are rather unpleasant. The intervals between examinations was not fixed, it varied according to the retinopathy development stage (3).



**Figure 3.** A. ROP stage 5, B. ROP “Plus-disease” factors ([www.retinophatyprematurity.com](http://www.retinophatyprematurity.com))



**Figure 4.** Aggressive posterior retinopathy of prematurity ([www.intechopen.com](http://www.intechopen.com))

**Material and method**

The research study was performed at the maternity ward in "Dumitru Popescu" Hospital Timisoara, and the research team included a neonatologist, a paediatrician and an ophthalmologist, the contribution of each team member being very important in the early screening of prematurely-born infants presenting a risk of ROP development, as well as in establishing an early diagnosis of ROP, in order to administer the optimal treatment and prevent long-term complications.

The ophthalmologist performed the examination with an ophthalmoscope. With the use of an indirect ophthalmoscope and a 20-dioptre lens, first the anterior and then the posterior poles were examined. The examination was performed according to the examination protocol included in the ROP screening.

**Results**

There have been examined 50 prematurely newborn infants ( from Timisoara and neighboring areas) that included all the infants with BW (born weight) <1500 g and with GA (gestational age)<32 weeks and also other infants over 32 weeks that presented associated risk factors (oxygen, ventilation, sepsis, etc). The repartition on gestational age and born weight was the following: 17 infats with GA between 24-28 weeks and BW 750-1000 g, 22 infants GA 28-32 weeks and BW between 1000-1500 g, and 11 infants with GA>32 and BW>1500g.

From the study lot, 28 infants (56%) did not present ROP modification; 22 infants had ROP (44% in risk category).

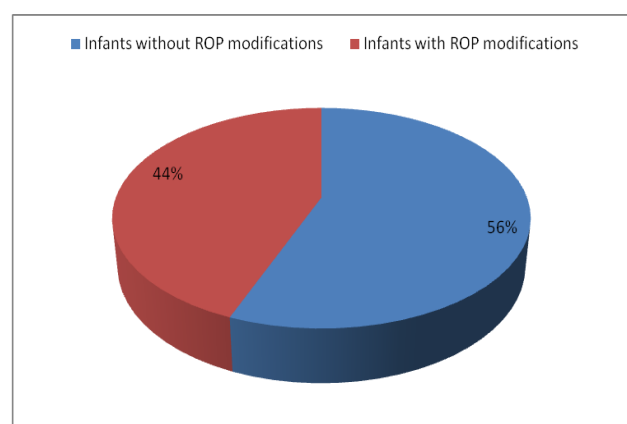
Using the ICROP classification, we have the following repartition on stage: stage 1= 10infants (18%), stage 2=7 infants (14%), stage 3=5 infants (10%), stage 4=1infants (2%), stage 5= 0 infants. All the infants examined received supplemental oxygen and most of them had anemia.

From the 6 infants (stage 3 and stage 4 of ROP), at three of them was done laser treatment.

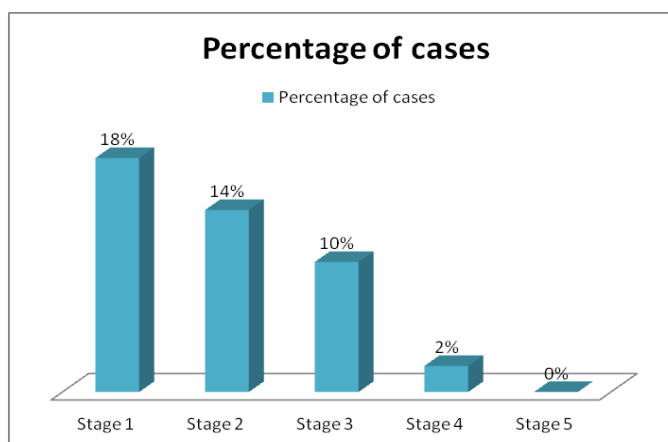
We report the different evolution of ROP in two prematurely-born infants from twins' cases, with multiple associated risk factors, admitted to the maternity ward in the "Dumitru Popescu" Hospital from Timisoara.

Case 1. The prematurely-born infant P.D. was included in the screening for retinopathy assessment at 35 weeks corrected postnatal age. The infant was diagnosed with stage-2 retinopathy of prematurity in zones I and II, with severe plus disease, and the later evolution became rapidly unfavourable. Laser therapy was performed 24 hours from the diagnosis. After the laser therapy, the evolution is still unfavourable. Approximately one month after the laser therapy, the diagnosis is stage-4 retinopathy of prematurity, and the parents were instructed to have the infant examined at a vitreous-retinal surgery clinic, yet the surgery is not performed. At present, the child is monitored at the Ophthalmology Clinic from Timisoara, with the following diagnosis: Right eye: ROP, stage 4b, partial retinal detachment, post-laser treatment status; Left eye: ROP, stage 4a, partial retinal detachment (nasal side), post-laser treatment status;

Case 2. The prematurely-born infant A.M. was included in the screening for retinopathy assessment at 37 weeks correct postnatal age. Upon ophthalmologic examination, the premature infant was diagnosed with stage-1 retinopathy of prematurity. The later development of the disease was unfavourable, and one week of monitoring, the diagnosis is posterior aggressive ROP/AO. Laser therapy was performed 24 hours from the diagnosis, and the later development was favourable. At present, the child is monitored at the Ophthalmology Clinic from Timisoara, with the following diagnosis: post-laser retinopathy of prematurity/AO, and severe myopia, and is subjected to regular assessments.



**Graphic 2.** The report between the infants presenting ROP modifications and the subplot without ROP



**Graphic 3.** Stages of ROP found in the study lot

Supplemental oxygen	50 infants (100%)
Intraventricular haemorrhage	40 infants (80%)
Respiratory distress syndrome	21 infants (42%)
Surfactant	8 infants (16%)
Sepsis	33 infants (66%)
Anaemia	49 infants (98%)
Blood transfusion	3 infants (6%)
Maternal associated risk factors	18 infants (36%)

**Table 1.** Complications found in infants included in this study

<b>Associated risk factors</b>	<b>Prematurely P.D</b>	<b>Prematurely A.N</b>
Gestational age	28 weeks	29 weeks
Birth weight	1100g	1120 g
Oxygen therapy	24 h	18 h
Anemia	Hb= 6,9 g/l	Hb= 7 g/l
Blood transfusion	2	2
Intraventricular bleeding	Grad II	Grad II
Maternal risk factors	Anemia, Imminent abortion	Anemia, Placenta praevie
Apgar index	6	6

**Table 2.** Associated risks factors found the presented cases

## Discussions

There are two theories explaining the retinopathy in premature infants: the oxygen toxicity and hypoxia theory and the "hiatus" links formation theory. Retinopathy in premature infants develops in two stages, influenced by factors such as the presence/absence of oxygen or by oxygen-independent factors (8) One major oxygen-related factor is the vascular endothelial growth factor (VEGF), together with another major oxygen-independent factor, the insulin-like growth factor 1 (IGF-1). Stage I (hyperoxia) of ROP starts with a delay in the development of retinal vascularisation immediately after birth and continues with the partial regression of existing vessels, followed by Stage II induced by hypoxia. Hyperoxia induces changes in the VEGF: suppressed VEGF in the first phase of ROP prevents physiologic retinal vascular development, while high VEGF determined by the phase-2 hypoxia of the ROP lead to abnormal vascular proliferation or neovascularisation (8,9)

A major role in this theory is played by the IGF-1 insulin-like growth factor 1, which acts directly to stimulate the VEGF for the maximum vascular development. The lack of IGF-1 in the prematurely-born infants prevents normal vascular development in phase-1 of the ROP, despite VEGF being present. As the prematurely-born infant grows, the increased IGF-1 levels in phase-2 of the ROP allow the VEGF to stimulate physiological vascular development (neovascularisation). It is believed that bringing the IGF-1 to the normal level immediately after the birth of a premature infant might be useful in preventing the ROP. At the same time, the presence of oxygen free radicals leads to the membrane alteration of the mesenchymal fusiform cells (precursors of the vascular wall), leading to the formation of

"hiatus"-like links, which will prevent the formation of normal blood vessels.

The retina of prematurely born infants is not completely developed, and this is also the case of the other organs. The presence of risk factors determines an abnormal development of the retina and thus leads to the retinopathy of prematurity (9).

Various risk factors contribute to the development of ROP. They are: gestational age less than 32 weeks, and especially less than 30 weeks, birth weight under 1,500 g, and especially infants with birth weight lower than 1,200 g (1% for the infants with birth weight over 1,500 g, 80% for the infants with birth weight between 750 and 1,000 g - 10% severe forms, and approximately 100% for the infants with birth weight between 500 and 750 g - 10% develop severe forms of ROP) (10)

There is a close connection between oxygen therapy and ROP, between the duration of oxygen exposure and the severity (disease stage) of retinopathy

Hypoxia (insufficient oxygen) represents a risk factor, as the increased carbon dioxide level in the blood influences the retinal metabolism and induces extremely high VEGF, which has a negative impact on eyesight.

Assisted fertilisation methods (especially the in-vitro fertilisation) contribute to the increased incidence in ROP by increasing the incidence of multiple pregnancy and, therefore, of premature births.

Blood transfusion, as risk factor in ROP development, may be explained by the fact that premature infants receive adult haemoglobin whose oxygen desaturation index is different from the foetal haemoglobin, thus providing an additional quantity of oxygen at tissue

level. In the uterus, the tissue oxygen level is low and the normal vascular development in the retina is partially determined by the "physiological hypoxia" (10).

Vitamin E deficit occurs due to the fact that prematurely-born infants do not receive the needed vitamins in the last trimester of pregnancy. The role of vitamin E in the child development is important due to its anti-oxidant characteristics. Pharmacological doses of vitamin E have been proposed for the treatment of premature infants with low birth-weight, in order to prevent the incidence of ROP, intra-cranial haemorrhage, haemolytic anaemia and pulmonary chronic diseases. However, very high doses of vitamin E can have negative consequences, as it increases the risk of infections that can cause death. Vitamin E supplements, especially when administered intravenously, increase the risk of intra-cerebral haemorrhage. The optimal dose of vitamin E for parenteral administration to prematurely-born infants has still not yet been determined. Vitamin E is not recommended in preventing the ROP, due to its undesirable side effects, while vitamin E supplements reduce the risk of developing severe retinopathy. (10, 11)

Other possible risk factors include maternal factors (anaemia, gestational diabetes, sepsis, and antihistamine administration during pregnancy)

The risk factors associated for the two prematurely-born infants presented in this paper are mentioned in Table 2.

Increased support is given to establish the role of genetic factors in the development of the retinopathy of

prematurity, a serious visual morbidity determined by premature birth. The specialty literature has reported research studies indicating the implication of three "single nucleotide polymorphisms" (SNPs), two in the CFH-gene and one in the EPAS1-gene. Upon expansion of this analysis, it was concluded that five SNPs from five genes (IHH, AGTR1, TBX5, CETP, GP1BA) are involved in the ROP development. (12)

### Conclusions

Pregnant women should be monitored as closely as possible by the family physician and the obstetrician, in order to prevent premature births. A child born as closely to the term as possible has higher chances to have a well-vascularised retina, as compared with the prematurely-born infants and, therefore, there is a lower risk to develop ROP. The management of the risk factors involved in the disease etiopathogenesis and the treatment by laser photocoagulation performed in early stages of the disease (in order to stop disease evolution before final changes occur in the retina) are important factors that contribute to less premature infants with retinopathy of prematurity.

Although both prematurely-born infants were exposed to the same associated risk factors, the evolution of retinopathy was different - the theory of the genetic factor as risk factor, contributing to the ROP development is becoming more and more plausible. Our research study was very restricted, as it included only two prematurely-born infants; therefore we cannot completely support this theory.

### References

1. The International Classification of Retinopathy of Prematurity Revisited – An International Committee for the Classification of Retinopathy of Prematurity. Arch.Ophthalmol. – Vol.123, July 2005.
2. Wilkinson AR, Haines L, Head K, et al. UK retinopathy of prematurity guideline. Eye 2009;23:2137–9.
3. American Academy of Pediatrics Section on Ophthalmology; American Academy of Ophthalmology; American Association for Pediatric Ophthalmology and Strabismus; American Association of Certified Orthoptists. Screening examination of premature infants for retinopathy of prematurity. Pediatrics. Jan 2013;131(1):189-95
4. www.eophta.com
5. www.ejournalophthalmology.com
6. www.retinophatyprematurity.com
7. www.intechopen.com
8. Csak K, Szabo V, Szabo A, et al. Pathogenesis and genetic basis for retinopathy of prematurity. Front Biosci. Jan 1 2006;11:908-2065.Chen J., Smith LE : Retinopathy of prematurity , Angiogenesis 2007, 10(2) : 133-140
9. Fleck BW, McIntosh N. Pathogenesis of retinopathy of prematurity and possible preventive strategies. Early Hum Dev 2008;84:83–8.
10. Seiberth V, Linderkamp O. Risk factors in retinopathy of prematurity. a multivariate statistical analysis. Ophthalmologica. 2000; 214(2):131-5.
11. Karna P, Muttineni J, Angell L, et al. Retinopathy of prematurity and risk factors: a prospective cohort study. BMC Pediatr. 2005;5:18.
12. Shakir Mohamed, Kendra Schaa, Margarete e. Cooper, Elise Ahrens, Ana Alvarado, Tarah Colaizy, Mary L. Marizia, Jeffrey C. Murray, John M. Dagle: Pediatric Research Vol. 65, No. 2, 2009 : Genetic Contributions to the Development of Retinopathy of Prematurity

Correspondance to:

Nicoleta Andreescu,  
Discipline of Genetics,  
University of Medicine and Pharmacy "Victor Babes"  
2, Pta Eftimie Murgu  
Timisoara, Romania  
E-mail: nicollandreescu@yahoo.com