

DUPLICATED COLLECTING SYSTEM-DIAGNOSTIC AND THERAPEUTIC ASPECTS

Daescu Camelia^{1,2}, Portaru Laura², Marginean Otilia^{1,2}, Militaru Andrea^{1,2}, Popoiu Calin^{3,4}, Vasilie Doru^{3,4}, David Vlad^{3,4}, Marcovici Tamara^{1,2}, Craciun Adrian^{1,2}, Chiru Daniela^{1,2}, Brad Giorgiana^{1,2}, Olariu Laura^{1,2}, Pavel Adina², Pantea Ioana²

Abstract

Objectives: We present the clinical and imaging exploration of four patients that have duplicated collecting system emphasizing the diagnostic and therapeutic features. **Methods:** The cases of: Lacramioara, 10 years old- both sides duplication of renal pelvis and calyces, Alexandra 7 years old - duplicity of renal pelvis and calyces on left side, Denis 1 month old and Bianca 1 year old - complete unilateral duplicated collecting system. **Results:** Presenting reasons: recurrent urinary tract infections, urinary incontinence, bronchopneumonia and sepsis in the neonate. Using the ultrasound investigation, urinary tract abnormalities are being seen and then confirmed by MRI. Therapeutic attitudes differ depending on the severity of the malformation. For the 7 years old girl, the urinary incontinence is due to aberrant implantation of the megaureter in the urethra. In the case of the newborn patient, surgical correction has been performed later on, at the age of 2 years and a half, due to the parent's noncompliance to treatment. **Conclusions:** Higher ureteral dilatation along with large ureter pole is the most specific ultrasound sign for complete double urinary collecting system. Corrective surgery in these cases is necessary.

Keywords: double collector system, renal imaging

Introduction

Duplicated collecting systems, which is also known as duplex collecting systems, consists of two pyelocaliceal systems that are associated with a single ureter or with double ureters. The two ureters empty separately into the bladder or fuse to form a single ureteral orifice. (1) In the literature certain terms are used to better describe the anatomy of this duplicated collecting system, as follows:

- Duplex kidney has a single renal parenchyma that is drained by 2 pyelocaliceal systems.
- Upper or lower pole represent one component of a duplex kidney.
- Duplex system: the kidney has 2 pyelocaliceal systems and is associated with a single ureter or with a bifid

ureter (a partial duplication) or, in the case of a complete duplication, with 2 ureters (double ureters) that drain separately into the urinary bladder.

- Bifid system: two pyelocaliceal systems join at the ureteropelvic junction (bifid pelvis), or 2 ureters join before draining into the urinary bladder (bifid ureters).
- Double ureters: two ureters open separately into the renal pelvis superiorly and drain separately into the bladder or genital tract.
- Upper and lower pole ureters: upper and lower pole ureters drain a duplex kidney's upper and lower poles, respectively. (2)

Duplicated collecting system is found unilateral, as well as bilateral and for most of the times, genitourinary anomalies are associated. Because in some cases this anomaly is asymptomatic, duplicated collecting system is discovered incidentally when performing imaging studies for some other reasons. Furthermore, vesico-urethral reflux of the lower pole ureter and the upper pole ureter dilatation can be associated, as well as the presence of the Ureterocel. (3)

Concerning the imaging studies that can certificate the presence of the duplicated collecting system, abdominal ultrasonography is among the first one being used. The fact that it's noninvasive gives it great advantage when applied to children, but still needs to be followed by MRI and CT scanning for more proper investigation. (4)

Case report

The first patient that the authors present is a 10 year old girl, Lacramioara that has been hospitalized for recurrent urinary tract infections with E coli in the Nephrology department of the Clinical Emergency Hospital for Children "Louis Turcanu", Timisoara. After an ultrasonography and cystography has been performed, a right ureterocel was suspected. The MRI discovers a bilateral duplicated collecting system and the patient remains under medical observation. (Fig. 1)

¹1stClinic of Pediatrics, University of Medicine and Pharmacy "Victor Babes" Timisoara

²1stClinic of Pediatrics, Clinical Emergency Hospital for Children "Louis Turcanu", Timisoara

³Clinic of Pediatric Surgery, EmergencyHospital for Children "Louis Turcanu", Timisoara

⁴Clinic of Pediatric Surgery, University of Medicine and Pharmacy "Victor Babes" Timisoara

E-mail: camidaescu@yahoo.com, lauraportaru@yahoo.com, omarginean@ymail.com, andreamilitaru@yahoo.com, mcpopoiu@yahoo.com, office@cmhypocrate.ro, david.vlad@yahoo.com, t_marcovici@yahoo.com, ac_ro@ymail.com, dani.chiru@yahoo.com, giorgiana.brad@gmail.com, tunealaura@yahoo.com

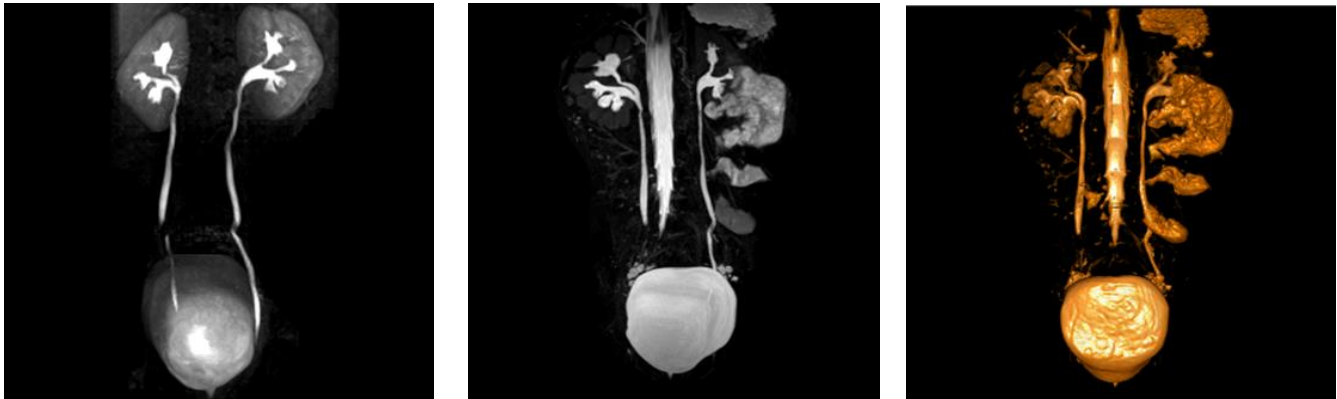


Fig. 1 MRI: bilateral duplicated collecting system (Lacramioara, 10 years old)

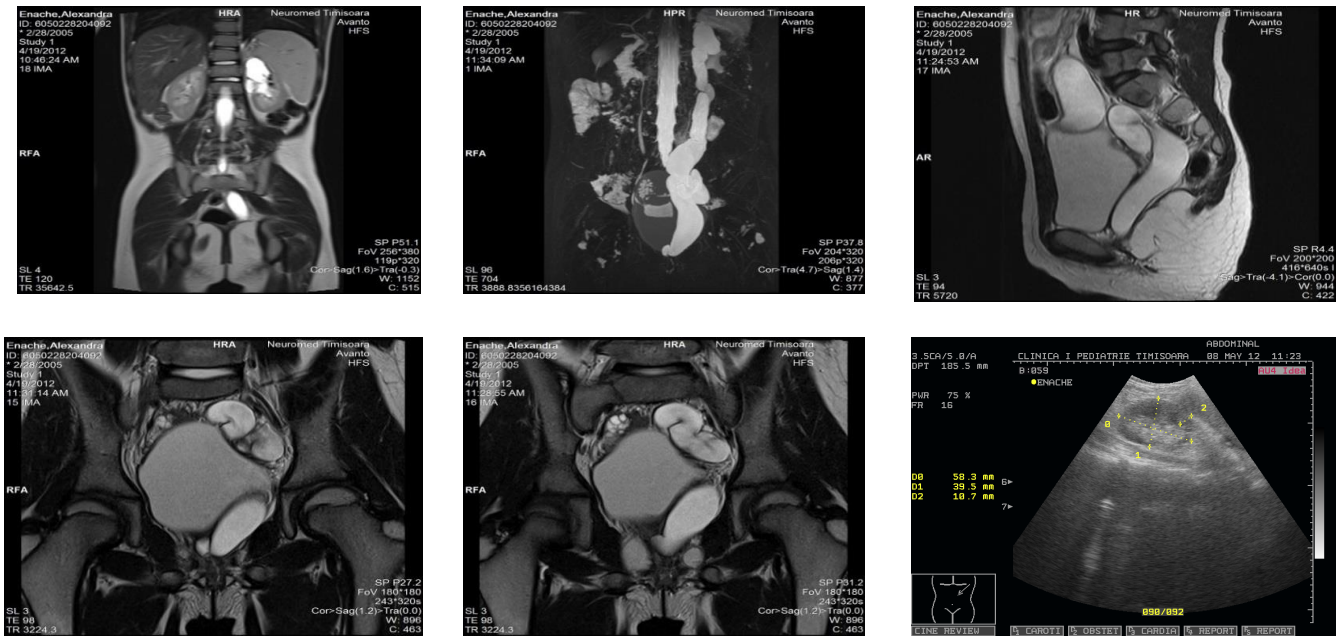


Fig.2 MRI: duplicated collecting system on the left side and the implantation of the megaureter in the urethra (Alexandra, 7 years old)

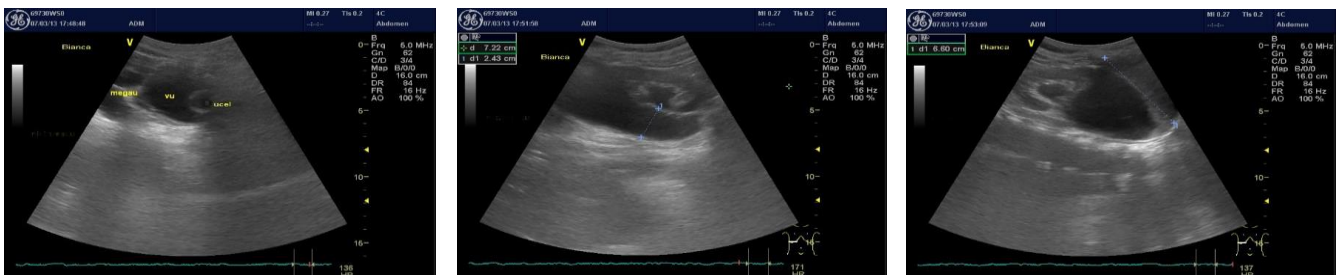


Fig.3 Abdominal ultrasound: left ureterocecal (Bianca, 1 year old)

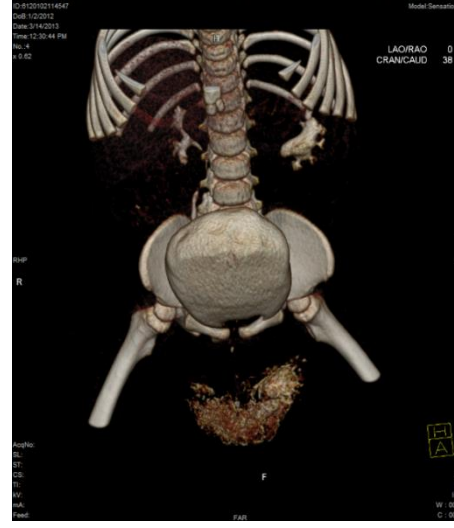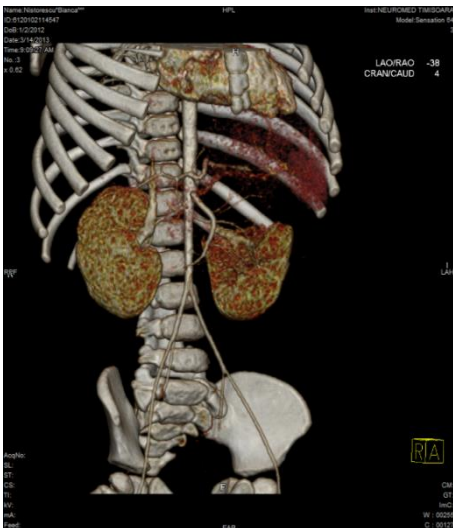
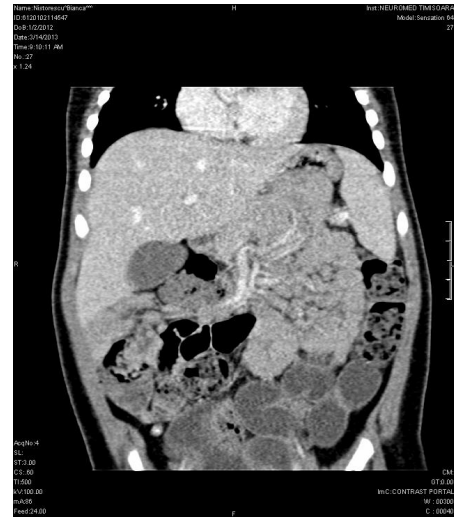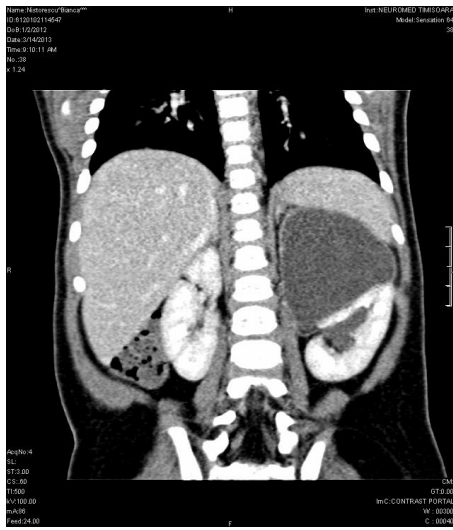


Fig.4 MRI: left duplicated collecting system (Bianca, 1 year old)

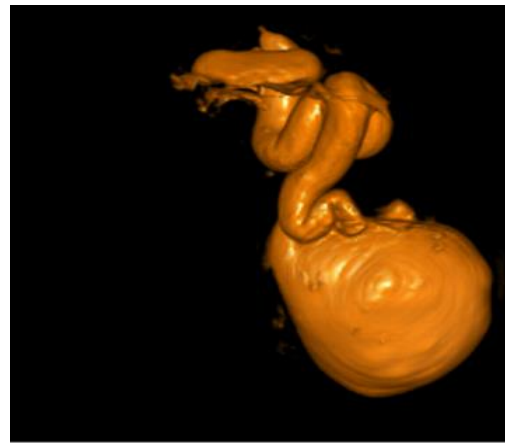
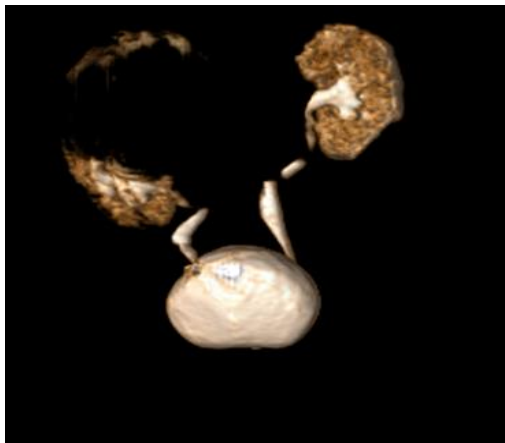


Fig.5 MRI: right duplicated collecting system (Denis, 1 month old)

The second case that of the 7 year old girl, named Alexandra, the presenting reasons are enuresis and diurnal urinary incontinence. Here as well, the MRI certifies the presence of the duplicated collecting system on the left side and the implantation of the megaureter in the urethra. Surgical correction is being performed, with the dissection and extirpation of the upper pole and of the megaureter. (Fig.2)

The third patient is a 1 year old girl, Bianca that is known from intrauterine life with a renal malformation and comes in the hospital for a bronchopneumonia. Later on, she presents for oliguria and palpebral edema, which has started a month before the actual hospitalization. She is treated with antibiotics for acute pyelonephritis, having a good outcome. Using the abdominal ultrasound, followed by a CT scan, left duplicated collecting system is diagnosed. On a further investigation, meaning a cystography, a left ureterocele is depicted, along with left megaureter and left hydronephrosis. Giving the facts, surgical correction is performed. (Fig. 3 and 4)

Our last case, a one month old baby boy, Denis, presents with sepsis and his personal history reveals repeated urinary tract infections. He is also known with hydronephrosis and megaureter from the neonate period. A complete right duplication is diagnosed at the MRI study. Due to his parent's noncompliance to the treatment, the anomaly has been eventually surgically corrected at the age of 2 years and a half. (Fig. 5)

Discussions

Giving the fact that duplicated collecting system is part of the reno urinary malformations that can be associated with other genitourinary anomalies, and also concerning the

fact that patients do address to the doctor for numerous different reasons, we would like to emphasize the importance of ultrasonography in the screening of this anomaly. But although the ultrasonography gives us significant data about the reno urinary anatomy, its reduced sensibility cannot differentiate bifid renal pelvis from complete two ureters and that is also the case when speaking about a duplex kidney and other renal masses.(5)

On the other hand, CT scanning can help to determine if there is any obstruction and very useful in assessing the renal parenchyma. CT scanning can also be used to determine if the insertion of the duplex ureter is intravesical or extravesical. It is quite clear that CT scanning is superior to ultrasonography for diagnosing duplicated collecting system and much more helpful if we are talking about a poor renal function or even an absent one.(6)

An MRI is indicated when the extravesical insertion of an ectopic ureter is in view or whenever an upper pole is suspected. Being a complex imaging study, the costs are likewise and we should have this aspect in view when thinking about performing MRI.(7)

Once the duplicated collecting system is depicted, it only remains to adjust a proper therapeutic approach.(8) In the cases that we addressed in this article, some of the patients needed surgical correction, when others remained under close medical observation.

Conclusions

The fact that a higher ureteral dilatation along with large ureter pole is the most specific ultrasound sign for complete duplicated urinary collecting system, corrective surgery in these cases is necessary.

References

1. Dalla Palma L, Bazzocchi M, Cressa C, et al. Radiological anatomy of the kidney revisited. *Br J Radiol.* Sep 1990;63(753):680-90
2. Glassberg KI, Braren V, Duckett JW, et al. Suggested terminology for duplex systems, ectopic ureters and ureteroceles. *J Urol.* Dec 1984;132(6):1153-4
3. Bruno D, Delvecchio FC, Preminger GM. Successful management of lower-pole moiety ureteropelvic junction obstruction in a partially duplicated collecting system using minimally invasive retrograde endoscopic techniques. *J Endourol.* Nov 2000;14(9):727-30
4. Avni FE, Nicaise N, Hall M, et al. The role of MR imaging for the assessment of complicated duplex kidneys in children: preliminary report. *Pediatr Radiol.* Apr 2001;31(4):215-23. Yanagisawa N, Yajima M, Takahara T, et al. Diagnostic magnetic resonance-
5. Blair D, Rigsby C, Rosenfield AT. The nubbin sign on computed tomography and sonography. *Urol Radiol.* 1987;9(3):149-51
6. Friedland GW. Large cloisons simulating duplex kidneys on CT. *AJR Am J Roentgenol.* May 1992;158(5):1171-2.
7. Jain KA. Ectopic vaginal insertion of an obstructed duplicated ureter in an adult female: demonstration by magnetic resonance imaging. *Clin Imaging.* Jan-Feb 2007;31(1):54-6.
8. Stec AA, Baradaran N, Gearhart JP. Congenital renal anomalies in patients with classic bladder exstrophy. *Urology.* Jan 2012;79(1):207-9.

Correspondance to:

Camelia Andreea Daescu,
 "Louis Turcanu" Emergency Hospital for Children
 Str Iosif Nemoianu nr 2-4 Timisoara 300011, Romania
 E-mail: camidaescu@yahoo.com