

# EXTRAPERITONEAL CEREBROSPINAL FLUID PSEUDOCYST FORMATION FOLLOWING VENTRICULOPERITONEAL SHUNT

David VL<sup>1</sup>, Emanuela Verenca<sup>1</sup>, Corina Stanculescu<sup>2</sup>, Alexandra Pelivan<sup>3</sup>, Popoiu MC<sup>1</sup>, Boia ES<sup>1</sup>

## Abstract

Hydrocephalus is the most frequently treated pathology in pediatric neurosurgery and ventriculoperitoneal (VP) shunting represents the standard of treatment for this condition. Several complications have been associated with VP shunting, such as shunt occlusion, fracture and disconnection, infection, overdrainage, shunt penetration into abdominal organs, and intraperitoneal abscess formation. We report the case of a 6 month old infant with an intra-abdominal cerebrospinal fluid (CSF) pseudocyst formation secondary to VP shunting. Prior to the development of a palpable abdominal mass which would help set suspicion of an intra-abdominal shunt complication, the patient presented general, nonspecific symptoms for a period of a few days. The intra-abdominal collection was confirmed by CT-scan and we were able to successfully treat it surgically. This kind of complication is one of the rarest following VP shunting and should be kept in mind in all children who underwent the procedure and later on present with abdominal symptoms, even in the absence of an abdominal mass.

**Key words:** Hydrocephalus, Ventriculoperitoneal Shunt, abdominal cerebrospinal fluid pseudocyst.

## Introduction

The technique of using the peritoneal cavity for cerebrospinal fluid (CSF) absorption in Ventriculoperitoneal Shunting (VPS) was developed by Kausch in 1908 (1). VPS represents the most common form of treatment for hydrocephalus, which itself is the most frequently treated condition in pediatric neurosurgery (2). It is estimated that 25–35% of patients who undergo the surgery experience at least one complication the year following the procedure. Lifetime risk of complication increases to 70-80% (1).

Most of the complications associated with VPS procedures include: shunt occlusion (accounts for up to 50% of shunt failures); shunt fracture and disconnection; infection (reported incidence of 1– 41%, average incidence of 10 – 15%); overdrainage (seen in 10% – 12% of patients and leading to complications such as slit ventricle syndrome, orthostatic hypotension, subdural fluid collections, craniosynostosis, ventricular compartmentalization, and cerebellar tonsillar herniation); and seizures (2).

The case we present is particularly interesting because the development of an abdominal cerebrospinal fluid (CSF) pseudocyst is uncommon, being encountered in < 1% of VPSs (5).

## Case report

A 6 month old male infant with occipital myelomeningocele and associated hydrocephalus for which he underwent a VPS procedure at birth, was referred to our surgical unit with a 3 day history of an enlarging abdominal mass. A week earlier, the child was admitted to the Pediatric ward in a septic state, presenting fever, agitation and refusal to eat. Improvement in the patient's condition was registered during the first days of hospital stay, though he remained febrile. The development of an abdominal mass was noticed on the 5th day of hospitalization. The mass exhibited an accelerated growth rate – from being barely palpable the first day, to reaching, on ultrasound, 8 x 10 cm the second day and 8 x 14 cm the third day (at which point it occupied the entire lower abdominal floor). This, together with a worsening in the patient's condition back to the septic state presented upon admission, has led to a surgical consult being sought, and the child was transferred into our unit.

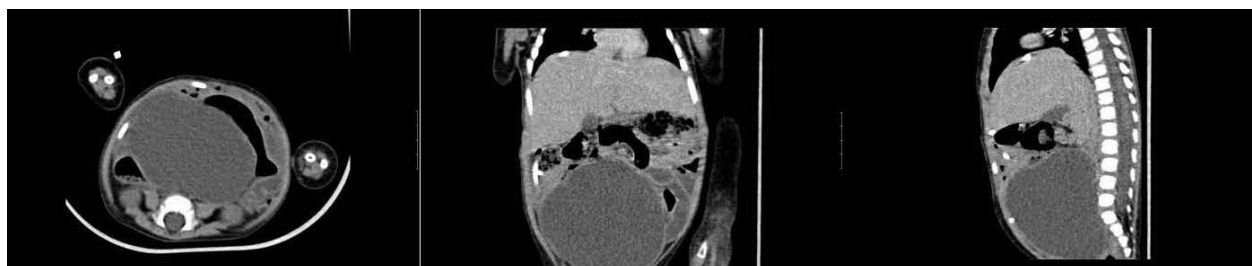
CT scan demonstrated a fluid-filled cystic mass (9.4 x 7.1 x 9 cm) with thin enhancing walls, located in the right iliac fossa (Fig. 1). An emergency exploratory laparotomy was performed and the peritoneal cyst was drained externally (about 300 ml of clear fluid was aspirated). The tip of the peritoneal catheter was found to lie within the mass (Fig. 2). The VPS was separated from the pseudocyst and the shunt was repositioned inside the peritoneal cavity, away from the lesion (Fig. 3). The patient had a favorable recovery for a period of two weeks following the procedure, which led to discontinuation of antibiotic treatment. However, the reappearance of fever and an increase in inflammatory markers raised suspicion of a VPS infection, such that about four weeks after the initial exploratory laparotomy, a complete shunt revision was carried out. Following this, the patient's condition improved.

<sup>1</sup>Department of Pediatric Surgery University of Medicine and Pharmacy "Victor Babes"

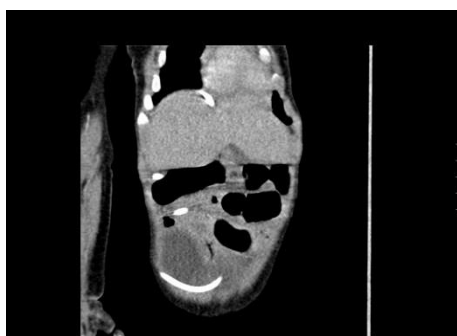<sup>2</sup>Department of Pediatric Surgery and Orthopedics, Emergency Children's Hospital "Louis Turcanu"

<sup>3</sup>County Hospital Timisoara, Romania

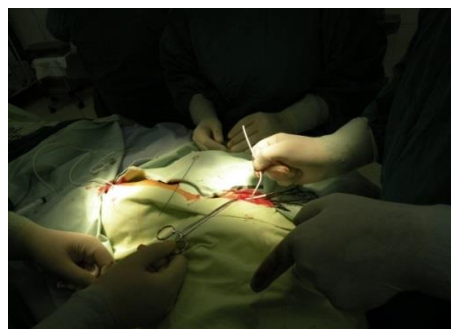E-mail:david.vlad@yahoo.com, emma\_ver@yahoo.com, corinastanculescu@yahoo.com, alexandra.pelivan@gmail.com, mcpopoiu@yahoo.com, boiaeugen@yahoo.com



**Fig. 1.** Contrast enhanced CT scan of abdomen showing a large well-defined, water-density cystic mass with



**Fig. 2.** Contrast enhanced CT scan of abdomen showing the tip of the peritoneal within the mass



**Fig. 3.** Operative photograph showing the intraperitoneal repositioning of the shunt

### Discussion

Uncommon VPS complications include subphrenic abscess; small-bowel perforation and formation of a CSF-enteric fistula; intractable CSF ascites; and migration of the shunt tip to locations such as the lateral ventricle, mediastinum, chest, gastrointestinal tract, bladder, vagina, and scrotum (4, 5).

Abdominal CSF pseudocyst development is a rare complication of VPS (< 1% of cases) (3). Most commonly, the timeframe from the shunting procedure to pseudocyst formation ranges from 3 weeks to 5 years (6). Patients with abdominal CSF pseudocyst usually present with abdominal symptoms (6); these symptoms generally precede the signs of shunt malfunction, which often makes it difficult to correlate the patients' symptoms with the presence of the VPS, thus leading to a delay in diagnosis (7). This description fits the case of our patient, who was admitted for abdominal symptoms and only displayed signs of shunt malfunctions after 5 days of hospital stay. In our patient, symptoms upon hospital admission were nonspecific and most of them pointed out solely to a VPS infection and not to the development of a CSF pseudocyst.

As employed in this case, both ultrasound and CT scan can be used in determining the diagnosis – ultrasound typically demonstrates a well-defined lucent mass with posterior acoustic enhancement, while CT scan

usually reveals a cyst containing homogenous water-density fluid (8). CT scan is, however, the imaging of choice, because it provides accurate localization of the cyst (9). However, none of the imagistic modalities can accurately provide a definitive diagnosis; moreover, in the presence of sepsis, none can distinguish between infected and noninfected cysts. Percutaneous aspiration/drainage of the pseudocyst can also be employed as a means of diagnosis; however, if infection is present, as it was in our patient, the pseudocyst should be excised and the shunt tube should be removed (8).

The direct cause that led to the formation of our patient's CSF pseudocyst is unknown. Several causes can be considered. As reported by Hahn et al., infection is the most prominent cause of pseudocyst formation (accounting for 80% of cases) and should be presumed as the cause of all abdominal pseudocysts, until proven otherwise (1). When there is an infection, the usual intra-abdominal response is peritoneal catheter sheathing; CSF draining into the sheaths can then lead to the development of CSF pseudocysts (1). Other factors that predispose to pseudocyst formation are peritoneal adhesions from a previous surgery; previous shunt revisions; increased CSF proteins; malabsorption of CSF due to conditions such as subclinical peritonitis; and an allergic reaction to the peritoneal catheter or to a CSF component (8). Of no less importance is the quality of the

shunt itself – VPSs used in hospitals from countries with small health budgets are often made of materials that retain some antigenic proprieties and can be rejected by the human body.

Overall, CSF pseudocyst formation represents a poor prognostic sign as far as the future viability of using the peritoneal cavity for shunting goes. Once a patient developed a CSF pseudocyst, it is increasingly likely that the condition will recur or that the peritoneum will suffer an inability to properly absorb the CSF (1).

### Conclusion

In spite of complications, VPS remains the method of choice for the long-term relief of increased intracranial pressure. Though uncommon, abdominal CSF pseudocyst formation should be kept in mind in all children who underwent a VPS surgery and present with abdominal symptoms, even in the absence of an abdominal mass. Clinicians managing patients with VPSs must be familiar with their possible complications, such that early recognition and prompt treatment can be implemented.

### References

1. Chung JJ, Yu JS, Kim JH, Nam SJ, Kim MJ. Intraabdominal Complications Secondary to Ventriculoperitoneal Shunts: CT Findings and Review of the Literature. *AJR Am J Roentgenol.* 2009;193:1311-7.
2. Weprin BE, Swift DM. Complications of Ventricular Shunts. *Techniques in Neurosurgery.* 2002;7:224–242.
3. Kim HB, Raghavendran K, Kleinhaus S. Management of an abdominal cerebrospinal fluid pseudocyst using laparoscopic techniques. *Surg Laparosc Endosc.* 1995;5:151-4.
4. Agha FP, Amendola MA, Shirazi KK, et al. Unusual abdominal complications of ventriculoperitoneal shunts. *Radiology.* 1983;146:323-326.
5. Agarwal T, Pandey S, Niranjan A, Jain V, Mishra S, Agarwal V. Unusual complication of ventriculoperitoneal shunt surgery. *Journal of Pediatric Neurosciences.* 2009;4:122-123.
6. Ersahin Y, Mutluer S, Tekeli G. Abdominal cerebrospinal fluid pseudocysts. *Childs Nerv Syst.* 1996;12:755-758.
7. Yamashita K, Yonekawa Y, Kawano T, Ihara I, Taki W, Kobayashi A, Handa Y, Kaku Y. Intra-abdominal Cyst Following Revision of Ventriculoperitoneal Shunt. *Neurol Med Chir (Tokyo).* 1990;30:748-52.
8. Gupta P, Ghole V, Eshaghi N. Abdominal CSF pseudocyst. *Applied Radiology.* 2009;38: 29-30.
9. Sharma AK, Pandey AK, Diyora BD, Mamidanna R, Sayal PP, Ingale HA. Abdominal CSF pseudocyst in a pateint with ventriculo- peritoneal shunt. *Indian Journal of Surgery.* 2004;66: 360-363.

Correspondance to:

Emanuela Verenca  
 University of Medicine and Pharmacy "Victor Babes"  
 2, Pta Eftimie Murgu  
 Timisoara, Romania  
 E-mail: emma\_ver@yahoo.com