

ADRENOLEUKODYSTROPHY – THE DIAGNOSTIC AND THERAPEUTIC CHALLENGES

Cristina Ghervan¹, Codruța Nemeș², Jacques Young³, Ana Valea¹, Alina Silaghi¹, Liviu Ghervan⁴

Abstract

Adrenoleukodystrophy (ALD) is a genetically determined disorder, with recessively X-linked inheritance, manifested by: progressive cerebral demyelination, primary adrenocortical failure and testicular impairment. The affected gene is *ABCD1*, which codes for a peroxisomal membrane protein implicated in the beta-oxidation of very long-chain saturated fatty acids (VLCFA). In affected patients VLCFA are accumulating within the cells, primarily in the nervous system white matter, in the adrenal cortex and in testis. Three main phenotypes of ALD are described: the childhood cerebral form (CCALD) the most severe, adrenomyeloneuropathy with adult onset (AMN) and isolated adrenal failure (Addison-only).

We present the case of a male patient diagnosed with Addison's disease at age 7, hypergonadotropic hypogonadism and AMN at age 21, showing the diagnostic and therapeutic difficulties in the context of our country. The diagnosis of ALD is based on the determination of VLCFA in plasma and is confirmed by molecular genetic testing of the *ABCD1* gene locus, both not available in Romania. Concerning the treatment, besides hormonal replacement therapy, the options in order to prevent the occurrence and progression of neurological symptoms are limited: Lorenzo's oil is used therapeutically to normalize VLCFA but its impact upon neurological disorders is largely debated; hematopoietic stem cell transplantation is shown to be beneficial in mild CCALD, but this effect was not proved for AMN; gene therapy showed good results in experimental animal studies and seems to be a promising perspective for the future, but none are at that time available in Romania.

Key words: adrenoleukodystrophy, Addison's disease, hypergonadotropic hypogonadism

Introduction

Adrenoleukodystrophy (ALD) is a genetically determined disorder, with recessively inherited X-linked inheritance, manifested mainly in male subjects, associated with progressive cerebral demyelination, primary adrenocortical failure and testicular impairment. The affected gene is *ABCD1*, which codes for a peroxisomal membrane protein (adrenoleukodystrophy protein – ALDP)

implicated in the beta-oxidation of very long-chain saturated fatty acids (VLCFA). If the enzyme is missing or not acting properly, the peroxisome dysfunction leads to the accumulation of VLCFA within the cells, primarily in the central nervous system (CNS) white matter and axons, in the adrenal cortex and in testis (1). The combined incidence of hemizygotes (all phenotypes) plus heterozygous female carriers is 1:16,800 newborns (2).

In 1923 Siemerling and Creutzfeldt reported a seven years old boy with adrenal failure due to the atrophy of the adrenal cortex and diffuse cerebral sclerosis. In 1963 an X-linked mode of inheritance was suggested, and in the mid-1970s this disease was named adrenoleukodystrophy. In 1976 the accumulation of VLCFA in the brain and adrenal cortex was reported, and in 1980, respectively in 1981 raised concentrations of VLCFA were shown in cultured skin fibroblasts and plasma. The defective peroxisomal enzyme and the responsible gene were identified in 1981 (1,3). The *ABCD1* gene is located on the long (q) arm of the X chromosome at position 28.

Three main phenotypes of ALD have been described: the childhood cerebral form (cALD) (30-35% - the most severe), adrenomyeloneuropathy (AMN) (40-46% -) and isolated adrenal failure ('Addison-only'). Other rare forms are: the adolescent and adult cerebral form (a milder phenotype of the adult) and asymptomatic forms (1).

In cerebral forms, the accumulation of VLCFA in the brain leads to inflammatory demyelination, resulting in confluent and bilaterally symmetric loss of myelin, the parieto-occipital regions being usually affected first, with asymmetric progression of the lesions toward the frontal or temporal lobes. Children with the cerebral form of ALD experience learning and behavioral problems that usually begin between the ages of 4 and 10.

Over time the symptoms worsen, and these children may have difficulty reading, writing, understanding speech, and comprehending written material. Additional signs and symptoms of the cerebral form include aggressive behavior, vision problems, difficulty swallowing, poor coordination, and impaired adrenal gland function.

¹Endocrinology Department, County Clinical Emergency Hospital Cluj-Napoca.

²Endocrinology Outpatient Facility, County Emergency Hospital Satu-Mare.

³Service d'Endocrinologie et Maladies de la Reproduction, Hôpital Bicêtre (Paris).

⁴Urology and Renal Transplantation Institute Cluj-Napoca.

E-mail: cghervan@yahoo.com, neagu_codruta@yahoo.com, jacques.young@wanadoo.fr, ana74us@yahoo.com, alinasilaghi@yahoo.com, liviughervan@yahoo.com

The rate at which this disorder progresses is variable but can be extremely rapid, often leading to total disability within a few years. The life expectancy of individuals with this type depends on the severity of the signs and symptoms and how quickly the disorder progresses, usually surviving only a few years after symptoms begin.

Adrenomyeloneuropathy (AMN) affects mainly the long tracts of the spinal cord; the affected individuals developing a degenerative axonopathy (4). Signs and symptoms appear between early adulthood and middle age. Affected individuals develop progressive stiffness and weakness in their legs (paraparesis), experience urinary and genital tract disorders, and often show changes in behavior and thinking ability. Most people with AMN also have adrenocortical insufficiency. In some severely affected individuals, damage to the brain and nervous system can lead to early death.

People with ALD whose only symptom is adrenocortical insufficiency are said to have the *Addison disease only form* (about 10% of cases). In these individuals, adrenocortical insufficiency can begin anytime between childhood and adulthood. However, most affected individuals develop the additional features of the AMN by the time they reach middle age. The life expectancy of individuals with this form depends on the severity of the signs and symptoms, but typically this is the mildest of the three types.

Adrenal insufficiency is also present in over 70% of cerebral or AMN forms. Although ALD is a rare cause of adrenal failure, *it is the most common cause of Addison's disease in young men* (5,6,7).

Rarely, individuals with X-linked ALD develop multiple features of the disorder in adolescence or early adulthood. In addition to adrenocortical insufficiency, these individuals usually have psychiatric disorders and a loss of intellectual function (dementia). It is unclear whether these individuals have a distinct form of the condition or a variation of one of the previously described types. For reasons that are unclear, different forms of X-linked ALD can be seen in affected individuals within the same family, harboring the same mutation.

Primary hypogonadism is also affecting the patients with ALD. The accumulation of VLCFA within the testis determine: hypocellularity and mild vacuolation of seminiferous tubules, and interstitial damage – i.e. focal fibrosis, near hyalinized tubules and reduction of the number of Leydig cell clusters per seminiferous tubule (8,9).

The diagnosis of ALD is based on the determination of VLCFA in plasma and is confirmed by molecular genetic testing of the *ABCD1* gene locus (6). Unfortunately there is still no effective treatment or strategy to predict the evolution of the disease (10).

We describe a case of adrenoleukodystrophy in a 21 years old young man, known with idiopathic Addison's disease by the age of 7, associated at the moment of diagnosis with hypogonadism, short stature, without neurological signs.

Case report

A 21 years old male patient was admitted in the emergency unit (ER) in August 2011 for asthenia, weakness, dizziness, nausea, vomiting, abdominal pain, salt craving, dyspnea, facial pallor and cold sensitivity; the symptoms occurring suddenly after sustained physical effort and sun exposure. The patient was diagnosed at the age of 7 with primary adrenal insufficiency and treated with glucocorticoid and mineralocorticoid substitution (prednisone and fludrocortisone) until 2007 when the treatment was discontinued by the pediatrician. In the presence of hyponatremia (124 mEq/l), hyperkalemia (6 mEq/l), metabolic acidosis (pH=7,3), leukocytosis (10800/mm³), uremia (blood urea nitrogen = 52 mg/dl) and rhabdomyolysis (TGO = 54U/L, CPK = 727U/L) adrenal crisis was diagnosed, subsequently confirmed by the low levels of cortisol: 8:00am = 20.9 nmol/l (n.r. 171-536) and 8:00pm = 12,4 nmol/l (n.r. 64-340), measured before ER admission. After the emergency treatment with hydrocortisone hemisuccinate i.v, rehydration and correction of electrolytes and acid-base imbalance, the patient was transferred in the Endocrinology department.

The clinical features at admission in our service are summarized in Table I and the laboratory and imaging tests in Table II.

Table I. Clinical examination performed at the admission in our unit.

Clinical examination
<ul style="list-style-type: none"> • Severe asthenia, • Hypothermia (<35°C), cold skin. • Height = 153 cm (-3,5 DS below the mean) • Proportionate somatic development (arm span to height ratio = 0,98, the upper segment to lower segment ratio = 0,96) • Weight = 43 Kg, underweight (body mass index (BMI) of 18,36 kg/m²), • Facial pallor • Generalized hyperpigmentation of the skin, increased in sun-exposed areas and over pressure areas (elbows and knees). • Supine blood pressure = 90/60 mmHg, orthostatic blood pressure = 80/60 mmHg, heart rate = 90 bpm; • Reduced facial hair growth, reduced axillar and pubic hair – stage Tanner III, right testicular volume = 12 ml, left testicular volume = 11 ml, penile length = 8 cm;

Table II. Laboratory tests and imaging.

Examination	Results	Observations/Interpretations																
Laboratory tests	8 AM serum cortisol = 448,6 ng/dl (75-225)	Considering the ER treatment with hydrocortisone, the low values of cortisol measured before the ER admission and the pre-existing diagnosis of Addison's disease, we didn't complete the investigations with plasma ACTH level and the stimulation testing with 100µg Synacthen.																
	Electrolytes: Na ⁺ = 138 mmol/l, K ⁺ = 5.23 mmol/l	Mineralocorticoid deficiency																
	DHEAS = 0,22 µg/ml (1-4,2)	Adrenal androgen deficiency																
	FSH = 8,17 U/l (1-10,5), LH = 11,4 U/L (1-5,8), Testosterone = 2,06 ng/ml (2,5-10) (initial values) <u>Stimulation test with 100 µg Diphereline s.c:</u> <table border="1" style="margin-left: auto; margin-right: auto;"> <tr> <td></td> <td>Bazal</td> <td>4 h</td> <td>24 h</td> </tr> <tr> <td>FSH (U/l)</td> <td>38,5</td> <td>41,1</td> <td>30,4</td> </tr> <tr> <td>LH (U/l)</td> <td>35,2</td> <td>67,1</td> <td>47,2</td> </tr> <tr> <td>Testosterone</td> <td>1,58</td> <td>2,04</td> <td>2,03 (ng/ml)</td> </tr> </table>		Bazal	4 h	24 h	FSH (U/l)	38,5	41,1	30,4	LH (U/l)	35,2	67,1	47,2	Testosterone	1,58	2,04	2,03 (ng/ml)	Primary hypogonadism.
	Bazal	4 h	24 h															
FSH (U/l)	38,5	41,1	30,4															
LH (U/l)	35,2	67,1	47,2															
Testosterone	1,58	2,04	2,03 (ng/ml)															
	IGF1 = 88,6 ng/ml (116-368)	Previous normal values of IGF1 and basal and stimulated GH excluded GH deficiency. The punctual low level of IGF1 was interpreted as reaction to the distress of the adrenal crisis.																
	PRL = 23,7 ng/ml (2-12)	The mild elevated PRL was interpreted as reaction to the distress of the adrenal crisis.																
	TSH = 5,65 µU/ml (0,5-4) FT4 = 1,30 ng/dl (0,8-1,4) ATPO - negative	The slight elevation of TSH with normal FT4, negative ATPO and normal sonography was interpreted as reaction to the distress of the adrenal crisis "thyroid sick syndrome".																
Thyroid sonography	Normal thyroid volume and structure																	
Native adrenal CT-scan	<i>Very small adrenals</i> , difficult to individualize, measuring only 3-4 mm.	Adrenal atrophy																
Immunology	Antiadrenal antibodies – negative	Autoimmune etiology is excluded																
Pituitary MRI and FLAIR sections for brain	No pituitary injuries; Multiple demyelination areas in the subcortical white matter of frontal lobes, adjacent to the body of right lateral ventricle and genu of the corpus callosum	Demyelinating disease																
Radiographs of the left hand and the knees.	The growth cartilages <i>are closed</i> ; The bone age corresponds to the chronological age.	Post-pubertal onset of hypogonadism.																

The association between adrenal failure, cerebral demyelination areas and hypogonadism raise suspicion of adrenoleukodystrophy, and the patient was transferred in the Neurology Department for etiologic and differential

diagnosis of the demyelinating lesions: the tests performed are described in Table III.

Table III. Neurologic evaluation.

Examinations	Results
Neurological physical examination	Without neurological signs excepting a <i>slightly increased reflexes</i> .
Laboratory tests	
- Immunology	- IgA, IgG, IgM, CRP – normal values - ANA negative - CIC = $200 \text{ U} \times 10^{-3}$ (<150), - IgG Borellia - negative - IgM Borellia - reactive
- Spinal fluid	- total protein = 76mg/dl (<50) - positive Pandy reaction - normal glucose and IgG - bacteriological and immunological examinations without abnormalities
Psychological examination	- normal intellect - MMSE: 30 points of 30 - personality examination revealed no psychopathological elements
Electro-neurography	- motor axonal polyneuropathy

Other causes for the demyelinating lesions being excluded, the probable diagnosis was ADL “Addison only form” but the confirmation needed the dosage of VLCFA, or the identification of the mutation of the *ABCD1* gene, both not available at the time in our country.

The patient was prescribed chronic replacement therapy: prednisone 7,5 mg/day, fludrocortisone 0,1 mg/day and testosterone undecanoate 40 mg/day (80 mg/day starting the second year). B-complex vitamins were prescribed in order to prevent further evolution of the demyelinating lesions and of axonal polyneuropathy. Lorenzo’s oil, a specific treatment of ALD is not available in our country.

The clinical evolution with substitution therapy was very good, with weight gain, disappearance of fatigue, appetite normalization, normalization of testosterone level and progression of secondary sexual characteristics. The MRI evaluations in the next two years, showed a stationary size of the demyelinating lesions in the frontal lobes (Figure 1), but with intense gadolinium enhancement of the rim of the lesions from the rostrum and the genu of the corpus callosum, meaning active lesions (Figure 2). Despite this aspect, the patient is still neurologically asymptomatic.

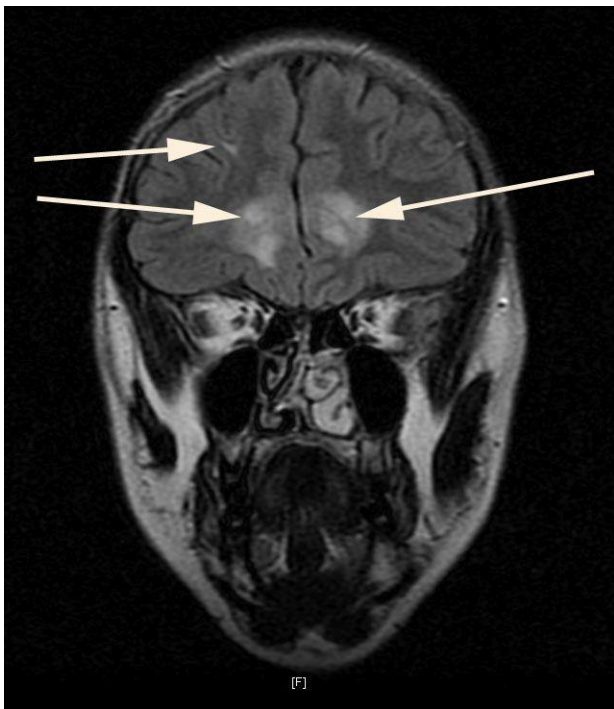


Fig. 1. MRI coronal section FLAIR showing demyelinating lesions (arrows).

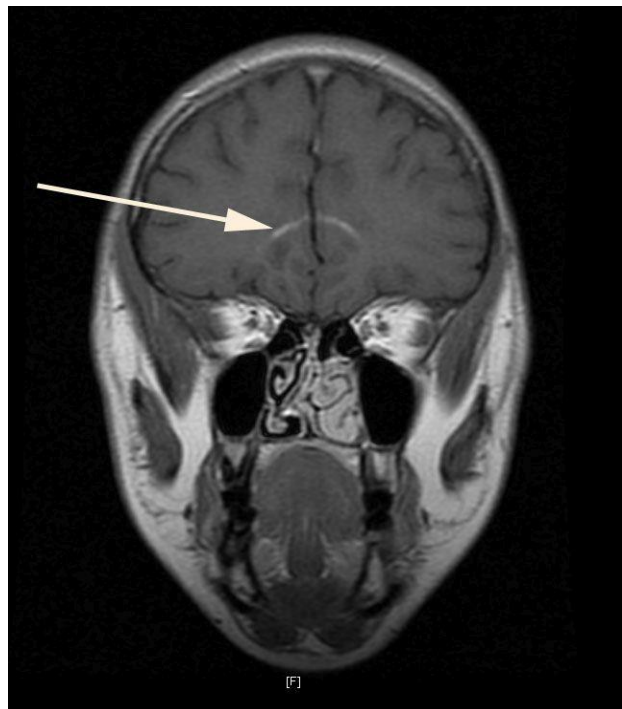


Fig. 2. MRI coronal section with gadolinium contrast showing marginal enhancement of the demyelinating lesions (arrow).

After two years, with the generous contribution of Prof. Jacques Young, Service d'Endocrinologie et Maladies de la Reproduction, Hopital Bicetre (Paris) and the contribution of the "Centre de Genetique Moleculaire et Chromosomique" Hopital Saint Vincent de Paul (Paris) the molecular genetic testing of the *ABCD1* gene locus showed that the patient is hemizygous for the mutation c.521A>G (p.Tyr174Cys), in exon 1, finally confirming the diagnosis of Adrenoleukodystrophy.

Discussions

Despite Addison's disease onset was at the age of 7, its etiology was never investigated. Moreover, at the age of 17 the substitution therapy was completely stopped by the pediatrician who said at that time that the illness was cured...

Adrenal failure is present in 90% of the boys and in 65% of the adults with ALD; it may precede, it can be concurrent or it can follow neurological signs. Desloques *et al.* reported a case of a young man diagnosed with cerebral ALD at the age of 29 who had been diagnosed with Addison's disease at the age of 8. The longest time reported between the diagnosis of Addison's disease and neurological manifestations in ALD is 32 years (11). Sydney *et al.* have published another case of idiopathic Addison's disease diagnosed at the age of 10 who eventually developed AMN at the age of 24 (12). Another study found that out of eight males with childhood-onset Addison's disease and no signs or symptoms of neurologic dysfunction; five had the biochemical defect of ALD and clear evidence by MRI examination of ALD involving the brain (13). These cases show that when Addison's disease is diagnosed in a young man, apparently without neurological signs, it still may be considered a manifestation of ALD.

In our case the patient had no neurological complaints at the time of presentation, the neurological examination revealed only slightly increased reflexes and the ENG examination noted motor axonal polyneuropathy. We interpreted the case as „Addison-only” that lately developed cerebral lesions. However, as shown, the risk of developing neurological manifestations in the “Addison-only” form is very high (3,6).

Long-term analysis of "Addison only" forms showed that all patients, who survive over adulthood will in the end develop AMN (1). The presence of motor axonal polyneuropathy may be the evidence of this evolution. If polyneuropathy is investigated, an axonopathy is found in the majority of the AMN patients, but this is rarely the initial symptomatology (14). The average age of developing neurological manifestations (spasticity and weakness of the legs, sphincter and sexual dysfunction) in AMN is 27,6 years. About 50% to 60% of AMN patients show subtle neuropsychological abnormalities, with the pattern of subcortical dementia (15).

In our patient, considering the presence of brain active demyelinating lesions on MRI, it may be an AMN with cerebral involvement. As shown, approximately 40%-45% of individuals with AMN show some degree of brain involvement on MRI or during clinical examination, but only in 10%-20% of them the brain involvement becomes

severely progressive and leads to serious cognitive and behavioral disturbances that may progress to total disability and death (6). Although patients with AMN generally do not have clinical signs of brain involvement, up to 50% of them have MRI evidence of cerebral demyelination (16) and about one-third of them develop a rapid progressive cerebral form similar to that seen in CCALD form (17). When cerebral demyelination occurs in adolescence or adulthood, the initial progression of symptoms is usually slower. The rapid neurologic decline, seen in the cerebral forms, is caused by a severe inflammatory demyelination process. Though, 10% of males with cerebral ALD or AMN with cerebral involvement may not reach this stage. The cerebral demyelinating process arrests spontaneously and the patient can remain stable for a decade or even longer. But even after a 10 –15 years period of stability, sudden onset of rapid neurologic deterioration may occur. Once the cerebral demyelinating lesions have entered the active phase, with gadolinium enhancement, the prognosis is poor (14). In our patient, despite the “active phase aspect” of the lesions from the rostrum and the genu of the corpus callosum in MRI, the neurologic signs are still lacking.

In 85% of the cerebral ALD cases the demyelinating lesions occur in the bilateral occipito-parietal regions. In this case the demyelinating lesions are located in the frontal lobes, adjacent to the body of the right lateral ventricle and the genu of the corpus callosum. This version is seen in about 15% of the cases (1,15,18). Because of this particular location, the differential diagnosis with other demyelinating diseases was needed and it was predominantly based on neurological and cerebrospinal fluid examination. The suggestive changes of multiple sclerosis (moderate pleocytosis, discrete increase of protein level, increased amount of IgG) and of Lyme disease (moderate lymphocytic pleocytosis, increased protein level (1-3 g/l), normal or low glucose) weren't observed in our patient. Despite the reactive IgM for Borellia at ELISA testing, due to the absence of the symptoms and of the specific cerebrospinal fluid changes, the neuroborreliosis was excluded. The result was interpreted as being false positive considering that ELISA IgM anti Borellia can be positive in a variety of other diseases, including neurological ones (19,20,21,22).

Although the determination of VLCFA wasn't possible, the genetic testing confirmed the diagnosis of adrenoleukodystrophy. It is well known that there is no genotype-phenotype correlation and also that all clinical phenotypes arise from identical mutations [23]. The mutation found in our patient, c521A>G (pTyr174Cys), was described many times before, including one case of “Addison-only” (24), one Chinese (25) and one Japanese (26) patient with childhood cerebral ALD and in a large Arab family with ALD (27). This mutation, located in the exon 1 of the *ABCD1* gene leads to the absence of ALDP in fibroblasts as indicated by immunofluorescence and /or immunoblotting.

The association of primary adrenal failure with hypogonadism raised also the suspicion of DAX1 mutation, even more with the initial normal value of FSH and only slightly increases of LH. Another hypothesis was adrenal

enzyme deficiency - partial StAR protein deficiency, which affects steroid hormone producing cells and is manifested by lipid adrenal hyperplasia, and adrenal and gonadal failure. Therefore, we decided to complete the investigations with adrenal CT scan and brain/pituitary MRI and the hormonal profile with the stimulation test with 100 µg Diphereline. Abdominal CT showed adrenal atrophy, the Diphereline test showed hypergonadotropic hypogonadism and the MRI showed demyelinating lesions of the brain, excluding these etiologies. The initial normal values of gonadotropins were subsequently interpreted as being due to the administration of hydrocortisone succinate for the treatment of Addison crisis (the excess of glucocorticoids inhibits the release of gonadotropins) (29). We also excluded hemochromatosis and the most common etiology of Addison's disease – the autoimmune disease.

The scarce secondary sexual characteristics, with testicular development and closure of growth cartilages, without bone age retardation, lead to the idea that hypogonadism occurred after a partial puberty.

The testicular impairment is present in 77-80% of ALD patients (8,9). The accumulation of striated material (lipid accumulation), that leads to atrophy and death of the cells is seen in: adrenal cells, Schwann cells, brain macrophages and testicular interstitial cells (30). The testicular histological changes, described by Powers and Schaumburg since 1981, consist in hypo cellularity, vacuolization of seminiferous tubules, hyalinization of tubules and reduced number of Leydig cells (31).

We also revealed a slightly increased TSH, with normal free T4 and a normal thyroid gland in ultrasound examination. These elements were also mentioned to by Aversa *et al.* and interpreted like "euthyroid sick syndrome" (32). The short stature is another simultaneous element. The low value of IGF1 corresponding to sex and age, in the presence of normal basal and after stimulation GH levels, was interpreted as being appropriate to pubertal stage.

Concerning the treatment, besides glucocorticoid, mineralocorticoid and androgen replacement therapy, the options in order to prevent the occurrence and progression of neurological symptoms are limited.

Lorenzo's oil, a combination of 4/1 mix of erucic acid and oleic acid, is used therapeutically to normalize VLCFA levels. The daily doses are 20% of the caloric needs. Several studies have shown that, despite Lorenzo's Oil reduces and even normalizes plasma levels of VLCFA, it doesn't prevent progression of brain demyelinating lesions in cerebral forms (33,34,35,36). Regarding the patients with AMN, there is some evidence that this therapy stabilizes or even improves neurological disorders (35), but other studies have shown the inefficiency of the treatment, with clinical deterioration and progression (36,37,38). Lorenzo's Oil isn't available in Romania, but certain oils used in cooking, such as *mustard seed oil*, have naturally high levels of erucic acid and thus can lead to a decrease in VLCFA similar to that observed with Lorenzo's oil therapy.

Hematopoietic stem cell transplantation is shown to be beneficial in CCALD, for asymptomatic or mild

symptomatic patients, but this effect was not proved for AMN or adult cerebral ALD patients. The data showed that hematopoietic stem cell transplantation performed at an advanced stage of the cerebral ALD would accelerate the progression of the disease; good clinical outcome is achieved only when hematopoietic stem cell transplantation is performed at the very early stage of the disease. Immunomodulatory and immunosuppressive therapies were proved ineffective. Valproic acid may be beneficial in patients with AMN; other therapies under trial are: 4 phenylbutyrate and antioxidants (14,39).

Gene therapy showed experimental promising results in animal studies. Gong group used recombinant adeno-associated virus serotype 9 (rAAV9) vector for delivery of the human *ABCD1* gene to mouse central nervous system (CNS). In vitro, efficient delivery of *ABCD1* gene was achieved in primary mixed brain glial cells from *Abcd1*^{-/-} mice as well as X-ALD patient fibroblasts. Importantly, human *ABCD1* localized to the peroxisome, and AAV-*ABCD1* transduction showed a dose-dependent effect in reducing VLCFA. In vivo, AAV9-*ABCD1* was delivered to *Abcd1*^{-/-} mouse CNS by either stereotactic intracerebroventricular (ICV) or intravenous (IV) injections. Astrocytes, microglia and neurons were the major target cell types following ICV injection, while IV injection also delivered to microvascular endothelial cells and oligodendrocytes. IV injection also yielded high transduction of the adrenal gland. Importantly, IV injection of AAV9-*ABCD1* reduced VLCFA in mouse brain and spinal cord. They conclude that AAV9-mediated *ABCD1* gene transfer is able to reach target cells in the nervous system and adrenal gland as well as reduce VLCFA in culture and a mouse model of X-ALD (40).

Conclusions

Adrenoleukodystrophy is a rare disease and is certainly underdiagnosed due to multiple phenotypes, in which the diagnosis is often delayed, especially if the adrenal failure precedes the neurological symptoms. Thus, we support the importance of ALD testing, especially for the male patients diagnosed with idiopathic Addison's disease in childhood. At least the dosage of VLCFA must be available and reimbursed by the medical insurance system.

Particular aspects of the case are:

- The association of primary adrenal insufficiency with hypogonadism and short stature that made necessary the differential diagnosis with other etiologies such as: DAX1 mutation, adrenal enzyme deficiency (partial deficiency of STaR protein) and pituitary failure;

- The atypical localization of the demyelinating lesions that required differential diagnosis with other causes of CNS demyelinating diseases, like multiple sclerosis and Lyme disease;

- The lack of neurological symptoms, despite the presence of the active demyelinating lesions of the cerebral white matter.

The major concern for the future is the evolution of the neurological lesions, even more since the therapeutic possibilities in our country are so limited.

References

1. Hugo WM. Adrenoleukodystrophy: phenotype, genetics, pathogenesis and therapy. *Brain*, 1997 Aug;120 (Pt 8):1485-1508.
2. Bezman L., Moser H.W. Incidence of X-linked adrenoleukodystrophy and the relative frequency of its phenotypes. *Am. J. Med. Genet.* 1998;76:415–419.
3. van Geel BM, Assies J, Wanders RJ, Barth PG. X linked adrenoleukodystrophy: clinical presentation, diagnosis, and therapy. *J Neurol Neurosurg Psychiatry*, 1997 Jul;63(1):4-14.
4. Powers JM, DeCiero DP, Ito M, Moser AB, Moser HW. Adrenomyeloneuropathy: a neuropathologic review featuring its noninflammatory myelopathy. *J Neuropathol Exp Neurol* 2000; 59(2):89-102.
5. Laureti S, Casucci G, Santeusanio F, Angeletti G, Aubourg P, Brunetti P. X-linked adrenoleukodystrophy is a frequent cause of idiopathic Addison's disease in young adult male patients. *J Clin Endocrinol Metab*, 1996 Feb;81(2):470-474.
6. Moser AB, Steinberg SJ, Raymond GV. X-Linked Adrenoleukodystrophy. In: Pagon RA, Bird TD, Dolan CR, Stephens K, editors. *GeneReviews* [Internet]. Seattle (WA): University of Washington, Seattle; 1993-1999 Mar 26 [updated 2009 Jun 02].
7. Ronghe MD, Barton J, Jardine PE, Crowne EC, Webster MH, Armitage M, Allen JT, Steward CG. The importance of testing for adrenoleukodystrophy in males with idiopathic Addison's disease. *Arch Dis Child*, 2002 Mar;86(3):185-189.
8. Brennemann W, Köhler W, Zierz S, Klingmüller D. Testicular dysfunction in adrenomyeloneuropathy. *Eur J Endocrinol*, 1997 Jul;137(1):34-39.
9. Assies J, Gooren LJ, Van Geel B, Barth PG. Signs of testicular insufficiency in adrenomyeloneuropathy and neurologically asymptomatic X-linked adrenoleukodystrophy: a retrospective study. *Int J Androl*, 1997 Oct;20(5):315-321.
10. TerreBlanche G, van der Walt MM, Bergh JJ, Mienie LJ. Treatment of an adrenomyeloneuropathy patient with Lorenzo's oil and supplementation with docosahexaenoic acid-A case report. *Lipids Health Dis*, 2011 Aug 26;10:152.
11. Desloques L, Januel AC, Mejdoubi M, Catalaa I, Pariente J, Cognard C. [X-linked adult onset adrenoleukodystrophy. A case report]. *J Neuroradiol*, 2006 Jun;33(3):201-215.
12. Westphal SA. Adrenomyeloneuropathy presenting in adulthood. *West J Med*, 1998 Jan;168(1):45-47.
13. Sadeghi-Nejad A, Senior B. Adrenomyeloneuropathy presenting as Addison's disease in childhood. *N Engl J Med*, 1990; 322:13-16.
14. Engelen M, Kemp S, de Visser M, van Geel BM, Wanders RJ, Aubourg P, Poll-The BT. X-linked adrenoleukodystrophy (X-ALD): clinical presentation and guidelines for diagnosis, follow-up and management. *Orphanet J Rare Dis*. 2012 Aug 13;7:51
15. Kumar AJ, Köhler W, Kruse B, Naidu S, Bergin A, Edwin D, Moser HW. MR findings in adult-onset adrenoleukodystrophy. *AJNR Am J Neuroradiol*. 1995 Jun-Jul;16(6):1227-1237.
16. Spurek M, Taylor-Gjevre R, Van Uum S, Khandwala HM. Adrenomyeloneuropathy as a cause of primary adrenal insufficiency and spastic paraparesis. *CMAJ*, 2004 Oct 26;171(9):1073-1077.
17. Ferrer I, Aubourg P, Pujol A. General aspects and neuropathology of X-linked adrenoleukodystrophy. *Brain Pathol*. 2010 Jul;20(4):817-830
18. Castellote A, Vera J, Vazquez E, Roig M, Belmonte JA, Rovira A. MR in adrenoleukodystrophy: atypical presentation as bilateral frontal demyelination. *AJNR Am J Neuroradiol*, 1995 Apr;16(4 Suppl):814-815.
19. Bratton RL, Whiteside JW, Hovan MJ, Engle RL, Edwards FD. Diagnosis and treatment of Lyme disease. *Mayo Clin Proc*, 2008;83:566–571.
20. Hildenbranda P, Cravenb DE, Jonesc R, Nemeskald P. Lyme Neuroborreliosis: Manifestations of a Rapidly Emerging Zoonosis. *AJNR*, June 2009; 30:1079-1087.
21. Lana-Peixoto MA. Multiple sclerosis and positive Lyme serology. *Arq Neuropsiquiatr* 1994;52(4):566-571
22. Luque FA, Jaffe SL. Cerebrospinal fluid analysis in multiple sclerosis. *Int Rev Neurobiol*. 2007;79:341-356
23. Smith KD, Kemp S, Braiterman LT, Lu J-F, Wei H-M, Geraghty M, Stetten G, Bergin JS, Pevsner J, Watkins PA. X-linked adrenoleukodystrophy: genes, mutations, and phenotypes. *Neurochem Res*.1999;24:511–525.
24. Lachtermacher MB, Seuánez HN, Moser AB, Moser HW, Smith KD. Determination of 30 X-linked adrenoleukodystrophy mutations, including 15 not previously described. *Hum Mutat*. 2000;15(4):348-353
25. Lan F, Wang Z, Xie H, Huang L, Ke L, Yang B, Zhu Z. Molecular diagnosis of X-linked adrenoleukodystrophy: experience from a clinical genetic laboratory in mainland China with report of 13 novel mutations. *Clin Chim Acta*. 2011 May 12;412(11-12):970-974
26. Shimozawa N, Honda A, Kajiwara N, Kozawa S, Nagase T, Takemoto Y, Suzuki Y. X-linked adrenoleukodystrophy: diagnostic and follow-up system in Japan. *J Hum Genet*. 2011 Feb;56(2):106-109.
27. Neumann S, Topper A, Mandel H, Shapira I, Golan O, Gazit E, Loewenthal R. Identification of new mutations in Israeli patients with X-linked adrenoleukodystrophy. *Genet Test*. 2001 Spring;5(1):65-68.
28. Korenke GC, Roth C, Krasemann E, Hüfner M, Hunneman DH, Hanefeld F. Variability of endocrinological dysfunction in 55 patients with X-linked adrenoleukodystrophy: clinical, laboratory and genetic findings. *Eur J Endocrinol*,1997 Jul;137(1):40-47.
29. Aron DC, Findling JW, Tyrrell JB. Glucocorticoids & Adrenal Androgens. In: Gardner DG, Shoback D, eds. *Greenspan's Basic & Clinical Endocrinology* 8th edition. US: The McGraw-Hill Companies, 2007:346-395.

30. Powers JM, Schaumburg HH. Adreno-leukodystrophy (sex-linked Schilder's disease). A pathogenetic hypothesis based on ultrastructural lesions in adrenal cortex, peripheral nerve and testis. *Am J Pathol*, 1974 Sep;76(3):481-491.
31. Powers JM, Schaumburg HH. The testis in adreno-leukodystrophy. *Am J Pathol*, 1981 Jan;102(1):90-98.
32. Aversa A, Palleschi S, Cruccu G, Silvestroni L, Isidori A, Fabbri A. Rapid decline of fertility in a case of adrenoleukodystrophy. *Hum Reprod*, 1998 Sep;13(9):2474-2479.
33. Rizzo WB, Leshner RT, Odone A, Dammann AL, Craft DA, Jensen ME, Jennings SS, Davis S, Jaitly R, Sgro JA. Dietary erucic acid therapy for X-linked adrenoleukodystrophy. *Neurology*, 1989 Nov;39(11):1415-1422.
34. Uziel G, Bertini E, Bardelli P, Rimoldi M, Gambetti M. Experience on therapy of adrenoleukodystrophy and adrenomyeloneuropathy. *DevNeurosci*, 1991;13 (4-5):274-279.
35. Asano J, Suzuki Y, Yajima S, Inoue K, Shimozawa N, Kondo N, Murase M, Orii T. Effects of erucic acid therapy on Japanese patients with X-linked adrenoleukodystrophy. *Brain Dev*, 1994 Nov-Dec;16(6):454-458.
36. Korenke GC, Hunneman DH, Kohler J, Stöckler S, Landmark K, Hanefeld F. Glyceroltrioleate /glyceroltrierucate therapy in 16 patients with X chromosomal adrenoleukodystrophy /adrenomyeloneuropathy: effect on clinical, biochemical and neurophysiological parameters. *Eur J Pediatr*, 1995;154:64–70.
37. Aubourg P, Adamsbaum C, Lavallard-Rousseau MC, Rocchiccioli F, Cartier N, Jambaque I, Jakobezak C, Lemaitre A, Boureau F, Wolf C, Bougneres PF. A 2 year trial of oleic and erucic acids (Lorenzo's oil) as treatment for adrenomyeloneuropathy. *N Engl J Med*, 1993; 329:745–752.
38. van Geel BM, Assies J, Haverkort EB, Koelman JH, Verbeeten B Jr, Wanders RJ, Barth PG. Progression of abnormalities in adrenomyeloneuropathy and neurologically asymptomatic X-linked adrenoleukodystrophy despite treatment with "Lorenzo's oil". *J Neurol Neurosurg Psychiatry*, 1999 Sep;67(3):290-299.
39. Berger J, Pujol A, Aubourg P, Forss-Petter S. Current and future pharmacological treatment strategies in X-linked adrenoleukodystrophy. *Brain Pathol*, 2010 Jul;20(4):845-856.
40. Gong Y, Mu D, Prabhakar S, Moser A, Musolino P, Ren J, Breakefield XO, Maguire CA, Eichler FS. Adeno-associated virus serotype 9-mediated gene therapy for X-linked Adrenoleukodystrophy (X-ALD). *Mol Ther*. 2015, 23(5):824-834.
41. Jiang MY1, Cai YN, Liang CL, Peng MZ, Sheng HY, Fan LP, Lin RZ, Jiang H, Huang Y, Liu L. Clinical, biochemical, neuroimaging and molecular findings of X-linked Adrenoleukodystrophy patients in South China. *Metab Brain Dis*. 2015 Aug 12. [Epub ahead of print]

Correspondence to:

Associate Professor Cristina Ghervan, MD, PhD.
 Department of Endocrinology,
 University of Medicine and Pharmacy "Iuliu Hatieganu"
 3-5 Pasteur street, Cluj-Napoca, Romania
 Tel: 0744398417
 E-mail: cghervan@yahoo.com