

ORBITAL COMPLICATIONS OF RHINOSINUSITIS

Balica N¹, Marioara Poenaru¹, Doros C¹, Stefanescu H¹, Boia ER¹

Abstract

Introduction: Acute rhinosinusitis is a very common disorder that at one time or another affects most people. From a temporal standpoint acute rhinosinusitis lasts for up to 4 weeks. *Streptococcus pneumoniae* (20%-45%) and *Haemophilus influenzae* (22%-35%) are the predominant organisms in acute bacterial rhinosinusitis in adults. An external ethmoidectomy is an alternative approach for treating orbital complications of acute rhinosinusitis, such as a subperiosteal abscess. Complications include diplopia from injury to the trochlea or medial rectus, blindness, exposure keratitis, corneal abrasions, skull base injury, and CSF leak. **Case Report:** We present the patient V.G. 18 years old which first addressed to the Infectious Diseases Department and 2 weeks later to the ENT Department with the following diagnosis: Left Fronto-Ethmoido-Maxillary Acute Bacterial Rhinosinusitis, Left Subperiosteal Abscess with Exophthalmia, Left Upper Eyelid Abscess, Left Chemosis, Left Lower Eyelid Inflammatory Edema. The blood cultures were negative. The treatment consisted in administration of i.v. broad spectrum antibiotics for 15 days. On ENT clinic and nasal rigid endoscopic 0° exam revealed purulent material at the level of left middle meatus, which is blocked, bilateral normal aspect of the inferior turbinates, rhynopharynx with purulent material from the left middle meatus. We performed a maxillary sinus puncture with lavage (+++) and silicon tube insertion. The patient was addressed for a contrast enhancement CT exam. In ENT Department we performed left external ethmoidectomy, left subperiosteal and upper eyelid abscesses drainage followed by Phenoxymethylpenicillin potassium 2g./day – 7 days. As postoperative protective antibiotic was used for 7 days Cilopen (Phenoxymethylpenicillin potassium) 2g./day. At seven postoperative days the signs (left subperiosteal abscess, exophthalmia, left upper eyelid abscess, left chemosis, left lower eyelid inflammatory edema) were resolved. The evolution was favorable with almost complete remission of the symptoms and signs. One month after the surgical procedure the patient presented a slight left proptosis and a slight divergent strabismus. Control CT exam was performed one month postoperative and showed a normal aeration of the paranasal sinuses. **Conclusion:** Orbital and nasal signs and symptoms at one month after the surgical procedure were resolved, the patient presented a slight left proptosis and a mild divergent strabismus..

Key words: orbital complication, external ethmoidectomy, subperiosteal abscess, upper eyelid abscess.

Introduction

Acute rhinosinusitis is a very common disorder that at one time or another affects most people. From a temporal standpoint acute rhinosinusitis lasts for up to 4 weeks.[1] The disorder is almost always due to an infectious process, both viral or bacterial, viruses accounting for the majority of the cases. Acute bacterial rhinosinusitis (ABRS) has been defined as sudden in onset and with duration of less than 4 weeks.[1]

Streptococcus pneumoniae (20%-45%) and *Haemophilus influenzae* (22%-35%) are the predominant organisms in ABRS in adults, whereas *S. pneumoniae* (30%-43%), *H. influenzae* (20%-28%), and *Moraxella catarrhalis* (20%-28%) are the predominant organisms in ABRS in children.[2,3]

In daily clinical practice, however, cultures are rarely performed unless there has been a failure of treatment. The severity of the symptoms and radiographic findings may help identify different pathogens, in that patients infected with *S. pneumoniae* have been found to have more significant symptoms and worse radiographic findings than those infected with *H. influenzae*.[4]

S. pneumoniae decreased from accounting for 43% to 25% of isolates, whereas *H. influenzae* increased from 35% to 41%. The rate for *M. catarrhalis* remained stable, changing from 13% to 14%. The rate for *Streptococcus pyogenes* increased from 7% to 12%, and that for *S. aureus* from 4% to 8%. [5]

Acute complications, both orbital and intracranial, that are unresponsive to medical therapy require immediate surgical intervention. External procedures are used because nasal edema and inflammation may compromise endoscopic exposure. However, in experienced hands, ESS is safe and effective.[6]

An external ethmoidectomy is an alternative approach for treating orbital complications of acute rhinosinusitis, such as a subperiosteal abscess. Complications include diplopia from injury to the trochlea or medial rectus, blindness, exposure keratitis, corneal abrasions, skull base injury, and CSF leak [7].

¹ENT Department, “Victor Babes” University of Medicine and Pharmacy Timisoara

E-mail: balica@umft.ro, marioara.poenaru@gmail.com, caiusdoros@gmail.com, stefanescu@umft.ro, eugen_boia@yahoo.com

Case report

The patient V.G. 18 years old, addressed to the Infectious Diseases Department with the following signs and symptoms: left exophthalmia, left subperiosteal and upper eyelid abscess, left chemosis, left lower eyelid inflammatory edema, nasal obstruction, fever 38,5°C, predominantly left headache. The patient underwent an MRI exam (figure 1) which revealed: left paranasal sinuses with thick mucosa and gadophilic irregular walls, left maxillary and frontal sinuses fluid/parafluid collection, left periosteal and upper eyelid abscess 2.7/1.2/2.4 and 1.1/0.8/1.3 cm., with irregular gadophilic contour, left orbital cellulites and left exophthalmia, edema of the left superior and right lateral muscles, left lower eyelid fluid collection, left hemifacial subcutaneous connective tissue and temporal and masseter muscles diffuse edema. Bilateral frontal and left temporal lobes contrast enhancement of the meninges (meningitis). Left parasagittal frontal epidural abscess 1.5/0.6 cm. The cultures were negative. The treatment consisted in administration of i.v. broad spectrum antibiotics for 15 days.

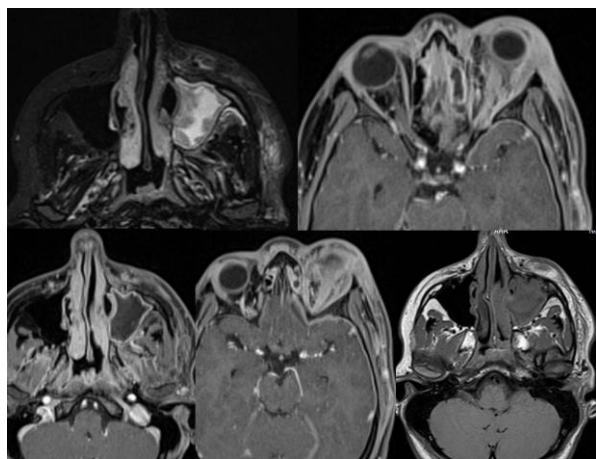


Fig. 1. MRI exam

Abnormal bioassays was represented by ESR 30 mm/h, PCR 61,07 mg/L (0-5 mg/L), WBC 14,54 *10³ /μL (4-10*10³ /μL), NEUT# 12,96 *10¹/ μL (2,2 – 6,60*10¹/ μL), LYMPH# 1,01 *10¹/ μL (1,2 – 4.40*10¹/ μL), NEUT% 89,2% (55,0 – 65,0%) and LYMPH% 6,9% (30 – 40,0%).

Two weeks later the patient was addressed to the ENT Department with the following diagnosis: Left Fronto-Ethomoido-Maxillary Acute Baterial Rhinosinusitis, Left Subperiosteal Abscess with Exophthalmia, Left Upper Eyelid Abscess, Left Chemosis, Left Lower Eyelid Inflammatory Edema.

ENT clinic and nasal rigid endoscopic 0° exam revealed purulent material at the level of left middle meatus, which is blocked, bilateral normal aspect of the inferior turbinates, rhynopharynx with purulent material from the left middle meatus. Bucopharyngoscopy: saburrall tongue and purulent material at the level of posterior wall. Inspection showed left exophthalmia, left upper eyelid abscess, left chemosis, left lower eyelid inflammatory edema (figure 2).

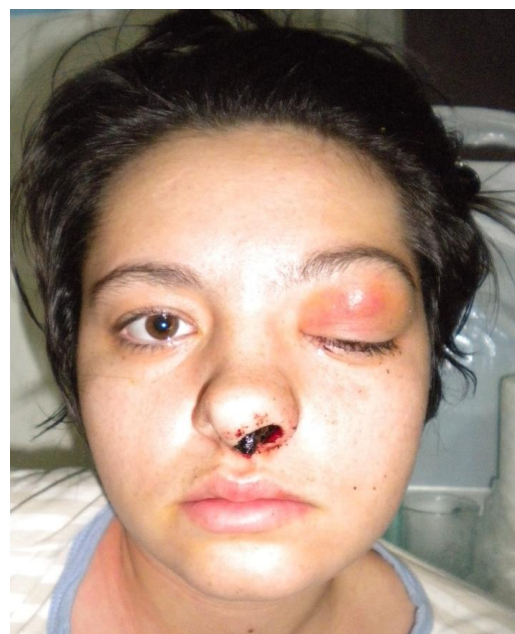

Fig. 2. Preoperative aspect

We performed a maxillary sinus puncture with lavage (+++) and silicon tube insertion. The patient was addressed for a contrast enhancement CT exam.

CT exam with enhancement (figure 3): left maxillary, ethmoid and frontal sinuses with thick mucosa, with fluid, parafluid and haematic collection. Medial wall of the left maxillary sinus presents a 12 mm. osseous discontinuity with a wide communication with ethmoidal cells. Silicon drainage tube present in left nasal fossa and maxillary sinus. It was notice a left subperiosteal parafluid density collection (2.7/1.2/2.4 cm) with slightly irregular wall and left superior eyelid (1.1/0.8/1.3 cm) iodophilic parafluid collection, a left hemifacial subcutaneous connective tissue and temporal and masseter muscles diffuse edema and left exophthalmia, respectively.

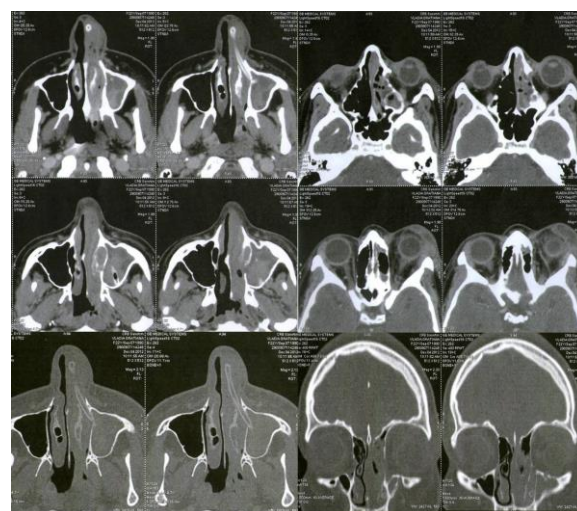


Fig. 3. Enhancement CT exam

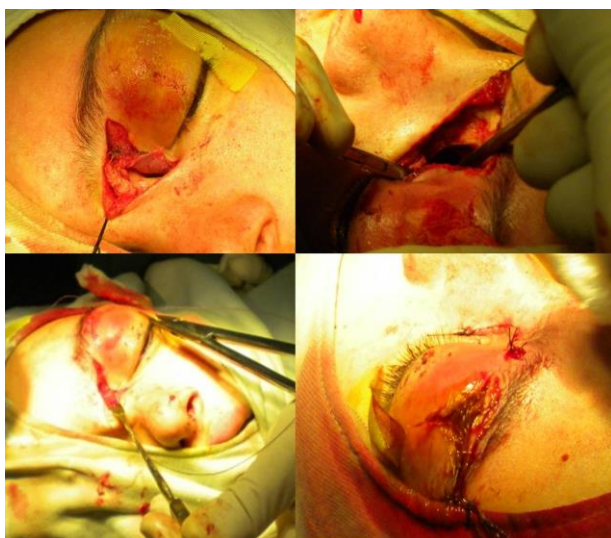


Fig. 4. Intraoperative aspects

Ophthalmologic exam did not show any visual loss or eye movement impairment.

The patient was admitted in the ENT Department Timisoara the second day and the external ethmoidectomy (figure 4) was performed under General Anesthesia with OroTracheal Intubation. The patient was placed in a reversed Trendelenburg position with 1.5" of head-up tilt.

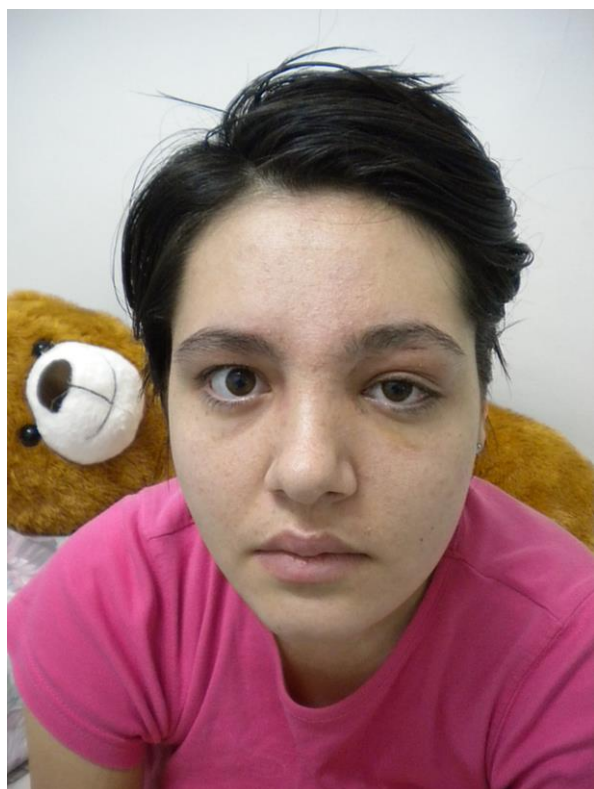


Fig. 5. Postoperative aspect

We removed the silicone drainage tube. A curved incision cutting down to bone was performed from the left medial canthus, mid-way between the medial canthus and the nasal bridge. The periosteum was elevated with a Freer's elevator exposing the nasal process of the maxilla, frontal bone and medial wall of the orbit. The trochlea was sharply dissected with a 15 blade scalpel. The lacrimal sac was elevated and laterally displaced; we exposed the lamina papyracea posteriorly to the level of the anterior ethmoidal artery. Through lamina papyracea we entered and cleared anterior and middle ethmoidal cells, from anterior to posterior, using a Blakesley-Wilde forceps. The medial floor of the frontal sinus was removed and extended laterally. The left subperiosteal abscess was drained. An additional incision of 1 cm. was performed at the upper eyelid midorbit level to drain the abscess.

The periosteal layer was sutured with non-resorbable material. The skin was subcutaneously sutured with fine silk 4.0. The left eye was washed with Betabioptol (Cloramphenicolium + Bethametasonum). As postoperative protective antibiotic was used for 7 days Cilopen (Phenoxymethylpenicillin potassium) 2g./day. Seven days postoperative aspect is showed in figure 5.

The evolution was favorable with almost complete remission of the symptoms and signs. One month after the surgical procedure the patient presented a slight left proptosis and a slight divergent strabismus. Control CT exam was performed one month postoperative (Figure 6).

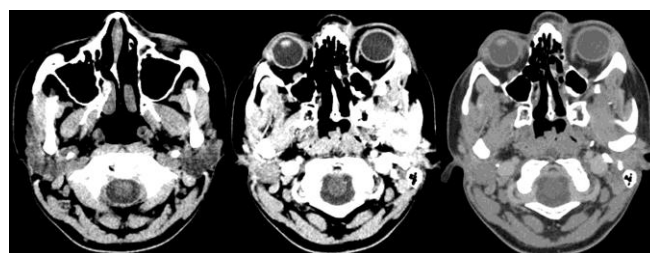


Fig. 6. Control CT exam

Discussion

Orbital cellulitis is usually a complication of paranasal sinus infection. Either the infection may dissect under the periosteum and lead to subperiosteal abscess or intraorbital abscess may be formed secondary to a progressive and localized cellulitis. Without appropriate treatment orbital infection may lead to serious complications, even death [8].

External approach indications are represented by frontoethmoidal mucocoeles, orbital complications of acute frontoethmoiditis, chronic infection unresponsive to conservative medication and surgery, recurrent polyposis, access for ethmoidal artery ligation in the treatment of epistaxis, transethmoidal hypophysectomy, dacryocystorrhinostomy, repair of cerebrospinal fluid (CSF) leaks and orbital decompression. Many of these conditions can be managed by an endoscopic approach but it is not technically possible to use this in all cases. It may also be necessary to employ an external approach as an emergency procedure if an orbital haematoma occurs during endoscopic

sinus surgery. As a consequence, an important role still exists for this approach [9,10,11].

Our patient first addressed to the Infectious Diseases Department and 2 weeks later to the ENT Department, the cultures were negative.

The treatment consisted in administration of Cefort (Ceftriaxonum) 4 g./day – 4 days, Meronem (Meropenemum) 6 g./day – 13 days, , Metronidazol (Metronidazolium) 1.5 g./day – 15 days, Levofloxacin (Levofloxacinum) 0.5 g./day – 13 days, Vancomicina (Vancomycin) 2 g./day – 15 days, Hydrocortisone hemisuccinate 0.2 g./day – 11 days.

In ENT Department we performed an external ethmoidectomy, 0° rigid nasal endoscopy, left subperiosteal and upper eyelid abscesses drainage followed by Cilopen (Phenoxymethylpenicillin potassium) 2g./day – 7 days.

In a study Olwoch I.P. isolated a total of 233 microorganisms from 163 patients (72.1%), and in 63 cases (27.9%) the cultures were negative. The study was retrospective, performed in 2 referral hospitals. The number of the patients was 226 consecutive surgical cases with acute complicated sinusitis, which underwent external fronto-ethmoidectomy with maxillary sinus washout and 13 had a concurrent craniotomy. One hundred and fifty-nine were males and 67 females, with a mean age of 16.5 (standard deviation 0.7) years. Positive cultures revealed *Streptococcus milleri* (18.5%), *Staphylococcus aureus* (12.4%), beta-haemolytic streptococci (10.8%), coagulase-negative staphylococci (8.6%), *Haemophilus influenzae* (8.6%) and the anaerobes, *Peptostreptococcus* (6.4%) and *Prevotella* (4.7%) species. The prevalences of *S. pneumoniae* (2.6%), methicillin-resistant *S. aureus* (MRSA) (1.3%) and *Moraxella catarrhalis* (0.4%) were low. Polymicrobial disease was present in 56 patients (34.4%). There was a significant difference between the two hospitals in the prevalences of some bacteria ($p < 0.05$). Antibiotic resistance was highest towards the penicillins (64.3%) and cephalosporins (12.5%). Effective empiric treatment was achieved with metronidazole and a choice of amoxicillin-clavulanate or ampicillin plus cloxacillin or penicillin plus chloramphenicol. The author concluded that the polymicrobial nature and severity of complicated sinusitis warrants a de-escalation approach to antimicrobial therapy.

The combination of beta-lactamase-resistant penicillins and metronidazole is a reasonable choice for initial empiric antibacterial therapy. Selection of drugs for empirical antibiotic therapy in patients with acute complicated sinusitis should be supported by knowledge of the local prevalence and antimicrobial susceptibilities of bacteria isolated from patients [12].

Strek P. et al. [13] stated that subperiosteal inflammatory disease, subperiosteal abscess and orbital cellulitis are the most common sequelae of both acute and chronic sinusitis.

Early, appropriate evaluation and management observing signs and symptoms of orbital inflammation are required to prevent blindness. CT is the investigation of choice.

Cellulitis does not require drainage of the orbit on a routine basis. Conventionally, the orbital abscess is drained via an external incision and sinus surgery is performed at the same time to remove the focus of infection. More recently, successful treatment both of the sinuses and decompression of the orbit has been accomplished endoscopically via an intranasal approach. Their experience suggests that the optimal method of treatment consists in surgical endoscopic removal of the focus of infection located in the sinuses with simultaneous drainage of the abscess in the orbit [13].

We performed an endoscopic evaluation of the ethmoid and maxillary sinuses and an external ethmoidectomy approach followed by the subperiosteal and upper eyelid abscess drainage.

Subperiosteal abscess should be early and appropriately evaluated and managed, by observing signs and symptoms of orbital inflammation in order to prevent blindness. Hatano A. et al. [14] reported 5 cases of subperiosteal abscess caused by paranasal sinus problems. The treatment consisted in endoscopic ethmoidectomy with puncture or endonasal endoscopic drainage of the abscess. In 4 cases they found orbital complications, using conservative therapy in 1 case with no visual acuity. Three of 4 patients with mild visual acuity and treated with surgical procedure were cured without sequelae. They managed the superior subperiosteal abscess with an endoscopic endonasal approach. One of 4 patients who had severe vision loss, however, was cured without any recovery of loss of vision after surgical drainage to decrease orbital pressure. In their hands the endoscopic endonasal approach is more useful in managing both sinus disease and orbital complications than external ethmoidectomy [14].

In our patient we did not encounter any complication: vision loss, vertical diplopia, incision webbing or paraesthesia of the supratrochlear nerve.

Conclusions

Orbital and nasal signs and symptoms at one month after the surgical procedure were resolved. External ethmoidectomy is a useful alternative approach in cases with orbital complications of suppurative anterior sinusitis with good cosmetic and functional results regarding the postoperative eye movements.

References

1. Lanza D.C., Kennedy D.W: Adult rhinosinusitis defined. *Otolaryngol Head Neck Surg* 1997; 117: S1-S7
2. Anon J.B., Jacobs M.R., Poole M.D., et al: Antimicrobial treatment guidelines for acute bacterial rhinosinusitis. *Otolaryngol Head Neck Surg* 2004; 130(Suppl):1-45.
3. Benninger M.S., Sedory Holzer S.E., Lau J: Diagnosis and treatment of uncomplicated acute bacterial rhinosinusitis: summary of the Agency for Health Care Policy and Research evidence-based report. *Otolaryngol Head Neck Surg* 2000; 122:1-7.

- | | |
|---|--|
| <p>4. Benninger M.S., Brook I., Farrell D.J.: Disease severity in acute bacterial rhinosinusitis is greater in patients infected with <i>Streptococcus pneumoniae</i> than in those infected with <i>Haemophilus influenzae</i>. <i>Otolaryngol Head Neck Surg</i> 2006; 135:523-528.</p> <p>5. Brook I, Gober A.E.: Frequency of recovery of pathogens from the nasopharynx of children with acute maxillary sinusitis before and after the introduction of vaccination with the 7-valent pneumococcal vaccine. <i>Int J Ped Otorhinolaryngol</i> 2007; 71:575-579.</p> <p>6. Bhargava D., Sankhla D., Ganesan A., et al: Endoscopic sinus surgery for orbital subperiosteal abscess secondary to sinusitis. <i>Rhinology</i> 2001; 39:151-155</p> <p>7. Neal G.D: External ethmoidectomy. <i>Otolaryngol Clin North Am</i> 1985; 18:55-60</p> <p>8. Vairaktaris E, Moschos MM, Vassiliou S, Baltatzis S, Kalimeras E, Avgoustidis D, Pappas Z, Moschos MN. Orbital cellulitis, orbital subperiosteal and intraorbital abscess: report of three cases and review of the literature <i>J Craniomaxillofac Surg.</i> 2009 Apr;37(3):132-6. doi: 10.1016/j.jcms.2008.10.007. Epub 2008 Dec 4.</p> | <p>9. Lund VJ Anatomical considerations in the aetiology of frontoethmoidal mucocoeles. <i>Rhinology</i> 1987 25, 83-8.</p> <p>10. Lund VJ & Rolfe M Ophthalmic considerations in frontoethmoidal mucocoeles. <i>J. Laryngol. Otol.</i> 1989 103, 667-9</p> <p>11. Rubin JS, Lund VJ & Salmon B Frontoethmoidectomy in the treatment of mucocoeles: a neglected operation. <i>Arch. Otolaryngol. Otol.</i> 1986 38, 341-3. 112,434-6</p> <p>12. Olwoch I.P. Microbiology of acute complicated bacterial sinusitis at the University of the Witwatersrand <i>S Afr Med J.</i> 2010 Jul 26;100(8):529-33</p> <p>13. Strek P, Zagólski O, Składzień J, Kurzyński M, Oleś K, Muszyński P, Konior M, Hydzik-Sobocińska K Orbital complications of sinusitis treated endoscopically [Article in Polish] <i>Przegl Lek.</i> 2008;65 (5):221-4</p> <p>14. Hatano A, Shiwa M, Iimura J, Tsukidate T, Moriyama H. Surgical management of subperiosteal abscess of the orbit <i>Nihon Jibiinkoka Gakkai Kaiho.</i> 2006 May;109(5):447-54</p> |
|---|--|

Correspondence to:

Eugen Radu Boia,
 “Victor Babes” University of Medicine and Pharmacy
 , ENT Department
 2 Eftimie Murgu Timisoara, Romania
 E-mail: eugen_boia@yahoo.com
 Phone: 0040745977531