EDITOR IN CHIEF

Eugen Sorin BOIA

CO-EDITORS

Radu Emil IACOB
Liviu POP
Maria TRAILESCU

SECRETARY

Radu Emil IACOB
Vlad Laurentiu DAVID

EDITORIAL BOARD

O Adam
Valerica Belengeanu
Marioara Boia
A Craciun
M Gafencu
Daniela Iacob
A Pirvan
CM Popoiu
Maria Puiu
I Velea

EDITORIAL CONSULTANTS

M Ardelean – Salzburg, Austria
Valerica Belengeanu – Timisoara, Romania
Jana Bernic – Chisinau, Moldavia
ES Boia – Timisoara, Romania
Maria Bortun – Timisoara, Romania
V Fluture – Timisoara, Romania
S Garofallo – Milano, Italy
DG Gotia – Iasi, Romania
C Ilie – Timisoara, Romania
Tamás Kovács – Szeged, Hungary
Silvo Lipovšek– Maribor, Slovenia
E Lazăr – Timisoara, Romania
J Mayr – Basel, Switzerland
Eva Nemes – Craiova, Romania
Gloria Pelizzo – Pavia, Italy
L Pop – Timisoara, Romania
I Popa – Timisoara, Romania
Maria Puiu – Timisoara, Romania
GC Rogers – Greenville, USA
J Schalamon – Graz, Austria
I Simedrea – Timisoara, Romania
Rodica Stackievicz – Kfar Sava, Israel
H Stackievicz – Hadera, Israel
Penka Stefanova - Plvdiv, Bulgaria
C Tica – Constanta, Romania

ADDRESS

Timisoara, Romania
Gospodarilor Street, nr. 42
Tel: +4-0256-439441
cod 300778
e-mail: boiaeugen@yahoo.com

JURNALUL PEDIATRULUI – Year XV, Vol. XV, Nr. 59-60, july-december 2012
www.jurnalulpediatrului.ro
ISSN 2065 – 4855

REVISTA SOCIETĂŢII ROMÂNE DE CHIRURGIE PEDIATRICĂ
www.srcp.ro

CONTENTS

1. MEDICAL EDUCATION ON CHRONIC PULMONARY DISEASES IN CHILDREN AND ADULTS
C Oancea, VM Tudorache, C Avram…….....……..……..…...3
2. URINARY TRACT INFECTION, SIGN OF DIAGNOSIS OF VESICOURETERAL REFLUX - CASE PRESENTATION
Anca Gabriela Bădescu, C Tica, Larisia Mihai, Mihaela Munteanu, C Chiriac-Babei, I Bâscă…….....……..…...6
3. KLIPPEL-TRENAUNAY SYNDROME WITH RARE ASSOCIATED COMPLICATIONS – A CASE REPORT
Maria-Corina Stănciulescu, Emanuela Verenca, CM Popoiu, ES Boia,
Anca Popoiu, VL David, Camelia Dăescu, Simona Cerbu, Maria Puiu …….....……..……..….10
4. ECHOGRAPHIC FOLLOW-UP OF REFLUX STATUS IN A CHILD WITH NEUROGENIC BLADDER AND INTERMITTENT VESICAL CATHETERIZATION
Camelia Daescu, Adela Chirita Emandi, C Popoiu, A Craciun, Andreea Militaru, Oana Belei …….…...…...….....14
5. UNUSUAL PRIMARY HYDATID CYST FROM SOFT TISSUE IN CHILDREN: FOUR CASES AND REVIEW OF LITERATURE
Muazez Cevik .....……..……..…..…..18
6. THE IMPORTANCE OF PRELIMINARY ANESTHESIA UNDER GENERAL ANESTHESIA FOR ENT SURGERY IN CHILDREN
D Dumbravă, GhI Comşa.....……..…….....22
7. ACUTE PHASE REACTANTS AND CYTOKINES IN THE EVALUATION OF NEONATAL SEPSIS
Mirabela Dima, C Ilie, Marioara Boia, Daniela Iacob, RE Iacob, Aniko Manea, Nicoleta Ionita…...……...……...27
8. POLYORCHIDISM: A CASE REPORT AND REVIEW OF THE LITERATURE
I Skondras, C Velaoras, C Erikat, I Alexandrou, E Christianakis ……...……...……..…...31
9. THE IMPORTANCE OF THE EARLY DIAGNOSIS IN THE CONGENITAL HEARING LOSS – CASE PRESENTATION
Maria Domuta, Ramona Dorobantu, Valeria Filip, Raluca Iurcov, S Cotulbea, Delia Horhat……...……...34
10. PEDIATRIC ACL RECONSTRUCTIONS USING TRANSPHYSEAL HAMSTRINGS
H Haragus, R Prejbeanu, D Vermesan, G Damian, S Vermesan……..……...……...……...…...37
11. LIVER CHIRRHOSIS – ULTRASOUND ASPECTS OF PORTAL CIRCULATION
Roxana Folescu, Alina Şişu, Elena Pop, Izabella Şargan, B Hogea, Delia Zăhoi, Ecaterina Dăescu, A Motoc……...…….....42
12. A PARTICULAR CASE OF OVARIAN TERATOMA IN A CHILD
RE Iacob, M Soiu, Z Moldovan, H Osakwe, Maria Trailescu, Daniela Iacob……...…..…...47
13. LAPAROSCOPIC APPROACH IN RECTO-COLIC DISEASES IN CHILDREN
M Oancea, Lorena Vatra, Anna Kadar……..……...…....……..…...50
14. JUVENILE NASOPHARYNGEAL ANGIOFIBROMA - CASE REPORT
Dana Florentina Gidea, G Iovanescu, S Cotulbea, Ghiran Ramona Maria, Delia Horhat …….……..……..……..…...54
15. TIBIAL SPINE AVULSIONS IN THE SKELETALLY IMMATURE
D Vermesan, R Prejbeanu, H Haragus, S Vermesan, G Damian……..……....…..……..…...59
16. HISTOLOGICAL FETO-PLACENTAL INTERFACE CHANGES IN THE GESTATIONAL DIABETES MELLITUS
Rodica Ilie, C Ilie, Ileana Enatescu, M Craina, Alexandra Nyiredi, Rodica Heredea…….……....……....……..…...64
17. RESPIRATORY THERAPY IN A LOT OF NEWBORN WITH EXTREMELY LOW BIRTH WEIGHT
Aniko Manea, Marioara Boia, C Ilie, Daniela Iacob, Mirabela Dima, RE Iacob……..……...……...……...…...69
18. AN UNUSUAL COMPLETE DUPLICATION OF THE HINDGUT AND UROGENITAL TRACT: CASE REPORT AND LITERATURE REVIEW
Muazez Cevik ……...……...……....……..…...72
19. RECURRENT URINARY TRACT INFECTIONS IN CHILDREN WITH SECONDARY VESICOURETERAL REFLUX - STUDY OF 10 CASES
Anca Gabriela Bădescu, C Tica, Larisia Mihai, Mihaela Munteanu, C Chiriac-Babei, I Bâscă……...……..…...75
20. VASCULAR ANOMALIES IN CHILDREN – 17 YEARS EXPERIENCE
Maria-Corina Stănciulescu, Emanuela Verenca, ES Boia,
CM Popoiu, VL David, Anca Popoiu, Patricia Cristodor……..……...……...……..…..…...79
21. LIVER NODULAR LESIONS IN THE CHILDREN – BASIC IMAGISTIC APPROACH
SB Motoi, Simona Cerbu, F Birsasteanu……...……...……...……...…....84

MANUSCRIPT REQUIREMENTS……89
ERRATUM. NOTA REDACȚIEI.....90

MEDICAL EDUCATION ON CHRONIC PULMONARY DISEASES IN CHILDREN AND ADULTS

C Oancea[1], VM Tudorache[1], C Avram[2]

Abstract

Therapeutic medical education is a treatment method addressed to both patients (adults and children) with chronic diseases and their families, providing the correct self-management in approaching the disease. The primary objective of a medical education programme is the identification by the physician of patient's optimal intellectual level at which he can understand his disease in order to apply correct management. In the case of children, the optimal intellectual level of parents needs to be accurately identified. The physician has also to test patients' knowledge about their disease and to fill the gaps, to raise their awareness about the risk they expose to if they do not take the diseases seriously and to inform them on the available medical resources for patients. Medical education process has to be continuous and to adjust to the personality type of the patients involved.

Key words: medical education, pulmonary disease, courses

Most studies have shown that medical education of patients has a positive impact manifested through the decrease of exacerbations, as well as of visits to physician and to emergency room.

Not all patients and their families want to participate in these courses. This can be explain by a negative experience in a previous course, preconceived ideas, lack of motivation (especially in terminal stages), poor educational level, low IQ, denial attitude, etc. Depending on both clinic capacity and work groups, three types of approach are recommended:

1. Physician ↔ patient
2. Physician ↔ patient + patient's family
3. Physician ↔ patients with the same respiratory diseases

Education of patient together with his family, or people who take care of them (especially in the case of children, etc.) or education of a group of patients with the same lung diseases is recommended. It has been noticed that the degree of receptivity and therapeutic compliance on the long run is higher when using approaches in which patient interrelate and stimulate each other. Didactic technology needs to include a set of forms, methods, means, techniques and relations which will allow the medical information to be understood optimally by the patient.[1]

Ways of learning[2]

Medical information needs to be diverse, coherent and easy to understand by patients. It can be done by interactive education, using media support (e-learning, visual and audio support, particularly useful in children) and by means of written materials (booklets, flyers). The physician has to identify the best opportunities of communication with the patient and to develop methods to test what he has learnt. These information, as well as the medical terminology well known to the medical personnel might be totally unknown to the patient, which is why this specific vocabulary increases the fear, anxiety distress.[3]

Which notions should be included in respiratory medical education course?[4]

North American guides recommend a complex theme comprising: notions of lung anatomy and physiology, pulmonary disease pathophysiology, description and interpretation of medical tests, notions of medication and treatment, description of physical exercises technique, description of daily activities and energy preservation techniques, symptoms management, nutrition and diet information and psychosocial management.

1. Lung anatomy and physiology

It is recommended to present elementary notions of anatomy (airways, lung segments) and respiratory physiology. Demonstrative practical models (anatomical models) or posters will be used, if possible, so that the patient to perceive (visualise) the information as well as possible.

2. Pulmonary disease pathophysiology

The causes that led to the disease onset, as well as the pathological changes induced by the disease should be explained. Once the patient understands the disease, his compliance with the treatment will automatically increase.

[1] Department of Pneumology, University of Medicine and Pharmacy, Clinical Hospital of Pneumophtysiology and Infectious Diseases "Victor Babeş", Timisoara, Romania
[2] Physical Education and Sport Faculty, West University of Timisoara, Romania
E-mail: oancea@umft.ro, voicu.tudorache@yahoo.com, claudiu.avram@gmail.com

3. Description of medical tests

A special time slot will be devoted to the description of medical analyses and tests. Each test or analysis will be explained, the patient being informed on both the normal and his values. A greater importance will be given to explanation of specific test (where the patient will be also educated on how to perform the test correctly), such as: spirometry, PImax, walking test, effort test. It is important to explain the risks deriving from the performance of these procedures. The following will be shortly and accessibly explained: walking test (of 6 minutes), functional pulmonary tests (spirometry, PImax, DLco), effort test (cardio-pulmonary), pulsoxymetry (HR, SaO_2), thoracic x-ray, ECG, laboratory tests (haematology, biochemistry, electrolytes).

4. Medication and treatment

For each prescribed medicine it is very important to explain the possible adverse reactions, the interactions with other medicines and the route of administration (in the case of pulmonary pathology, the inhalation route is vital). Longer time has to be dedicated to explaining and verifying the technique to children and elders. Patients with chronic respiratory disease frequently use equipments for improving the respiration. Allot more time for explaining the long term oxygen therapy and how these equipments change the life style.

The therapeutic principles of medicines used and the possible adverse effects, the duration and frequency of treatment, as well as the route of administration (nebulizers, aerosol therapy, sprays, disks, etc) should be clearly and concisely explained.

5. Physical exercises technique

Benefits of respiratory exercises will be explained, insisting on the accuracy of the technique and respiratory times. Bronchial hygiene techniques: cough technique, postural drainage, percussion (manual or mechanically assisted), vibration, PEP, flutter therapy, autogenic drainage.

6. Assessment of daily activity[4]

We have to explain what practically means the preservation of energy, avoidance of activities requiring great energy consumption and therefore increased O_2 consumption, transfer of some assignments to family members etc. The main aim is to identify together with the patient and his familiy the proper means to limit them and improve the life style. We have also to teach the patient various energy preservation techniques, to give them advices on how to simplify their work, how to manage their time more effectively. It is very important to teach the patient how to recognise and control the panic attacks (to use different relaxation techniques) – extremely important in both children and adults. A vital aspect is to sensitise children's families about the trips and access to the local medical resources.

7. Respiratory techniques

The patient will be taught the respiratory techniques stressing on the execution method until the patient learns it as an integrative component of the rehabilitation programme. For instance: respiratory clearance techniques (autogenic drainage, flutter therapy, expansion thoracic exercises, etc.), cough training methods, respiratory re-education techniques (airflow directing, re-education of diaphragmatic respiration, control and coordination of respiration, etc.).[4] Monitoring of these exercises until the patient performs them correctly is very important.

8. Symptoms management including quitting smoking

The patient has to understand the importance of quitting smoking, as well as the pathological effects of this vice. Explain also to the patient the environmental factors role (especially during the cold season-bronchoconstriction); teach the patients to avoid irritating factors (pollution) and to recognise and avoid the main allergens (in-door or out-door, e.g.: der. p1, der. farinae, pollens, moulds, etc.). The patient should be taught to recognise an exacerbation, to adjust (by increasing the doses) or to use crisis medication. It is important to explain: quitting smoking and avoid being a passive smoker, environmental factors control (clime, irritating factors, and allergens), dyspnoea management, and recognition of respiratory infection symptoms, exacerbations prevention and periodic vaccination.

9. Nutrition and diet

A large part of patients need nutritional equilibration and diet education; for instance, explaining the importance of hyposodic menu for adult cardiac patients. It is critical to identify if patient needs to loose or gain weight (in case of children) or has a special diet and to verify the amount and frequency of food intake. We have to check whether the patient has adequate hydration, and alcohol consumption/restriction.

10. Psychosocial management

Besides the psychotherapy conducted by a psychologist or a trained physician, it is good to also explain patient's responsibilities: to come to the periodic control, to write down and report the symptoms and to follow the therapeutic plan correctly. The chronic patient has a set of questions that preoccupies him, such as: how much time I have left to live? Or how will I live with this disease?

The following themes should be approached: strategy to accept the disease, depression management, control of panic and anxiety, stress reduction, relaxation techniques, support systems (and how all these can improve their life style), patient-medical care provider relationship, change of the addictive behaviour, improvement of memorisation capacity (mental exercises ± medication support).

Finally, we present a model of practical scheme for medical education within a pulmonary rehabilitation programme.[4]

Session 1 – explaining PRP (benefits and programmes types)

Session 2 – explaining medical tests (functional explorations, medical analyses)

Session 3 – lung anatomy

Session 4 – description and explanation of inhalation devices (practical demonstrations)
Session 5 – explaining medication (benefits, adverse effects and medicines interactions)
Session 6 – importance of nutrition (diet or repletion)
Session 7 – description of energy preservation techniques
Session 8 – relaxation techniques and panic control
Session 9 – prevention of infections, environmental factors control
Session 10 – adjustment to disease
Session 11 – description of adaptive equipments and access to medical resources

Conclusions

- The process of medical education in the management of pulmonary disease is permanent and complex.
- Children with chronic pulmonary disease require a special attention and an educational process focused on their cognitive level.
- A great stress must be put on the learning of respiratory technique elements adapted to patient's age.

References

1. C.Docherty, D.Hoy, H.Topp, K.Trinder eLearning techniques supporting problem based learning in clinical simulation International Journal of Medical Informatics, Volume 74, Issue 7, Pages 527-533
2. Jorge G. Ruiz, Michael J. Mintzer, Rosanne M. Leipzig, The Impact of E-Learning in Medical Education, Acad Med. 2006; 81:207–212.
3. The use of elearning in medical education, Kay Mohanna, Postgrad. Med. J. 2007;83;211
4. Guidelines for Pulmonary Rehabilitation Programs, third edition, AACPR
5. Tudor Sbenghe Recuperarea Medicală a Bolnavilor Respiratori, Editura Medicală, 1983.

Correspondance to:
Cristian Oancea,
Department of Pneumology,
University of Medicine and Pharmacy "Victor Babes"
13 Gheorghe Adam,
Timisoara, Romania
Telephone: 0040769221057
E-mail: oancea@umft.ro

URINARY TRACT INFECTION, SIGN OF DIAGNOSIS OF VESICOURETERAL REFLUX - CASE PRESENTATION

Anca Gabriela Bădescu[1], C Tica[1], Larisia Mihai[1], Mihaela Munteanu[2], C Chiriac-Babei[3], I Bâscă[3]

Abstract

Ureteral abnormalities represent a complex and often confusing subset of urological anomalies that manifest in many ways. However, in the current era, hydronephrosis that is evident on fetal ultrasonography often heralds a ureteral abnormality. (1)

Ureteral duplication is the most common renal abnormality, occurring in approximately 1% of the population and 10% of children who are diagnosed with urinary tract infections. Incomplete ureteral duplication, in which one common ureter enters the bladder, is rarely clinically significant. Alternatively, complete ureteral duplication, in which 2 ureters ipsilaterally enter the bladder, has a propensity for vesicoureteral reflux into the lower pole and obstruction of the upper pole, which can be problematic.

The authors present a case of a very late diagnosed malformation reffering to a urinary system, with an already installed reflux nephropathy. The case is about a urinary-renal malformation associated with vesicoureteral reflux, manifested by urinary tract infection, first positive episode diagnosed at high age.

Positive diagnosis was facilitated by laboratory investigations (urine analysis, urine culture, voiding cystourethrography, static renal scintigraphy).(1)

Key words: voiding cystourethrography, urinary tract infection, vesicoureteral reflux, ureter duplication.

Introduction

The pielo-ureteral duplication is a kidney with two pielo-caliceale systems draining two ureters, entering the bladder through two orifices, which are either united or go through a single orifice.(2) Is the most frequent abnormality of ureters. These children are most commonly affected by UTIandpyelonephritis, both in vesico-ureteral reflux and through the obstruction.

The duplicate appears when there is a fast bifurcation of ureteralbud, resulting in a bifid ureter or when there are two ureteralbuds risen from mesonefroticduct, resulting in a double ureter. The two resulted renal units are called poles. Renal surface may reveal a ditch separating the two poles, which have independent vascularity and intrarenal anastomosis. The upper segment is smaller, drained by a single caliceal group and the ureter opens wider caudal into the bladder at the lower pole. The lower pole is bigger, drained by two potassium and by a well developed pelvis. Often the upper pole gets cut off, and the urography gives the appearance of "Wilted Flower" due to viewing only the lower pole.(3)

From an embriological point of view, the appearance of ureteral duplication with double ureter is subject to the principle of Weigert-Meyer, acordind to which the ureteral buds cranial revealed on the Wolf channel will have a caudal orifice in the future bladder and those emerged caudal, will have a cranial orifice. This theory explains the presence of the crossing that characterizes the route of double ureters so that in the ureteral duplicate, the upper pole of the urete opens caudal in the bladder from the lower pole.

Vesicoureteral reflux occurs most frequently in the lower pole since caudal ureter opens sided and cranial into the bladder and has a shorter submucosal trajectory. (1). Vesicoureteralreflux occurs on the upper pole when two orifices are adjacent or when its ureter opens distal to the cervix and therefore does not have any support to the detrusor. (4)

The principles of therapeutic indication are the same as those for primary vesicoureteral reflux, and reimplantation techniques addresses to both ureters as they present commune vascularity in the distal part. Ureteral anastomosis techinques and reimplantation of one ureter may be useful in some cases (4).

Case presentation

The authors present a case of malformation of urinary system late diagnosed, when reflux nephropathy is already installed.

In the Pediatric Surgery Clinic of Constanta County Emergency Hospital has admitted a female patient, aged 11 years and 9 months, for fever and abdominal pain. There wasn't any micturition difficulty, such as pollakiuria or dysuria. Past medical history sows no urinary infections. During the examination we find a child with a weight weakness stature (size 135 cm, weight 30 kg), but no pale skin, with dark urine, without any pathological changes.

Laboratory investigations revealed a WBC count of 20000/mm ^{3}, with predominance of granulocytes, ESR = 26 mm / h, normal blood urea and serum creatinine, CRP positive, urine analysis with frequent leukocyte, positive nitrite, pH 7, urine culture showed the presence of E. coli.

[1]County Emergency Hospital Constanța
[2]Children Hospital,„Sfânta Maria" Iași
[3]Children Hospital „Grigore Alexandrescu" Bucharest
E-mail: badescuanca2000@yahoo.com, constantin.tica@yahoo.com, larisia_mihai@yahoo.com, mihaelamunteanu2001@gmail.com, cbcatalin@yahoo.com, ion.basca@gmail.com

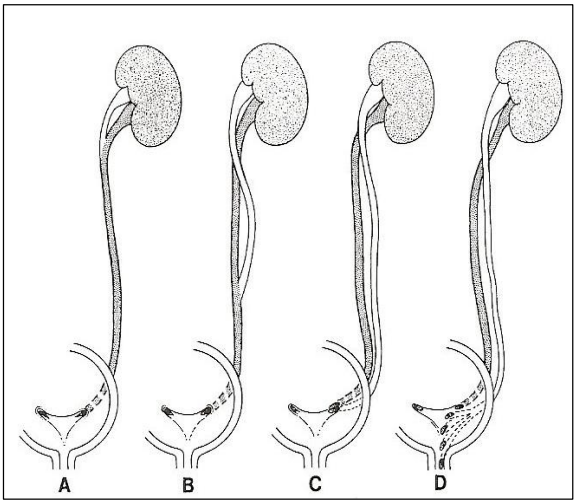

Fig.1. Types of duplication – After Ascraft Pediatric Surgery 2000 Saunders (2).

Imaging investigations showed:

1. Abdominal ultrasound showed pielo-caliceal duplicity right sided with mildright caliceale dilatation, (5)

2. Intravenous urography shows a right kidney with right pieloureteral duplicity (5)

3. Voiding cystourethrography showed a grade III of vesicoureteral reflux without dilatation of urinary tract,(Fig.2.)

4. Renal scintigraphy withTcDTPA, already shows the presence of bilateral renal scarrs, with renal functions stil normalGFR= 114ml/min,(FIG.3) (4,6)

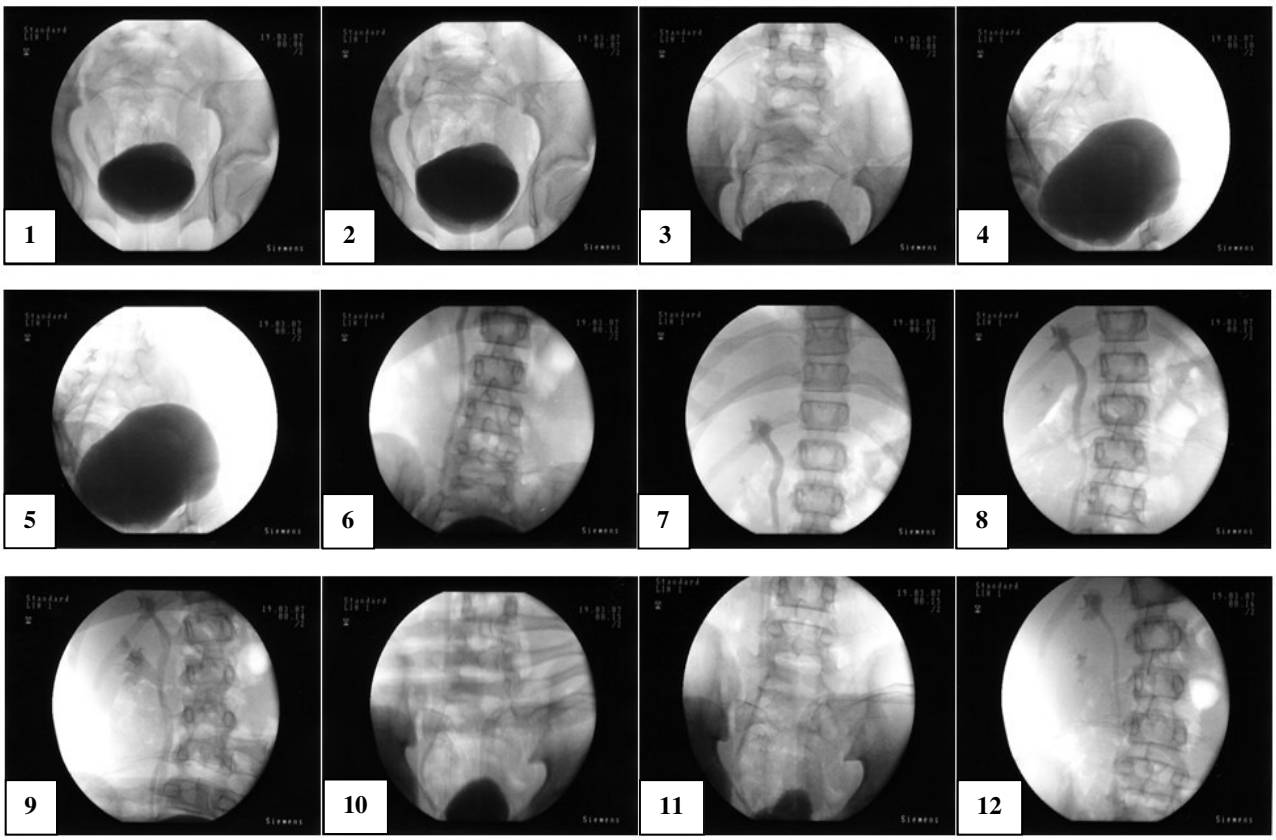

Fig. 2. Voiding cystourethrography Collection Pediatric Surgery Clinic Constanta.

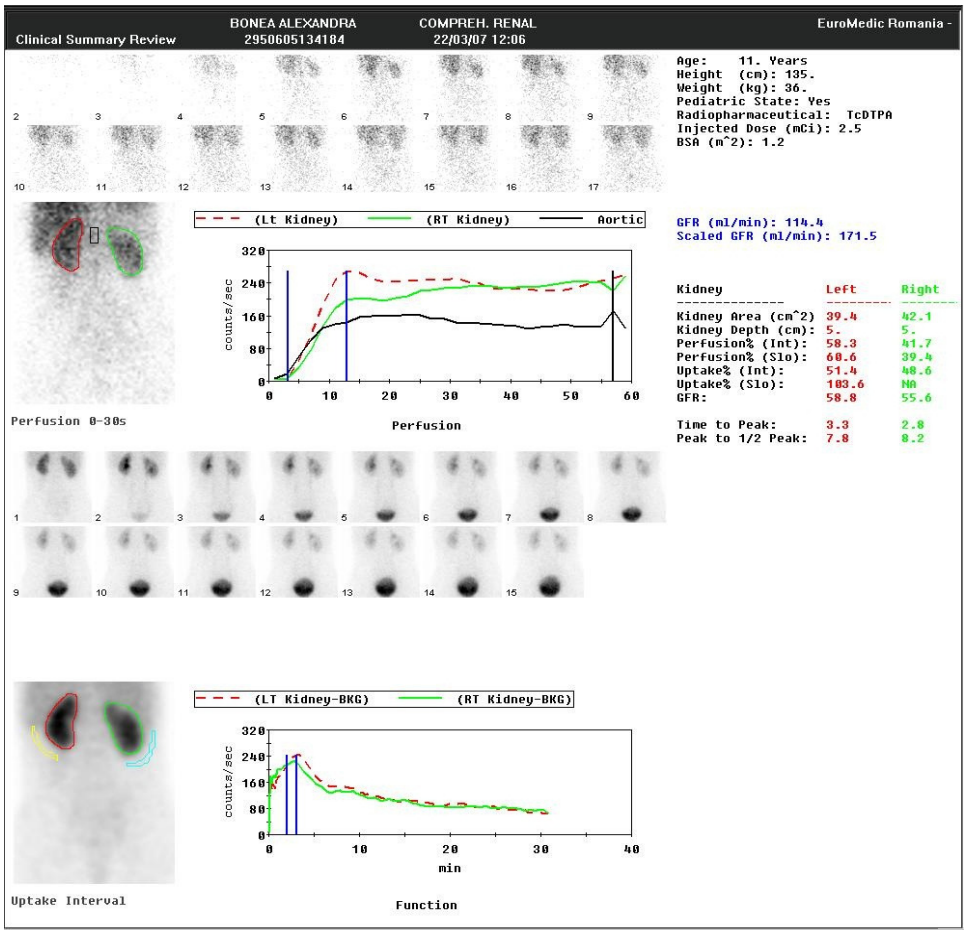

Fig. 3. Renal scintigraphy with TcDTPA, Collection Pediatric Surgery Clinic Constanta.

After the diagnosis had been set, that is, urinary tract infection present, the anamnesis was detailed, knowing the history of febrile episodes without setting definite etiology

The correct treatment of urinary tract infection was set, with intravenous ceftriaxone 3 days, then Cefuroxime, 11 days at 12 hours, with repeated urine culture after 3 days. It became sterile.

The patient was placed in a program for prevention of recurrences of urinary infections with the following scheme: nalidixic acid, cefuroxime, trimethoprim alternating for 10 days of month, 1/3 of the dose. It has been decided to delay surgery. Eventhough with a late established diagnosis, the patient never presented herself to the followup.

Discussions

This paper presents a special case of pediatric pathology, (nephrology, urology), why? Because there hasn't been implemented a protocol to establish pediatric urinary malformations, and implicitly, of the vesicoureteral reflux.

Positive diagnosis of malformation of renourinare paths was established very late, and the child was 11 years old, though she had a weakness stature weight, for which was not established any cause. Positive diagnosis was facilitated by performing voiding cystourethrography and static scintigraphy TcDTPA.(1)

Although the diagnosis was established very late, the short-term prognosis is good, with better renal function, but with appearance of renal scarrs which is an indirect sign for reflux nephropathy. Long-term prognosis can not be currently estimated, taking into account the literature that says that the appearance of reflux nephropathy leads to complications such as hypertension, chronic renal failure.

Recurrence prevention of urinary tract infections is important in order to prevent appearance of new renal scarrs, and therefore introducing a long term antibiotic treatment scheme to the child, one evening, 1/3 of the dose, for 6 months, with further evaluation..

Further lack of patient compliance, makes the long term prognosis worse.

Conclusions

We tried to present a case of urinary-renal malformation associated with vesicoureteral reflux, manifested by urinary tract infection, with first positive episode diagnosed at a highage.

Positive diagnosis was facilitated by laboratory investigations (urine analysis, urine culture, voiding cystourethrography, static renal scintigraphy).

An early introduction of a protocol is important for early diagnosis of vesicoureteral reflux in order to maintain a normal renal function of the future adult.

References

1. Chiriac-Babei Cătălin, Dima Bogdan Alexandru - *Importanța diagnosticului imagistic in refluxul vezicoureteral la copil*, Revista Română de Pediatrie – vol. LVIII, NR. 1, 2009,page 40-45
2. Ashcraft Keith W.: *Pediatric Surgery*. Ed. a 3-a, W.B. Saunders Company, Philadelphia, London, New York s.a., 2000, p.467
3. Bâscă Ion: *Refluxul vezico-ureteral la copil*. Editura Ştiinţifică, Bucureşti, 1998, p.102-105,
4. Temiz Y, Tarcan T, Önol FF, Alpay H. & Şimşek F – *The efficacy of Tc99m (Tc-DMSA) scintigraphy andultrasonography in detecting renal scars in children with primary vesicoureteral reflux.* International Urology and Nephrology,Volume 38, 2006, p. 149-152
5. Darge Kassa – *Diagnosis of vesicoureteral reflux with ullrasonography*, Pediatric Nephrology, Volume 17, 2002, p. 52-60
6. Ataei Neamatollah, Madani Abbas, Habibi Reza – *Evaluation ofacute pyelonephritis with DMSA scans in children presenting after the age of 5 years*. Pediatric Nephrology, Volume 20, August 2005, p. 1439-1444

Correspondance to:

Anca Gabriela Bădescu,
County Emergency Hospital Constanța,
B-rd Tomis no 145,
Constanța,
România,
Telephone: 0722238808
E-mail: badescuanca2000@yahoo.com

KLIPPEL-TRENAUNAY SYNDROME WITH RARE ASSOCIATED COMPLICATIONS – A CASE REPORT

Maria-Corina Stănciulescu[1], Emanuela Verenca[2], CM Popoiu[1,2], ES Boia[1,2], Anca Popoiu[1,2], VL David[1,2], Camelia Dăescu[1,2], Simona Cerbu[1] , Maria Puiu[1,2]

Abstract

Klippel-Trenaunay Syndrome (KTS) is a rare congenital malformation consisting of venous, capillary and lymphatic abnormalities, in addition to hypertrophy and overgrowth of the bony and/or soft tissue of the affected limbs. We report a unique case of KTS due to its complex association of complications (hydronephrosis, rectorrhagia and splenomegaly).

Key words: Klippel-Trenaunay Syndrome (KTS), hydronephrosis, rectorrhagia, splenomegaly

Introduction

Klippel-Trenaunay Syndrome (KTS) was first described in 1900 by physicians Klippel and Trenaunay, who evidenced the constellation of three major clinical features: capillary, venous and lymphatic vascular malformations; varicose veins with an early onset; and bony and/or soft tissue hypertrophy and overgrowth [1]. One of the lower limbs is the most frequent involved site and it is usually hypertrophied [2].

Other common features of KTS include: hyperhydrosis, skin atrophy, verrucae, dermatitis, thrombophlebitis, and cellulitis [3]. Deep vein thrombosis, pulmonary embolism, gram-negative sepsis and coagulopathy are sometimes present and represent life-threatening complications [4]. While most KTS cases are sporadic, theories arguing for an autosomal dominant (AD) mode of inheritance have been formulated. It was noticed that in the case of some affected individuals, first-degree relatives presented a high incidence of capillary malformations and varicose veins [5]. KTS has been linked to two balanced reciprocal translocations, namely 46,XX,t(5;11) (q13.3;p15.1) [6] and 46,XY,t(8;14)(q22.3; q13) [7]. Moreover, a genetic predisposition for the development of KTS has been established following the discovery of a susceptibility gene for the syndrome, specifically the angiogenic factor gene VG5Q, the up-regulation of which results in increased angiogenesis [8]. As these tests are unavailable in most clinics, a diagnosis of KTS, be it idiopathic or genetic, is usually based on clinical signs, ultrasound and imagistic studies.

Case presentation

An 8 year and 7 month old child, first newborn of healthy, nonconsanguineous parents aged 20 and 24 was referred to us. The patient's mother had an uneventful pregnancy, with no history of medication intake. However, both parents worked in a toxic environment (car cable factory) both prior and throughout pregnancy. Family history is unremarkable. Examination of the infant after birth revealed multiple diffuse cutaneous hemangiomatosis of the port-wine type (covering 60% of body surface and involving completely both legs and the left arm, and part of the gluteal region, genitalia, trunk and face); edema and hypertrophy of the above-mentioned limbs; and bilateral syndactyly of the second and third toes. Ultrasound of the abdomen showed bilateral congenital hydronephrosis (stenosis of the vesicoureteral junction on the right and stenosis of the pielo-ureteral junction on the left). Chromosomal analysis revealed the 46,XY karyotype.

Over the years, the patient underwent surgery for the following conditions: hydronephrosis (right ureterostomy at 5 months of age followed by ureter reimplantation at 10 months of age; left Hynes-Anderson pyeloplasty at 5 months of age); left inguinal hernia; congenital verrucous lesions of the endobucal and perianal cavity; and periodontal abscess. Patient history is significant for the following: pneumocystis pneumonia; rectorrhagia; recurrent bronchiolitis; and profound venous thrombosis and thrombophlebitis (for which he is taking anticoagulant treatment).

At the moment (Figure 1) the patient presents, throughout the entire length of the lower extremities, edema and hypertrophy, with multiple dilated and tortuous venous varicosities. The left lower extremity is more severely affected than its counterpart (50 cm versus 43 cm in girth at the level of the hip and 34 cm versus 31 cm at the level of the thigh). Moreover, the left leg presents an overgrowth in length of 4 cm compared to the right leg; this difference was 2 cm two years ago. The patient's left upper extremity presents muscular hypoplasia. Doppler echography demonstrates normal arterial and venous blood flow all throughout the affected members; however, there is destruction of the venous valves and higher blood flow rate in the left leg versus the right leg.

[1]Emergency Hospital for Children "Louis Ţurcanu" Timişoara, România
[2]University of Medicine and Pharmacy "Victor Babeş" Timişoara, România
E-mail: stanciulescucorina@yahoo.com, emma_ver@yahoo.com, mcpopoiu@yahoo.com, boiaeugen@yahoo.com, david.vlad@yahoo.com, camidaescu@yahoo.com, cerbusimona@yahoo.com, maria_puiu@umft.ro

Port wine stains are present in the same distribution as upon birth. Abdominal ultrasound reveals second degree hydronephrosis on the left, first degree hydronephrosis on the right and splenomegaly (14.5 cm).

Figure 1: Evidence of limb hypertrophy and hyperplasia, left lower limb overgrowth, tortuous venous varicosities, port-wine stains and syndactily.

MRI shows multiple hemangiomas in the subcutaneous tissue all throughout the body and a scrotal lymphangioma. MRI angiography reveals normal arterial system with no evidence of AV fistulas in the lower extremities (Figure 2) while MRI phlebography reveals dilation of the superficial venous system of the affected members and multiple varicose venous tracts in the subcutaneous tissue of the hips and calves (more severe on the left) (Figure 3).

Figure 2: MRI Angiography with no evidence of AV fistulas.

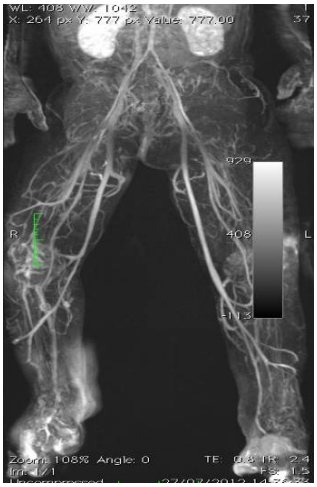

Figure 3: MRI Phlebography evidencing calves varicosity.

The patient has a normal mental development, with an IQ of 103. He was diagnosed at 3 years of age with developmental language disorder but responded very well to logopedic therapy. He attends regular school and is well integrated among his classmates, despite his inability to participate in group activities that require physical exercise. Current management of our patient includes orthopedic shoes (which are changed every 6 months), lymphatic drainage massage (2 x week), compression garments and monthly INR monitoring.

Discussions

KTS affects males and females in an equal proportion, irrespective of their ethnic background [2, 9]. Its features usually develop slowly during childhood and are fully present at birth in rare cases only. However, capillary malformations are seen at birth in 98% of cases [9]. Both upper and lower extremity involvement is present in about 10% of patients [3]. For the 1956 – 1981 period, KTS limb involvement in Mayo Clinic patients was unilateral in 85%, bilateral in 12.5%, and crossed-bilateral in only 2.5% [3]. Our patient's involvement of both lower and the left upper extremity represents a rare case of KTS.

In a study conducted by Jacob et al [10] on 246 patients, the frequency of KTS clinical features include: port-wine stains in 98% of patients, varicosities and/or venous malformations in 72% and limb hypertrophy in 67%, all of which are present in our patient. The frequently

increased limb girth in KTS is mainly due to lymphedema and soft-tissue hypertrophy [9]. Hemangiomas in KTS may be limited to the skin or may extend into the subcutaneous tissue [11], as in the present case. Syndactyly, which characterizes the child, is a common finding in KTS [9]. The muscular hypoplasia seen in the patient's left arm is a relatively rare finding in KTS and is thought to be related to the existence of intramuscular lesions [12].

Several theories have been formulated to explain the osseous growth that is seen in an overwhelming majority of KTS patients. One theory argues that it could be attributed to venous hypertension [13]. Another suggests that it could be the result of a genetic defect that leads to both vessel malformations and excess limb circumference and length [9]. A third theory proposes that a mesodermal defect during fetal development results in delayed regression of the embryonic vascular reticular network in the developing limb, which leads to increased blood flow (within normal limits, however), higher bone growth rates, venous abnormalities and cutaneous nevus development [14]. Our patient's case supports the last theory listed, as Doppler echocardiography demonstrates normal but higher blood flow in the more effected extremity versus its less affected counterpart.

On a group of 40 patients with KTS, Gloviczki et al [3] found that the average difference in length between the affected and non-affected lower extremity was 2.39 cm, with only two patients experiencing an accentuation of more than 1 cm in this difference over a two year period. The 4 cm length discrepancy between the patient's legs and the 2 cm lengthening difference he experienced over the past two years account for an unusual case of KTS.

Common complaints of patients with KTS, which have been experienced by our patient as well, include: pain, swelling, bleeding, superficial thrombophlebitis, cellulitis, heaviness and weakness in the affected limbs [9, 11]. In addressing these problems, therapeutic approach of KTS is usually conservative – compression garments; pain management; anticoagulant therapy when there is predisposition to thrombosis; prophylactic antibiotic therapy in recurrent cellulitis; lymphatic drainage in cases of significant edema; and rigorous hygiene of affected limbs to prevent infection and cellulitis [3,9,11].

The case we present is particularly interesting as the patient has a history of hydronephrosis, splenomegaly and rectorrhagia, all of which have rarely been individually reported in association with KTS, and, to our knowledge, never together. Splenomegaly in KTS has been linked to high venous pressure due to splenic vein stenosis [15] and/or splenic hemangioma/lymphangioma [16]. Some cases of rectorrhagia are though to occur as a result of the hypogastric vein being overloaded by the posterolateral veins of the affected extremity, which impedes proper pelvic drainage and leads to dilatation of hemorrhoidal veins and rectal bleeding [3].

Major differentials for KTS include Parkes Weber syndrome (PWS), Servelle-Martorell syndrome (SMS) and Proteus syndrome (PS). As demonstrated by arteriography, in KTS, contrary to PWS, there is absence of arteriovenous (AV) fistulae, especially at the epiphyseal plate, and there is usually no bone anomaly other than its hypertrophy [3]. SMS can be excluded on the account that, while it represents an association of capillary stains, dilated superficial veins and limb circumferential hypertrophy, it is characterized by undergrowth and not overgrowth of the affected limb, as intraosseous vascular malformations result in cortical bone and spongiosa destruction, leading to bony hypoplasia [4, 17]. In our case, MRI reveals a normal bone structure (Figure 4). The diagnosis of PS can be eliminated because, while patients with PS can experience the capillary, venous and lymphatic malformations of KTS, the most common manifestation of PS is a connective tissue nevus clinically apparent as cerebriform thickening of the palms and soles, which does not characterize our patient; moreover, linear verrucous epidermal nevi and brain structural malformations, which are common in PS, are not seen in our patient either [4].

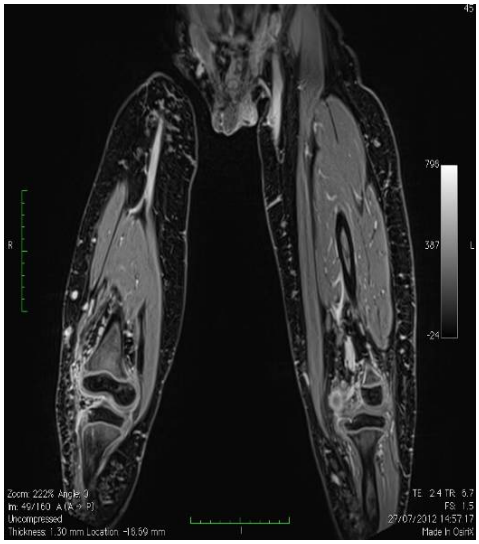

Figure 4. MRI showing normal bone structure.

Conclusion

Hydronephrosis, rectorrhagia and splenomegaly have rarely been associated with KTS. To our knowledge in the English literature, this is the first reported case of a patient with KTS who is affected by all three conditions. That, in addition to the unusual three limb involvement, makes our patient's case noteworthy to report on. As none of the newly-developed genetic testing that could indicate KTS is available in our clinic, we are unable to argue whether the patient's unique condition is sporadic or whether it arose due to a genetic predisposition. The uniqueness of the case makes genetic testing highly advisable.

References

1. Klippel M, Trenaunay P. Du naevus variqueux osteohypertrophique. Arch Gen Med 1900;185:641-672.
2. Cohen MM Jr. Klippel-Trenaunay syndrome. Am J Med Genet. 2000 Jul 31;93(3):171-5.
3. Gloviczki P, Hollier LH, Telander RL, Kaufman B, Bianco AJ, Stickler GB. Surgical Implications of Klippel-Trenaunay Syndrome. Ann Surg. 1983 Mar;197(3):353-62.
4. Garzon MC, Huang JT, Enjolras O, Frieden IJ. Vascular malformations: Part II: Associated syndromes. Journal of the American Academy of Dermatology 2007 Apr;56(4):541-564.
5. Timur AA, Sadgephour A, Graf M, Schwartz S, Libby ED, Driscoll DJ, Wang Q. Identification and molecular characterization of a de novo supernumerary ring chromosome 18 in a patient with Klippel-Trenaunay syndrome. Ann Hum Genet. 2004 Jul;68(Pt 4):353-61.
6. Whelan AJ, Watson MS, Porter FD, Steiner RD "Klippel-Trenaunay-Weber syndrome associated with a 5:11 balanced translocation." Am J Med Genet. 1995 Dec 4;59(4):492-4.
7. Wang Q, Timur AA, Szafranski P, Sadgephour A, Jurecic V, Cowell J, Baldini A, Driscoll DJ. Identification and molecular characterization of de novo translocation t(8;14)(q22.3;q13) associated with a vascular and tissue overgrowth syndrome. Cytogenet Cell Genet. 2001;95(3-4):183-8.
8. Tian XL, Kadaba R, You SA, Liu M, Timur AA, Yang L, Chen Q, Szafranski P, Rao S, Wu L, Housman DE, DiCorleto PE, Driscoll DJ, Borrow J, Wang Q. Identification of an angiogenic factor that when mutated causes susceptibility to Klippel-Trenaunay syndrome. Nature. 2004 Feb 12;427(6975):640-5.
9. Enjolras O, Chapot R, Merland JJ. Vascular anomalies and the growth of limbs: a review. J Pediatr Orthop B. 2004 Nov;13(6):349-57.
10. Jacob AG, Driscoll DJ, Shaughnessy WJ, Stanson AW, Clay RP, Gloviczki P. Klippel-Trénaunay syndrome: spectrum and management. Mayo Clin Proc. 1998 Jan;73(1):28-36.
11. Billingham R. Klippel-Trenaunay-Weber syndrome — a case report. Journal of Lymphoedema, 2010;5 (1):99-103.
12. Funayama E, Sasaki S, Oyama A, Furukawa H, Hayashi T, Yamamoto Y. How do the type and location of a vascular malformation influence growth in Klippel-Trénaunay syndrome? Plast Reconstr Surg. 2011 Jan;127(1):340-6.
13. Servelle M. Klippel and Trénaunay's syndrome. 768 operated cases. Ann Surg. 1985 March;201(3):365–373.
14. Baskerville P A, Ackroyd J S, Browse N L. The etiology of the Klippel-Trenaunay syndrome. Ann Surg. 1985 November; 202(5):624–627.
15. Hamano K, Hiraoka H, Kouchi Y, Fujioka K, Esato K. Klippel-Trenaunay syndrome associated with splenomegaly: report of a case. Surg Today. 1995;25(3):272-4.
16. Jindal R, Sullivan R, Rodda B, Arun D, Hamady M, Cheshire NJ. Splenic malformation in a patient with Klippel-Trenaunay syndrome: a case report. J Vasc Surg. 2006 Apr;43(4):848-50.
17. Karuppal R, Raman RV, Valsalan BP, Gopakumar TS, Kumaran CM, Vasu CK. Servelle-Martorell syndrome with extensive upper limb involvement: a case report J Med Case Reports. 2008 May;2:142.

Correspondance to:

Maria-Corina Stănciulescu
Str. Dr. Iosif Nemoianu No.2
Timisoara,
Romania,
E-mail: stanciulescucorina@yahoo.com

ECHOGRAPHIC FOLLOW-UP OF REFLUX STATUS IN A CHILD WITH NEUROGENIC BLADDER AND INTERMITTENT VESICAL CATHETERIZATION

Camelia Daescu[1,2], Adela Chirita Emandi[1,2], C Popoiu[1,2] , A Craciun[1,2], Andreea Militaru[1,2], Oana Belei[1,2]

Abstract

Objectives: We highlight the role of echography in the follow-up of an 8 year old girl with neurogenic bladder, right megaureter due to reflux; left obstructive megaureter, and impaired renal function.

Methods: The patient came quarterly to follow-up, to evaluate renal function and possible infections, while the hydronephrosis was evaluated by echography. She had intermittent vesical catheterization and antibiotic prophylaxis.

Results: The girl was diagnosed at 3 months of age with complex renal malformation, one month later she underwent bilateral cutaneous ureterostomy. Ureteral reimplantation surgery was performed at the age of 1 year and 6 months. At age 6, abdominal echography revealed bilateral hidronephrosis grade IV, which was sustained by uroMRI and stage 2 renal failure shown by renal function tests. Intermittent vesical catheterization 4 times/day and antibiotic prophylaxis were initiated. The echographic follow-up reported that the reflux remained mostly unchanged: left kidney had hydronephosis grade III, and the right kidney presented hydronephosis grade III/IV. Nevertheless the parenchymatous index increased, which correlates with the improved renal function, from stage 2 renal failure (moderate reduction in glomerular filtration rate=58mL/min/1.73m2) to normal glomerular filtration rate. The blood urea nitrogen and creatinine levels slightly decreased. The urinary tract infection rate remained low.

Conclusions: Long-term intermittent catheterization as method of treatment and prevention is associated with stable reflux status, renal function, and infection rate, which in the end result in better quality of life for the patient. Echographic method of follow-up is reliable for medical examinations since it is informative, harmless and economical.

Key words: Echographic follow-up; child; intermittent vesical catheterization

Background

The urinary complications of patients with a neuropathic bladder consist of incontinence, inability to empty the bladder, urinary infection, and deterioration of the upper urinary tract. Intermittent self-catheterization (ISC) or carer/nurse-assisted clinically clean intermittent catheterization (CIC) has developed over the past 30 years as a means of treating patients with bladder-emptying problems. It is now recognized as one of the safest methods of managing patients, especially those with neurogenic bladder disorders (1). CIC has been demonstrated to reduce infection hazards and greatly improve the lives of many patients with micturition disorders. In 1972, Lapides et al (2) reported the successful treatment of neuropathic bladders with CIC and since then CIC has become widely accepted as the main therapeutic management for patients with such bladders. CIC can be undertaken by health professionals in a variety of clinical settings for a range of clinical indications, and increasingly by patients themselves who use it as a long-term bladder management technique. The relative simplicity of the technique comes with the potential for health professionals to underestimate the skills required when considering a regimen of intermittent catheterisation and, perhaps more importantly, to underestimate the impact it may have on individual patients (3). Adequate bladder emptying can be achieved by CIC, but urinary incontinence may persist in the presence of detrusor hyperreflexia and/or low compliance bladder.

Objectives

To highlight the role of echography in the follow-up of an 8 year old girl with neurogenic bladder, right megaureter due to reflux; left obstructive megaureter, and impaired renal function.

Case report

History

We present an 8 years old girl that we have in management, in the Nephrology department of Emergency Hospital for Children "Louis Turcanu" in Timisoara. The child is the first born of healthy non-consanguineous parents. There was no family history of similar symptoms.

[1]University of Medicine and Pharmacy "Victor Babes" Timisoara
[2]Emergency Hospital for Children "Louis Turcanu" Timisoara
E-mail: camidaescu@yahoo.com, adela.chirita@yahoo.com, mcpopoiu@yahoo.com, ad_craciun@yahoo.co.uk, andreamilitaru@yahoo.com, oana22_99@yahoo.com

The girl was diagnosed at the age of 3 months of age with agenesis of the corpus callosum and complex renal malformation (figure 1 and 2). At the age of 4 months, she underwent bilateral cutaneous ureterostomy. Ureteral reimplantation surgery was performed at the age of 1 year and 6 months. At the age of 6 years abdominal echography revealed bilateral hidronephrosis grade IV, which was confirmed by the uroMRI (figure 3) that we performed and stage 2 renal failure, shown by renal function tests.

Figure 1. Cystography at age of 3 months – right megaureter due to reflux.

Figure 2. Urography at age of 3 months – left ureterohydronephrosis due to obstruction.

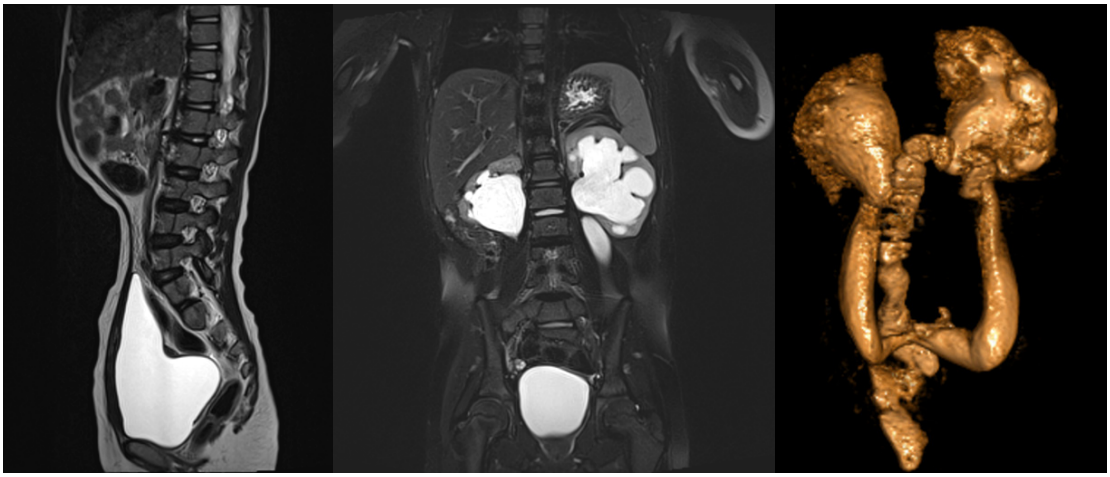

Figure 3. UroMRI aspect at age 6 years, showing distended neurogenic bladder and bilateral hydronephosis.

Clinical examination

Currently, on clinical examination she is pale, multiple scars from abdominal surgery, she is severely underweight (weight= 21 Kg; Height= 126 cm – 50th percentile for age WHO; BMI= 13.22 - below the 3rd percentile WHO) (4). Her blood pressure is = 100/70 mmHg – normal for gender, age and height (5). The maximum evacuated urinary volume was 400ml, while normal for her age would be 190ml. The clinical exam was otherwise normal.

Blood work:

The complete blood count was unremarkable, no anemia (Hemoglobin= 13,5g/dl) or other pathologies were detected. Electrolytes and blood gas remained in normal range. She presented normal serum protein level and normal lipid profile. In the last 12 months of follow-up the serum creatinine levels ranged between 43-72 µmol/l (normal), while blood urea nitrogen ranged between 5.5-7.7 mmol/l (normal). In the last year of management, she presented 4

episodes of urinary tract infections with Escherichia Coli that were treated with antibiotics.

Consults:

The neuropsichiatrist concluded she has a mild form of attention deficit disorder, learnig disability borderline intelect (IQ- *Raven's* Progressive Matrices=80) and agenesis of the corpus callosum. She recommended vitamin B supplement, an aiding professor and behavioral therapy. She is also in follow-up with the pediatric surgeon for neurogenic bladder, right megaureter due to reflux; left obstructive megaureter and CIC.

Treatment and follow-up:

The patient was started on intermittent bladder catheterization 4 times/day, done by the mother –who was very compliant and antibiotic prophylaxis. The patient's bladder emptying time was approximately 30 minute, variably influenced (shortened) by voluntary increasing abdominal pressure, through laughing or coughing. She is scheduled for monthly urine sample and urine culture and quarterly follow-up for blood work and clinical reevaluation. Echographic method of follow-up is reliable for medical examinations since it is informative, harmless and readily available, therefore applicable for this case. Figure 4 show the abdominal echography before and after CIC, reporting diminished hydronephrosis immediately after bladder emptying. The echographic follow-up after one year, in our patient, reported that the aspect remained mostly unchanged: left kidney had hydronephosis grade III, and the right kidney presented hydronephosis grade III/IV (6). Nevertheless, the parenchymatous index increased, which correlates with the improved renal function, from stage 2 renal failure (moderate reduction in glomerular filtration rate=58mL/min/1.73m^2) to normal glomerular filtration rate (glomerular filtration rate=94.17mL/min/1.73m^2). The blood urea nitrogen and creatinine levels slowly decreased in the 1 year period of follow-up. The urinary tract infection rate remained low. Her bladder emptying time has decreased from 30 to 25 minutes in the last year of CIC.

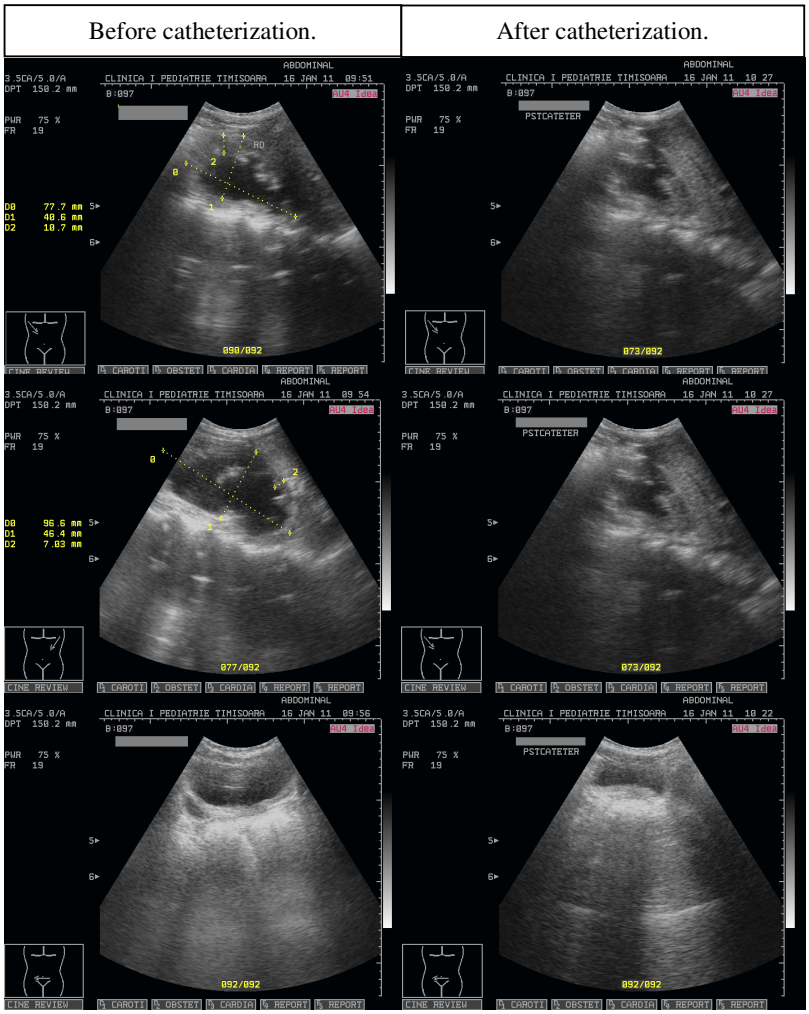

Figure 4. Abdominal echography (age 8 years) before and after the catheterization.

Discussions

The neurogenic bladder is a severe illness that seriously impairs the quality of life of patients, and at the same time, neurogenic bladder of retention type may represent a real threat to their life. The acute urinary retention is a condition resulted when the patient is unable to evacuate urine and may lead to bladder rupture through supradistension or/and vezico-ureteral reflux which leads to renal failure and even possibly exitus. A deficient management of avoiding – the absence of correct urinary catheterization regarding ritmicity, asepsis and antisepsis methods – represents a major cause of maintaining and aggravation of urinary tract infections, which may determine the impairment of the general state of the patient and eventually the potential loss of renal function – with poor prognosis (7). In addition, such patients may progress to bilateral hydronephrosis and end-stage renal insufficiency (8). CIC is considered the gold standard for bladder drainage because of the significantly decreased incidence of urinary tract infection in comparison with other catheterization methods (9). The principle in IC is the cvasicomplete and regular voidance of the bladder, resulting in a minimum post-mictional residuum and thus, maintaining a low intravesical pressure associated with a decreased risk of vezico-ureteral outflow (7).

Echographic anteroposterior measurements of hydronephrosis degree of the renal pelvis differs with a full bladder versus when the bladder is emptied (10). This is an important aspect to consider, because it can influence the accuracy of echographic estimation of hydronephrosis.

In order to evaluate the hydronephrosis and renal function during the last year, the patient was evaluated clinically, with laboratory work and with Imagistics. Abdominal echography has proven highly useful in the management of this case. Long-term intermittent catheterization as method of treatment for neurogenic bladder is associated with stable reflux status, renal function, and infection rate, which in the end results in better quality of life for the patient. However, the prognosis of this case remains reserved due to the chronic progressive renal disease. Kidney transplant is considered for this case.

Conclusions

Long-term intermittent catheterization as method of treatment and prevention is associated with stable reflux status, renal function, and infection rate, which in the end results in better quality of life for the patient. Echographic method of follow-up is reliable for medical examinations since it is informative, harmless and economical.

Ethical considerations

Written informed consent was obtained from the patient for publication of this case report and accompanying images.

References

1. Mizunaga M, Miyata M, Kaneko S, Yachiku S, Chiba K. Intravesical instillation of oxybutynin hydrochloride therapy for patients with a neuropathic bladder. Spinal Cord. 1994;32(1):25–9.
2. Lapides J, Diokno AC, Silber SJ, Lowe BS. Clean, intermittent self-catheterization in the treatment of urinary tract disease. J. Urol. 1972 Mar;107(3):458–61.
3. Mangnall J. Key considerations of intermittent catheterisation. Br J Nurs. 2012 Apr 12;21(7):392, 384, 396–8.
4. de Onis M, Garza C, Onyango AW, Rolland-Cachera M-F. [WHO growth standards for infants and young children]. Arch Pediatr. 2009 Jan;16(1):47–53.
5. The fourth report on the diagnosis, evaluation, and treatment of high blood pressure in children and adolescents. Pediatrics. 2004 Aug;114(2 Suppl 4th Report):555–76.
6. Fernbach SK, Maizels M, Conway JJ. Ultrasound grading of hydronephrosis: Introduction to the system used by the society for fetal urology. Pediatric Radiology. 1993 Oct;23(6):478–80.
7. Spinu A, Onose G, Daia C, Panţu C, Anghelescu A, Onose L, et al. Intermittent catheterization in the management of post spinal cord injury (SCI) neurogenic bladder using new hydrophilic, with lubrication in close circuit devices – our own preliminary results. J Med Life. 2012 Feb 22;5(1):21–8.
8. Sinha S. Dysfunctional voiding: A review of the terminology, presentation, evaluation and management in children and adults. Indian J Urol. 2011;27(4):437–47.
9. Carver MD. Adaptive equipment to assist with one-handed intermittent self-catheterization: a case study of a patient with multiple brain injuries. Am J Occup Ther. 2009 Jun;63(3):333–6.
10. Petrikovsky BM, Cuomo MI, Schneider EP, Wyse LJ, Cohen HL, Lesser M. Isolated fetal hydronephrosis: beware the effect of bladder filling. Prenat. Diagn. 1995 Sep;15(9):827–9.

Correspondance to:

Chirita Emandi Adela
"Louis Turcanu" Emergency Hospital for
Children Timisoara – Pediatrics Department,
Str Iosif Nemoianu nr 2-4,
300011,Timisoara,
Romania,
E-mail: adela.chirita@yahoo.com

UNUSUAL PRIMARY HYDATID CYST FROM SOFT TISSUE IN CHILDREN: FOUR CASES AND REVIEW OF LITERATURE

Muazez Cevik[1]

Abstract

Objective: Hydatid cyst (HC) is a zoonosis caused by the larval stage of the Echinococcus tapeworm. The location of HC is usually hepatic and/or pulmonary. In the present study was evaluated 4 patients with primary HC (PHC) related the literature. The present first the largest series of PHC of the soft tissue in the literature

Cases and Presentation: An experience of a single surgeon was conducted of 4 cases of primary HC of unusual regions of the body treated between 2004 and 2011. Locations were axillary fossa, popliteal fossa , and thoracic wall . Patients were admitted with an initial diagnosis of lipoma, lymphadenitis, or other cystic lesions. The definitive diagnosis of PHC was made peroperatively and related histopathological examination.

Conclusion: A PHC disease should be considered in the differential diagnosis of cystic lesions in every anatomic location, especially when patients have spent time in endemic areas for HC.

Key words: Hydatid cyst; primary; soft tissue; children; echinococcus

Introduction

The term "hydatid" has Greek origins and means "watery vesicle." Human echinococcosis was first described in ancient times by Hippocrates as "cysts full of water" in a human liver. [1,2]. There are six species of *Echinococcus* tapeworm, including *E. granulosus* (which causes cystic echinococcosis), *E. multilocularis* (which causes alveolar echinococcosis), *E. vogeli* and *E. oligarthus* (which cause polycystic echinococcosis), *E. shiquicus,* and *E. felidis*. *E. granulosus* is the most common *Echinococcus* parasite to infect man.[3] Dogs are the primary host of echinococcal infection, while intermediate hosts include sheep, cattle, and, occasionally, man. Hydatid cyst (HC) is most often found in rural areas. [4,5]. HC is endemic in Mediterranean countries, the Middle East, Far East, and south America.[2,6] Primary HC (PHC) from soft tissue is very rare.

Despite several important advances in the control of HC, this disease remains a major health problem in some countries. The PHC located in extremely rarely is seen in soft tissues even in which ecchinococcal infestation is frequent. In this report were reported to four rare cases had PHC in soft tissue as an uncommon site and review the literature.

Material and Methods

The medical records of unusual presentation primary HC as subcutaneous were reviewed. In addition, the English language literature was reviewed. We retrospectively identified all cases of HC managed by the pediatric surgery department at Sanliurfa public hospital, Sanliurfa, Turkey, a funding hospital, Mombasa, Kenya, Harran University, Medical Faculty hospital, Sanliurfa, Turkey during the years 2004 to 2011 (Table 1).

Table 1: Demographics and clinical features in patients related literature

Cases	Age/ Gender	Rural enivorment	Symptom	Location of HC	Previous diagnosis	Diagnosed with
Cangiotti L, et al[10]		Yes	Mass	Lumbar	No	After Surgery
Nath K et al.[8]	12/M	Yes	Mass	Neck	No	After Surgery
Marwah S et al.[12]	8/M	Yes	Mass	the tigh	Yes	USG, serology
Duygulu F, et al.[13]	8/F	Yes	Mass	The wall of thoraxThorax	Yes	MRI
Erol B, etal.[6]			Mass	tissue of calf mass	Yes	MRI
Ok E et al.[5]	12/f	unknown	Mass	neck	No	After Surgery
Cankorkmaz L et al.[7]	4/M	No	Mass	lumbar	Yes	MRI
Gupta R et al.[2]	12/F	Yes	Mass	Shoulder	No	Needle aspiration
Arslan S et al.[11]	5/M	No	Mass	Lumbar	Yes	USG
Our Case 1	7/F	Yes	Mass	Left axillar fossa	No	After Surgery
Our case 2	11/F	Yes	Mass	Right ant thorax wall	No	After Surgery
Our case 3	4/M	Yes	Mass	Popliteal Fossa	No	After Surgery
Our case 4	6/M	Yes	Mass	Left axillar Fossa	No	After Surgery

[1]Department of Pediatric Surgery Harran University Faculty of Medicine, Sanliurfa, Turkey
E-mail: cevikmuazzez@gmail.com

Case 1: A 7-year-old girl presented with a two-month history of a gradually enlarging swelling in the left axillary fossa and lived in a rural area. On physical examination, an about 3 cm in diameter a swelling was palpated at the left axillary fossa. It was ovoid in shape, painless, and mobile. Superficial ultrasonography (US) showed a 4 x 3.5cm mass in the subcutaneous tissue. Diagnosis with US was lymphadenopathy, and revealed no pathology in the internal organs. All laboratory tests were normal. The patient received antibiotic therapy and follow up for 1 month. In this period, the patient showed no clinical improvement. Therefore, the patient underwent elective surgery for mass excision. Surgical excision of the mass under general anesthesia and an elliptic incision was performed. And the mass was dissected with sharp dissection and perforated of capsule of mass and seen germinative membrane (Figure 1), and therefore a sponge soaked in povidone- iodine was placed around the cyst and cystic lesion was removed totally with capsule. The cavity was irrigated with povidone-iodine, and followed with saline. Histopathological examination of specimen revealed a HC. Albendazole 15 mg/kg was given for 3 months. Further investigations for other organ involvement were performed postoperatively to identify additional HC in different regions, and no other focus was found. No recurrence occurred for 12 month follow up.

Figure 1: View of the Germinative Membrane.

Case 2: An 11-year-old girl was admitted with 3-month history of a gradually enlarging swelling in the right side of the chest wall and lived in a rural area. On physical examination, a mobile mass situated right anterior thoracic wall between the fifth and sixth rib (Figure 2), with no other findings. Laboratory findings were nonspecific. Superficial US showed a 2 x 3 cm cystic mass, which was reported as lipoma (Figure 2). The patient underwent elective surgery for mass excision. Surgical excision of the mass performed with elliptic incision under general anesthesia and the mass was dissected with sharp dissection. During operation capsula of cystic mass was perforated and seen germinative membrane with cystic liquid. Therefore a sponge soaked in povidone- iodine was placed around the mass and cystic lesion was removed totally with capsule. The cavity was irrigated with povidone- iodine, and followed with saline. Histopathological examination confirmed the presence of hydatid cyst. Albendazole 15 mg/kg was given for 3 months. Further investigations were performed to identify additional HC in different regions, but none were found. No recurrence occurred for 12 month follow up.

Figure 2: View of preoperative of the patient.

Case 3: A 4-year-old boy presented with a three-month history of a painless mass located in the right popliteal fossa. The patient had had undergone needle aspiration one month prior to admitted into our clinic, and the mass continued to swelling. On physical examination, there was a soft mass and about 1.5 cm mass in diameter, round shape, and localize in the popliteal fossa. The patient underwent elective surgery for mass excision. Surgical excision of the mass performed with elliptic incision with sedoanalgesia and local anesthesia and the mass was dissected with sharp dissection, the mass was originated from under subcutaneose tissue and peroperation was perforated capsule of mass and seen germinative membrane and the macroscopic appearance suggested a HC . Therefore a sponge soaked in povidone- iodine was placed around the cyst and cystic lesion was removed totally with capsule. The cavity was irrigated with povidone- iodine, and followed with saline. Histopathological examination confirmed the presence of hydatid cyst. Albendazole 15 mg/kg was given for 3 months. No recurrence occurred for 1 month follow up.

Case 4: A 6-year-old male presented with a six-month history of a slow-growing swelling in the left axillar fossa and lived in rural area. Upon physical examination, a round, soft mass was observed. Laboratory findings were nonspecific. Superficial US demonstrated a 6 x 4 cm cystic mass arising from the subcutaneous tissue and diagnosed to cystic hygroma by US. The patient underwent elective surgery for mass excision. Surgical excision of the mass performed with elliptic incision with general anesthesia and the mass was dissected with sharp dissection. At surgical exploration, the cyst was arised from subcutaneouse tissue. Peroperatively, the mass was without perforated took from tissue and a sponge soaked in povidone- iodine was placed around the cyst to prevent enfestation and cystic lesion was removed totally with capsule The cavity was irrigated with povidone- iodine, and followed with saline. Histopathological examination confirmed the presence of hydatid cyst (Figure 3). Albendazole 15 mg/kg was given for 3 months. Further investigations were performed to identify additional HC in different region, but none were found. No recurrence occurred for 12 month follow up.

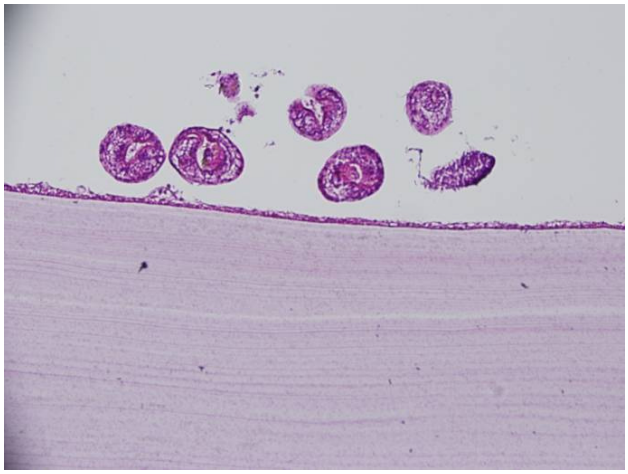

Figure 3: Histologic specimen of HC tissue; at the bottom, eosinophilic stained laminated and germinal membrane with many protoscolices in the lumen (stained H& x 200).

Discussions

In Pubmed, there was not any case under searching keywords :"Primary Cyst Hydatid,Subcutaneouse, Children" in english but there were 176 literature was about cutaneouse, subcutaneouse, muscle, with primary cyst hidatid that we assessed. This review yielded 9 reports of subcutaneous or smooth tissue with PHC in children. Most of them from neck, seconderly from lumbar, and then it may occur any part of body in muscle and diagnosed preoperativel by MRI.[6] In our series most of HC was seen in axillar region and all of them no preoperative diagnosis as HC. And also all our cases were from subcutaneouse tissue (Tablo 1).

HC is mostly diagnosed in adults.[1] Only a small percent of cases (10-20%) are diagnosed in patients younger than 16 years.[1,3] However, HC often infected to people during childhood and slow-growing (1-5 cm/year). HC located subcutaneously may see easily even when they are a small diameter. Therefore, the majority HC from soft tissue is diagnosed in children.[2,4,7,8]

Primary cysts are most often located in major organs, such as liver, lung, whereas HC located in other tissues typically occur in addition to primary cysts and are called secondary HC. The mechanism of primary subcutaneous HC is unclear.[7] The parasitic life cycle starts in the host after the accidental oral intake of *E. granulosus* eggs. Gastric and intestinal enzymes then help to release the oncosphere, which penetrates the duodenal wall and reach the liver via the portal vein.[5] After they trapped in the sinusoid of the liver therefore, the liver mostly involved organ (70%). The larvae which pass through this first filter, reach the lung via directly enter the bloodstream via anastomoses between intestinal vessels and the caval system, therefore, the lung is secondary involved organ (10-15%). As well as, the larvae travel along the lymphatic system into systemic circulation or some larvaes escape the hepatic-pulmonary filter and

cause HC in other end organs (5-15%).[9,10] The incidence of subcutaneous HC is unknown; however, the incidence of soft tissue involving subcutaneous HC, is low and ranges from 1 to 5.4% of all HC cases. [5,3] Most frequencly of these cases are associated with involved of other organs such as liver, lung. PHC of soft tissue without involved of liver and lung is extremely rare. Therefore, we found a few case in the literature and illustrated Table 1.

HC cause several clinical symptoms due to size of the HC and involved organ. Patients with PHC of soft tissue have nonspecific symptoms, so their accurate diagnosis is challenging. The diagnosis of HC is made with anamnesis, physical examination, imaging techniques, serologiacal tests (hemagglutination, complement fixation or enzyme linked immunosorbent assay, E.granulosus-specific IgE).[11,12] In the present study, patients had no signs of HC in the liver, lungs, or other parts of body and were misdiagnosed before the operation. The definitive diagnosis of HC was made peroperatively, when the germinal membrane of the cysts was seen and revealed the histopathology.

The basic treatment of HC is combined medical and surgery treatment.[11,13] Because of, removal of the primary cyst may not be totally effective, as smaller cysts can be left behind. Therefore, antihelmintic therapy is routinely prescribed to prevent recurrence. Recently, albendazol with percutaneous treatments have become widely available.[11] Several reports have demonstrated that only mebendazole is a highly effective treatment, as it penetrates deeply into the cyst and is known to reduce the risk of recurrence.[4] If we known preoperatively that our patients had HC, we would have treated them with albendazole, which would have avoided the need for surgery.

Easier, more effective, and more economic treatments are needed to prevent HC. Strategies, such as public education, strive to change risk behaviors and are succeeding in limiting and, in some cases, preventing the spread of the disease in humans.[4] Control of HC also entails treating infected dogs with antihelmintics and controlling illegal slaughtering of potentially infected livestock. The feeding of livestock entrails to dogs is a common way that these tapeworms are spread and should be avoided.[4]

In conclusion, HC should be considered in the differential diagnosis of cystic masses in endemic areas. Preoperative diagnosis of HC enables treatment by chemotherapy and avoids the need for surgery. In addition to good hygiene, prophylaxis of hydatidosis is very important, particularly in children, as most cases of HC start in childhood.

References

1. Turgut AT, Altin L, Topçu S, Kiliçoğlu B, Aliinok T, Kaptanoğlu E, et al. Unusual imaging characteristics of complicated hydatid disease. Eur J Rad. 2007;63: 84-93.
2. Gupta R, Mathur SR, Agarwala S, Kaushal S, Srivastav A. Primary soft tissue hydatidosis: aspiration cytological diagnosis in two cases. Diagn Cytopathol. 2008;36(12):884-6.
3. Celik A, Turanli M, Kutun S, Delibasi T, Mengi N, Comert E, et al. Unusual location of hydatid cyst: soft tissue mass in the neck. Eur Arch Otorhinolaryngol. 2006;263(12):1147-50.
4. Shah OJ, Robbani I, Zargar SA, Yattoo GN, Shah P, Ali S, et al. Hydatid cyst of the pancreas. An experience with six cases. J Pancreas. 2010;11:575-81.
5. Ok E, Sözüer EM. Solitary subcutaneous hydatid cyst: a case report. Am J Trop Med Hyg. 2000;62(5):583-4.
6. Erol B, Tetik C, Altun E, Soysal A, Bakir M. Hydatid cyst presenting as a soft-tissue calf mass in a child. Eur J Pediatr Surg. 2007;17(1):55-8.
7. Cankorkmaz L, Ozturk H, Koyluoglu G, Atalar MH, Arslan MS. Intermuscular hydatid cyst in a 4-year-old child: a case report. J Pediatr Surg. 2007;42(11):1946-8.
8. Nath K, Prabhakar G, Nagar RC. Primary hydatid cyst of neck muscles.Indian J Pediatr. 2002 ;69(11):997-8.
9. Safioleas M, Nikiteas N, Stamatakos M, Safioleas C, Manti CH, Revenas C, et al. Echinococcal cyst of the subcutaneous tissue. A rare case report. Parasitol Int. 2008;57:236-8.
10. Cangiotti L, Muiesan P, Begni A, Cesare V, Pouchè A, Giulini SM, et al. Unusual localizations of hydatid disease: a 18 year experience.1994;15(3):83-6.
11. Arslan S, Turan C, Sezer S, Tuna IS. Primary lumbar hydatid cyst: a case report. Turk J Pediatr. 2010;52(5):556
12. Marwah S, Subramanian P, Marwah N, Rattan KN, Karwasra RK. Infected primary intramuscular echinococcosis of thigh. Indian J Pediatr. 2005 Sep;72(9):799-800.
13. Duygulu F, Karaoğlu S, Erdoğan N, Yildiz O. Primary hydatid cyst of the thigh: a case report of an unusual localization. Turk J Pediatr. 2006;48(3):256-9.

Correspondance to:

Muazez Cevik
Department of Pediatric Surgery
Harran University Faculty of Medicine
TR-63000, Sanliurfa, Turkey
Fax: +90 (414) 318 33 50
E-mail: cevikmuazzez@gmail.com

THE IMPORTANCE OF PRELIMINARY ANESTHESIA UNDER GENERAL ANESTHESIA FOR ENT SURGERY IN CHILDREN

D Dumbravă[1], GhI Comşa[2]

Abstract

This study analyzes the importance of preliminary anesthesia under general anesthesia for ENT surgery in children, due to the high frequency of this kind of medical procedures in children and the particulary special psychological impact on child and family.

Key words: general anesthesia, medical procedures, ENT, children, Richmond scale, agitation.

Introduction

Most of the times, the ENT medical procedures in children are electrive procedures, often representing the first surgical experience in a child's life. In the U.S., for example, 250 000 (*two hundred and fifty thousand*) tonsillectomies (1) are performed annually. Therefore, the psyichological impact on children and their families is major. The causes of anxiety in pediatric patients are multifactorial, and most often due to the patient's inability to communicate effectively, to the existence of a hostile environment for children and the poor, distorted informing of parents. To limit the negative effects of anxiety on children, but also on their families, pacient's premedication is used. There are a number of ways this procedure can be done, without asking the parents to withdraw: orally; rectally; sublinguall; Injected, either intramuscular or intravenous.

Recent studies on the importance of pre-operative sedation(or preliminary anesthesia) show that pre- and postoperative agitation causes negative effects on patient, such as : disorders of ventilatory control, increased oxygen consumption, accidental removal of the probes and catheters or, especially in ENT surgery, increased risk of postoperative wound bleeding (2).

Material and Methods

After obtaining written informed consent of parents, we performed a prospective study in the ENT clinic of County Emergency Hospital Constanta over 249 patients, ASA I-III, aged 3 to 14 years old, hospitalized for scheduled or emergency interventions, which were divided in two large groups: those who received intravenous anesthesia and those who recieved inhalational anesthesia with sevoflurane. In both groups there were patients who received preliminary anesthesia and patients who did not. For induction of anesthesia are used: *sevoflurane administered* through a face *mask in group A, until the patient* enter the 3rd phase of anesthesia, venous line placement, administration of atropine 0.2 mg / kg, fentanyl 3 µg/ kg and then rocuronium 0.3 mg / kg. After the orotracheal intubation, maintaining has been done with Sevoflurane 2,5% and Oxygen 2 l/min. Awakening from anesthesia was spontaneous, without antagonisation, in all patients. In group B, after the venous line placement, same anesthetic technique was used, except that, instead of utilizing sevoflurane, a dose of 2.5 mg/kg IV propofol was given. Maintaining was done by reinjection of propofol and fentanyl boluses, awakening being also spontaneous. The rectal route of administration (ROA) was used in all patients who received pre-anesthetic medication, consisting of a dose of 0.2 mg/kg diazepam Desitin administered about 30 minutes before surgery. Exclusion criteria were known allergies to any anaesthetic agent, family history of malignant hyperthermia, coagulopaty and the legal guardian's refusal to sign consent.

The data obtained were statistically processed in MS Excel 2010 observing the following aspects: the age distribution of patients, the types of general anesthesia used in surgery, their length, as well as the influence of pre-anesthetic medication regarding the degree of early postoperative agitation and sedation.

Results and discussions

The collected data show a relatively uniform distribution over the range studied, presented in the following Table No. 1 and Fig. No. 1, with a maximum of 137 patients who received inhalational anesthesia.

In terms of type of general anesthesia used, distribution was clearly in favor of inhalational anesthesia (90 cases - 69.77%) in the age group 3-7 years, followed by intravenous anesthesia (39 cases - 30.23%); we noted in the age group 8-14 years, a high percentage of intravenous anesthesia (73 cases- 60.83%) compared to inhalational anesthesia (47 cases-39.17%). In Table No. 2 and Figure No. 2 we present the distribution by year and type of anesthesia, in the study group.

[1]County Emergency Hospital Constana, ph.D student at Ovidius University Constanta
[2]County Emergency Hospital Constana, ENT Clinic.
E-mail: ddumb2006@yahoo.com, geocomsa@yahoo.com

Table No.1 – Distribution of patients in the study group according to the general anesthesia types.

The type of anesthesia	No. of patients	Percent (%)
inhalational	137	55.02
i.v.	112	44.98

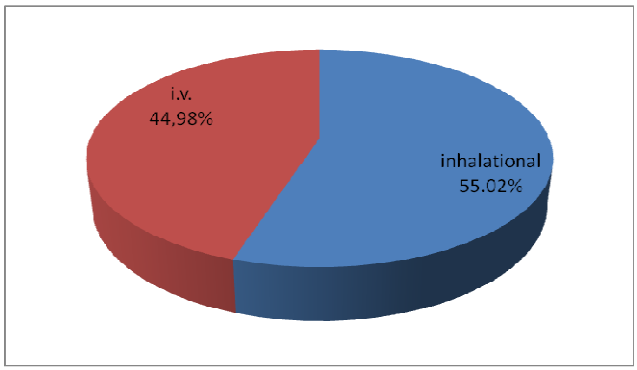

Fig. No. 1- Distribution by types of general anesthesia used.

Table No. 2-Distribution of patients by age and type of general anesthesia.

Age	2011	inhalational	percent(%)	iv	percent (%)
3-7 years	129	90	69.77	39	30.23
8-14 years	120	47	39.17	73	60.83

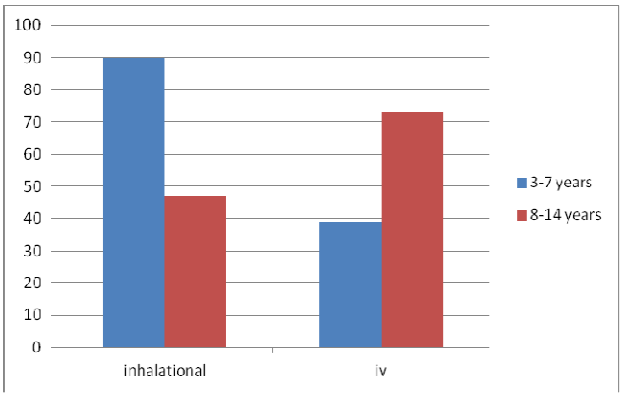

Fig. No. 2 - Distribution of patients by age and type of general anesthesia.

From the two main group: A (inhalational anesthesia) and B (IV anesthesia) , two quasiequal subgroups were selected consisting of a number of 68 patients who received pre-medication and 69 patients who have not in group A, and 57 vs. 55 in group B. The 249 patients in this study are pediatric patients with various pathologies, aged 3 to 14 years, who underwent surgery in the ENT Clinic of County Emergency Hospital Constanta in the first 8 month of 2011. The data are represented in Table No.3 and Figure No. 3.

Table No. 3-The distribution of patients according to the type of anesthesia and pre-anesthesia given.

	Group A	Percent (%)	Group B	Percent (%)
Pre-medication	68	49.64	57	50.89
Without pre-medication	69	50.36	55	49.11

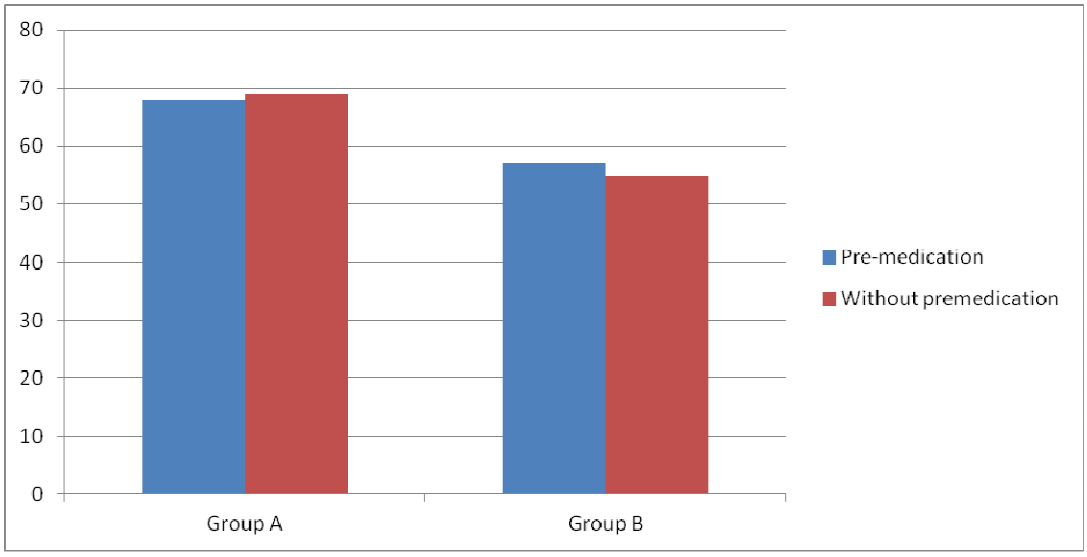

Fig. No. 3- The distribution of patients according to the type of anesthesia and pre-anesthesia given.

Medical studies reveal a number of scales evaluating the grade of sedation and agitation, such as: Riker scale, motor assessment scale, Ramsay scale and Richmond scale. To evaluate the selected patients in our study, we used the Richmond scale (3):

+4 – Combative; Combative, violent, danger to staff;
+3 - Pulls or removes tube(s) or catheters; aggressive;
+2 - Frequent nonpurposeful movement, fights ventilator;
+1 - Anxious, apprehensive , but not aggressive;
0 - Alert and calm
-1 - awakens to voi ce (eye opening/contact) >10 sec;
-2 - light sedation, briefly awakens to voice (eye opening/contact) <10 sec;
-3 - moderate sedation, movement or eye opening. No eye contact;
-4 - deep sedation, no response to voice, but movement or eye opening to physical stimulation;
-5 - Unarousable, no response to voice or physical stimulation.

The data obtained and presented in Table 4 and Figure 4 reveal an increased frequency of high-grade agitation in group aged 3 to7 years (10.08% - 4th grade, 14.73% - 3rd grade 20.16%-2nd grade) compared with group aged 8 to 14 years, where we noticed that with increasing age, the percentages are significantly reduced (4.48% - 4th grade, aged 8 to 10 and 1.49%,aged 11 to 14 , 7.46% - 3rd grade, aged 8 to 10 and 4.48% aged 11 to 14 , and , finally, 11.94% - 2nd grade, aged 8 to 10 and 7.46%, aged 11-14).

Table No. 4 – Agitation assessment based on Richmond scale, divided by age group.

Richmond Scale	3-7 years	%	8-10 years	%	11-14 years	%
4	13	10.08	3	4.48	1	1.49
3	19	14.73	5	7.46	3	4.48
2	26	20.16	8	11.94	5	7.46
1	31	24.03	22	32.84	19	28.36
0	4	3.10	8	11.94	8	11.94
-1	11	8.53	7	10.45	9	13.43
-2	13	10.08	6	8.96	5	7.46
-3	8	6.20	6	8.96	2	2.99
-4	4	3.10	2	2.99	1	1.49
-5	0	0.00	0	0.00	0	0.00
Total	129		67		53	

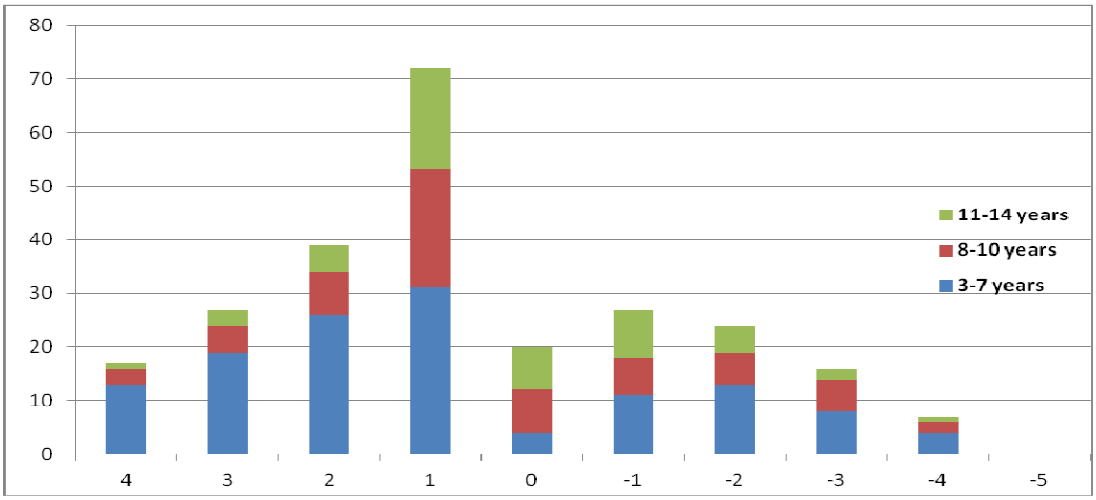

Fig. No. 4 – The distribution of patients according to age group and the stage of agitation.

In Table No. 5 we present the statistics results of the two large groups A and B, as well as the results of the subgroups, ranking sedated and unsedated patients. In the group aged 3 to 7, by comparing patients who underwent sedation and those who have not (1.47% vs. 4.35% - 4th grade and 7.35% vs. 14.49% - 3rd grade), we noticed a clear difference in the percentage of patients ranked in dangerous agitation groups (4th and 3rd). In the group aged 8 to 14 there is a difference, but a significantly lower one, between the two subgroups (1.75% vs. 1.82% - 4th grade and 5.26% vs. 7.27% - 3rd grade). Analysis of statistics results shows a major variation in the proportion of patients classified in groups +1, 0, -1 , between the group of patients aged 3 to 7 and the second one aged 8 to 14 (25% vs. 24.56% - 1st grade , 7.35% vs. 15.79% - 0 grade and 10.29% vs. 19.39% - grade -1). This difference can be explained primarily by specific psychological changes that occur at different ages.

Table No. 5 – distribution of patients depending on age and premedication.

Richmond Scale	Group A Premedicated	%	Lot A un-premedicated	%	Lot B premedicated	%	Lot B un-premedicated	%
4	1	1.47	3	4.35	1	1.75	1	1.82
3	5	7.35	10	14.49	3	5.26	4	7.27
2	10	14.71	13	18.84	5	8.77	8	14.55
1	17	25.00	15	21.74	14	24.56	12	21.82
0	5	7.35	2	2.90	9	15.79	7	12.73
-1	7	10.29	6	8.70	11	19.30	10	18.18
-2	13	19.12	12	17.39	8	14.04	6	10.91
-3	8	11.76	7	10.14	5	8.77	6	10.91
-4	2	2.94	1	1.45	1	1.75	1	1.82
-5	0	0.00	0	0.00	0	0.00	0	0.00
TOTAL	68		69		57		55	

Conclusions

1. The degree of postoperative agitation is significantly influenced by the child's age and socio-cultural background;
2. The preoperative sedation gives a much more stronger sense of comfort to both child and parents';
3. In our study, at group aged 3 to 7 , there was a clear difference regarding the reduction of postoperative agitation in patients who recived premedication, compared to the ones who have not , noting that in the patients group aged 8 to 14, this difference significantly diminishes.

References

1. Shinhar S, Scotch BM, Belenky W, Madgy D, Haupert M. Harmonic scalpel tonsillectomy versus hot electrocautery and cold dissection: an objective comparison. Ear Nose Throat J. 2004;83(10):712-715.
2. Fraser GL, Riker RR, Prato BS, et al. The frequency and cost of patient-imitiated device removal in the ICU. Pharmacotherapy 2001;21:1-6.
3. De Jonghe B, Cook D, Appere-De-Vecchi C, et al. Using and understanding sedation scoring systems: A systematic review. Intensive Care Med 2000;26:275-285.
4. Zdrehuş C. Recomandări pentru sedare şi analgezie la pacientul critic. În recomandări şi protocoale în anestezie, terapie intensivă şi medicină de urgenţă 2009.

Correspondance to:
Dumbravă Daniel
145, Tomis Bvd.
Constanţa,
Romania,
Phone: +4 0745 777816
E-mail: ddumb2006@yahoo.com

ACUTE PHASE REACTANTS AND CYTOKINES IN THE EVALUATION OF NEONATAL SEPSIS

Mirabela Dima[1*], C Ilie[1], Marioara Boia[1], Daniela Iacob[1], RE Iacob[2], Aniko Manea[1], Nicoleta Ionita[3]

Abstract

In the latest years, biochemical markers are important in research areas in neonatal infections. Inflammatory cascade as response to an infection comprise many elevated markers, frequently used for diagnosis and monitoring of sepsis. White blood cells release cytokines and chemokines and others mediators which regulate inflammatory process. Interleukin-6 (Il-6) and interleukin-8 (Il-8) are considered markers of *early-onset neonatal sepsis*. Late-onset neonatal sepsis in newborn infants is sepsis that occurs after the first 72 hours of life and is a major cause of infant mortality. C-reactive protein, procalcitonin and hepcidin, released as a consequence of increased cytokine activity are considered markers of *late-onset neonatal sepsis*. Mannose-binding lectin (MBL) is a collagenous protein involved in innate immunity of neonates and a useful marker of infection. Early diagnosis and prompt intervention are essential to prevent morbidity and mortality in neonates (<28 days of age) and infants (>28 days of age) with sepsis.

Key words: interleukin 6, interleukin 8, procalcitonin, cytokines

Introduction

Neonatal sepsis occurs from 1 to 21 newborns out of 1 000 live births with mortality rates as high as 30% up to 69% and the "gold standard" for the neonatal diagnosis of sepsis is a positive microbiological culture (1,2). Neonatal sepsis is defined as a clinical syndrome characterized by bacteremia with systemic signs and symptoms of infection in the first 4 weeks of life (3). The diagnosis of sepsis includes also urine, cerebrospinal fluid, or bronchial fluid specimens and usually takes 24 to 48 hours (4,5). Data from the National Institute of Child Health and Human Development Neonatal Research Network reported mortality rates with gram-negative infections at 36% and 32% with fungal infections (6). In clinical practice a rapid diagnosis of neonatal sepsis is difficult, because the clinical manifestations of this condition can overlap with those of non-infectious conditions, such as the meconium aspiration syndrome, respiratory distress syndrome, and hemodynamic instability of various underlying etiologies (7).

Newborns are frequently evaluated after the principle "rule out sepsis". In United States, it was reported that 15% of term newborn undergo this evaluation (7,8). Based on the timing of presentation, neonatal sepsis is classified as either early or late. In the literature, however, there is no definitive consensus as to what age limits apply, with early-onset sepsis ranging from 48 hours to 6 days after delivery (9). Late-onset sepsis generally occurs beyond the first week of life. The clinical relevance of this distinction is that early-onset disease is often due to organisms acquired during delivery (10).

Although no significant sex difference has been reported, it was observed that male infants had a higher incidence of neonatal sepsis than females, which may be related to X-linked immunoregulatory genes (11). The bacteria that cause neonatal sepsis are acquired shortly before, during, and after delivery (12). The results of blood culture are usually available only after a delay of about two days, thus necessitating initial empirical treatment for suspected cases (13). The adaptive immune system of neonates, particularly of preterm infants, is severely impaired because of immature B and T cell function (14,15).

An earlier diagnosis by laboratory markers could reduce the incidence and high mortality rate through neonatal sepsis (4). CRP, white blood cell count, absolute neutrophil count, and immature/total neutrophil ratio are the most widely used tests in the diagnosis of neonatal sepsis (5). Procalcitonin and mannose-binding lectin are probably more sensitive and specific for detecting the early stages of bacterial infections than traditional inflammation indicators such as Erythrocyte Sedimentation Rate or CRP (17). The advantages of peripheral circulatory measurements as diagnostic markers are that 1) they can be done rapidly and noninvasively, 2) the measurements are reproducible shortly after birth, and 3) the result of the test is available immediately (18).

[1]University of Medicine and Pharmacy "Victor Babes" Timisoara, Romania
[2]County Emergency Hospital Arad – Department of Pediatric Surgery, Arad, Romania
[3]Clinical Emergency Hospital, Timisoara, Romania
***Research supported by PhD fellowship POSDRU107/1.5/S/ID 78702**
E-mail: dima_mirabela@yahoo.com, constantinilie@umft.ro, marianaboia@yahoo.com, danielariacob@yahoo.com, radueiacob@yahoo.com, aniko180798@yahoo.com, ionita_nicoll@yahoo.com

Furthermore, a number of other acute-phase proteins including fibronectin, granulocyte colony–stimulating factor, and α_1-antitrypsin have been evaluated as diagnostic markers for neonatal sepsis. Although all could be used as markers for diagnosing sepsis, none has been routinely studied on a large scale or in the clinical setting (6).

Acute Phase Reactants

C-Reactive Protein

C-reactive protein (CRP) is one of the most studied and used laboratory tests for neonatal sepsis. The utility of CRP for the diagnosis of early-onset neonatal infection has been the subject of controversy because of its unsatisfactory sensitivity (19). The delayed synthesis during the inflammatory response accounts for its low sensitivity during the early phases of the disease (20). Upon resolution of the inflammation, CRP levels rapidly decline with an elimination half-life of 19 hours (21). A study compared six inflammatory mediators: CRP, interleukin-6 (IL-6), soluble tumor necrosis factor receptors (p55 and p75) and soluble adhesion molecules (ICAM-1, E-selectin) as early diagnostic tests for neonatal sepsis, and studied the possible benefit of combining parameters (22). CRP proved to be best diagnostic test for neonatal sepsis, the diagnostic accuracy was improved by combining CRP and IL-6, but other parameters (p55, p75, ICAM-1 and E-selectin) added no further diagnostic information (22). The cut-off levels of CRP may vary among authors from 5 to 50 mg/l (23-25). Another study evaluated CRP levels in four hundred and twenty neonates with clinical suspicion of sepsis over a 6 month period. They concluded that the qualitative method of estimating CRP has moderate sensitivity, specificity and negative predictive value (21). Another recent study tried to find out the role of hematologic scoring system (HSS), CRP and haptoglobin in the early diagnosis of neonatal septicemia. They observed that HSS and CRP are useful test to differentiate the septicemic from non septicemic neonates and help in decisions regarding judicious use of antibiotic therapy, but haptoglobin level was not found useful for screening of sepsis (26). Recently, a study compared the diagnostic accuracy of neutrophil CD_{64} and CRP as a single test for the early detection of neonatal sepsis and the authors observed that the diagnostic accuracy of CD_{64} is superior to CRP when measured at the time of suspected sepsis (27). On the contrary, a study reported that implementation of an algorithm based on the determination of IL-6 and CRP, in the initial assessment of the newborn with clinical suspicion of infection, could reduce unnecessary antibiotic therapy.

Procalcitonin

Lately, procalcitonin (PCT) has acquired, especially in Europe, an important role in the diagnosis of bacterial infection in both pediatric and adult population (29). PCT, one of the precursors of calcitonin, is a 116 amino acid peptide, physiologically produced and secreted in the thyroid gland and secreted into the blood circulation during infection, without increasing calcitonin (25). PCT is detectable in the plasma as early as 2 h after the exposure to the bacterial products; its level rises for 6 to 8 h, reaches a plateau after 12 h, and then decreases to a normal level after 2 to 3 days. A cut-off of 0.5 ng/ml starting from the third day of life appears to be capable of ensuring good test sensitivity and specificity. Furthermore, non-infective perinatal events, such as intracranial hemorrhage, perinatal asphyxia, respiratory disorders, and fetal distress, may increase PCT concentrations.

A study that compared the diagnostic value of PCT and CRP in neonatal sepsis, observed that PCT is a useful, sensitive and independent biomarker of neonatal sepsis, but measurement of both CRP and PCT may increase the specificity (30). A study reported that the serum PCT concentration showed a good diagnostic value for the early detection of neonatal sepsis of vertical transmission compared to traditional inflammatory mediators, such as IL-6 and CRP values. On the contrary, some studies found that the sensitivity of PCT is low (70%–80%) to rule out sepsis at birth (4,5). PCT and CRP thresholds for the diagnosis of sepsis were 5.38 ng/ml (sensitivity 83.3%, specificity 88.6%) and 12 mg/l (sensitivity 76.4%, specificity 78.9%) at 24 h of age (31). Although CRP and PCT are accepted sepsis markers, there is still some debate concerning the correlation between their serum concentrations and sepsis severity (8). The measurement of procalcitonin can also help differentiation between bacterial and viral infection, therefore it has been introduced in many European protocols for the management of febrile children (31).

Hepcidin

Hepcidin is an acute-phase reactant that plays a critical role in inflammation and iron homeostasis (33). Although hepcidin has an important role in anemia, there is a known relationship between iron metabolism and innate immunity. It is already known that synthesis of hepcidin is up-regulated by lipopolysaccharide and interleukin-6. Recently, it was reported that serum hepcidin concentration may be a useful adjunct test, in addition to blood culture and other markers of infection, in the evaluation of late-onset sepsis in very low birth weight infants.

Mannose-binding lectin (MBL)

Mannose binding lectin (MBL) is an acute phase protein produced by the liver that activates the lectin pathway of the complement system by binding to various microorganisms, which leads to enhanced phagocytosis. Furthermore, MBL binds to mannose and other sugar residues present on the cell wall of bacteria, viruses and parasites with high affinity. A study investigated the relationship between MBL gene polymorphism and early neonatal outcome in preterm infants. They found out that MBL gene polymorphism was associated with early neonatal sepsis and increased frequency of patent ductus arteriosus in infants. Single-nucleotide polymorphisms in exon 1 of the MBL_2 gene are responsible for altered MBL serum levels and impaired function (7). Other study suggested that low MBL concentrations are a risk factor for sepsis associated with infections with Gram-positive but not Gram-negative bacteria (14). A study showed that low MBL levels and presence of B allele of MBL exon 1 gene are

important risk factors for development of both neonatal sepsis and pneumonia, especially in premature infants. Recently was reported that newborns with low MBL levels appear to have culture-confirmed sepsis more frequently than MBL-sufficient newborns.

Cytokines and Chemokines

Cytokines, small molecules secreted by lymphocytes and monocytes are thought to be endogenous mediators of the immune response to bacterial infections, while chemotactic cytokines, collectively known as chemokines, appear to have the capacity to control the movement of leukocytes and are important elements in this process. Elevated levels of cytokines and chemokines can be detected in umbilical blood of the neonates with sepsis and are considered sensitive and specific markers of acute infection. Elevated serum levels of some cytokines like interleukin-6, interleukin-8 or tumor necrosis factor α may precede the increase of CRP and may stimulate the hepatocytes for increased CRP production.

Interleukin-6

Another marker that has gained much attention more recently is interleukin-6 (Il-6). Il-6 is produced by monocytes, endothelial cells and fibroblasts (24). The advantage of measurement of Il-6 is that it rises at the onset of infection while CRP reaches the maximum concentration with a noticeable delay. Cord blood Il-6 rather than CRP is a better predictor to initiate treatment in neonates with prenatal infectious risk factors immediately after birth. Furthermore, elevated concentrations of Il-6 and CRP are risk factors for preterm birth < 32 weeks. A recent study found that the optimal cut-off value of Il-6 for diagnosis of neonatal sepsis is 24.65 pg/ml (30). On the contrary, another study found out that the optimal cut-off value of Il-6 for diagnosis of neonatal sepsis is 40.5 pg/ml. The sensitivity of Il-6 assay ranged from 0.61 to 0.96 (23). Higher serum level of PCT, hs-CRP, and Il-6 were reported in neonates with sepsis compared to those without sepsis (25). Furthermore, the concentration of Il-6 in preterm and term infants does not seem to be influenced by gestational age or maternal cytokine concentration (24). IL-6, IL-10 and oxidative parameters in umbilical cord blood contribute as an indicator of neonatal sepsis in recognized high-risk neonates (3). Therefore, Il-6 can be used as an important marker for *early-onset neonatal sepsis* in neonatal care units.

Interleukin-8 (IL-8)

IL-8 is a pro-inflammatory cytokine predominantly produced by monocytes, macrophages, and endothelial cells, has a role in release, activation and chemotaxis of neutrophils and rises early in the course of neonatal bacterial infections. The cut-off value for diagnosis of neonatal sepsis is IL-8 > 60 pg/ml. Interleukin-8 is considered to be an accurate marker, with sensitivities ranging from 80% to 91% and specificities from 76% to 100% (6).

It was reported that the use of multiple markers as CRP, PCT, IL-6 and Il-8 is useful both to early (24-48 h) diagnose of neonatal sepsis, and to monitor the antibiotic treatment while waiting for the results of cultural examinations (2). It was reported that IL-8 may be a valid and early predictive marker of neonatal infection that is associated with severity of infection.

Tumor necrosis factor α (TNF-α)

TNF-α is one of the primary agents which sets in motion the exaggerated cellular, metabolic, and vascular responses of sepsis. TNF binds to specific receptors (p55, p75) on target cells, which also exist as soluble isoforms (22). A study detected that sensitivity, specificity and diagnostic efficacy values of IL-6, CRP and IL-8 are lower than PCT and TNF-α (18).

Cytokines and chemokines such as Il-6 and Il-8 have good diagnostic utilities as early phase markers, while acute phase reactants such as C-reactive protein, procalcitonin, hepcidin and mannose-binding lectin have superior diagnostic properties during the later phases.

Conclusions

Combination assay of serum levels of cytokines like interleukin-6, interleukin-8 or tumor necrosis factor α and acute-phase reactants like C reactive protein, procalcitonin, hepcidin and mannose-binding lectin seems to be useful as a part of diagnostic work up for neonatal sepsis, but also in following the effectiveness of treatment and determining the prognosis of the disease.

References

1. Miguel, D., et al., *Cord blood plasma reference intervals for potential sepsis markers: pro-adrenomedullin, pro-endothelin, and pro-atrial natriuretic peptide.* Clin Biochem, 2011. **44**(4): p. 337-41.
2. Zuppa, A.A., et al., *[Evaluation of C reactive protein and others immunologic markers in the diagnosis of neonatal sepsis].* Minerva Pediatr, 2007. **59**(3): p. 267-74.
3. Carvalho, N.C., et al., *Comet assay in neonatal sepsis.* Indian J Pediatr, 2010. **77**(8): p. 875-7.
4. Mussap, M., *Laboratory medicine in neonatal sepsis and inflammation.* J Matern Fetal Neonatal Med, 2012. **25 Suppl 4**: p. 32-4.
5. Benitz, W.E., *Adjunct laboratory tests in the diagnosis of early-onset neonatal sepsis.* Clin Perinatol, 2010. **37**(2): p. 421-38.
6. de Assis Meireles, L., A.A. Vieira, and C.R. Costa, *[Evaluation of the neonatal sepsis diagnosis: use of clinical and laboratory parameters as diagnosis factors].* Rev Esc Enferm USP, 2011. **45**(1): p. 33-9.

7. Escobar, G.J., et al., *Neonatal sepsis workups in infants >/=2000 grams at birth: A population-based study.* Pediatrics, 2000. **106**(2 Pt 1): p. 256-63.
8. Escobar, G.J., *What have we learned from observational studies on neonatal sepsis?* Pediatr Crit Care Med, 2005. **6**(3 Suppl): p. S138-45.
9. Vergnano, S., et al., *Neonatal sepsis: an international perspective.* Arch Dis Child Fetal Neonatal Ed, 2005. **90**(3): p. F220-4.
10. Srinivasan, L. and M.C. Harris, *New technologies for the rapid diagnosis of neonatal sepsis.* Curr Opin Pediatr, 2012. **24**(2): p. 165-71.
11. *Neonatal-perinatal medicine: diseases of the fetus and infant.* Arch Dis Child, 1978. **53**(8): p. 696.
12. Edmond, K. and A. Zaidi, *New approaches to preventing, diagnosing, and treating neonatal sepsis.* PLoS Med, 2010. **7**(3): p. e1000213.
13. Zakariya, B.P., et al., *Risk factors and predictors of mortality in culture proven neonatal sepsis.* Indian J Pediatr, 2012. **79**(3): p. 358-61.
14. Schlapbach, L.J., et al., *Differential role of the lectin pathway of complement activation in susceptibility to neonatal sepsis.* Clin Infect Dis, 2010. **51**(2): p. 153-62.
15. Kenzel, S. and P. Henneke, *The innate immune system and its relevance to neonatal sepsis.* Curr Opin Infect Dis, 2006. **19**(3): p. 264-70.
16. Altunhan, H., et al., *Procalcitonin measurement at 24 hours of age may be helpful in the prompt diagnosis of early-onset neonatal sepsis.* Int J Infect Dis, 2011. **15**(12): p. e854-8.
17. Lu, C.Y. and P.N. Tsao, *Protect the unprotected: neonatal sepsis in very-low-birth-weight infants.* Pediatr Neonatol, 2012. **53**(4): p. 217-8.
18. Martin, H. and M. Norman, *Skin microcirculation before and after local warming in infants delivered vaginally or by caesarean section.* Acta Paediatr, 1997. **86**(3): p. 261-7.
19. Chiesa, C., et al., *C reactive protein and procalcitonin: reference intervals for preterm and term newborns during the early neonatal period.* Clin Chim Acta, 2011. **412**(11-12): p. 1053-9.
20. Hofer, N., et al., *An update on the use of C-reactive protein in early-onset neonatal sepsis: current insights and new tasks.* Neonatology, 2012. **102**(1): p. 25-36.
21. West, B.A., et al., *Prospective evaluation of the usefulness of C-reactive protein in the diagnosis of neonatal sepsis in a sub-Saharan African region.* Antimicrob Resist Infect Control, 2012. **1**(1): p. 22.
22. Dollner, H., L. Vatten, and R. Austgulen, *Early diagnostic markers for neonatal sepsis: comparing C-reactive protein, interleukin-6, soluble tumour necrosis factor receptors and soluble adhesion molecules.* J Clin Epidemiol, 2001. **54**(12): p. 1251-7.
23. Martin, H., B. Olander, and M. Norman, *Reactive hyperemia and interleukin 6, interleukin 8, and tumor necrosis factor-alpha in the diagnosis of early-onset neonatal sepsis.* Pediatrics, 2001. **108**(4): p. E61.
24. Shahkar, L., et al., *The role of IL-6 for predicting neonatal sepsis: a systematic review and meta-analysis.* Iran J Pediatr, 2011. **21**(4): p. 411-7.
25. Abdollahi, A., et al., *Diagnostic Value of Simultaneous Measurement of Procalcitonin, Interleukin-6 and hs-CRP in Prediction of Early-Onset Neonatal Sepsis.* Mediterr J Hematol Infect Dis, 2012. **4**(1): p. e2012028.
26. Khair, K.B., et al., *Early diagnosis of neonatal septicemia by hematologic scoring system, C-reactive protein and serum haptoglobin.* Mymensingh Med J, 2012. **21**(1): p. 85-92.
27. Choo, Y.K., et al., *Comparison of the accuracy of neutrophil CD64 and C-reactive protein as a single test for the early detection of neonatal sepsis.* Korean J Pediatr, 2012. **55**(1): p. 11-7.
28. Santuz, P., et al., *Procalcitonin for the diagnosis of early-onset neonatal sepsis: a multilevel probabilistic approach.* Clin Biochem, 2008. **41**(14-15): p. 1150-5.
29. Naher, B.S., et al., *Role of serum procalcitonin and C-reactive protein in the diagnosis of neonatal sepsis.* Bangladesh Med Res Counc Bull, 2011. **37**(2): p. 40-6.
30. Celik, I.H., et al., *Value of different markers in the prompt diagnosis of early-onset neonatal sepsis.* Int J Infect Dis, 2012. **16**(8): p. e639.
31. Gomez, B., et al., *Diagnostic value of procalcitonin in well-appearing young febrile infants.* Pediatrics, 2012. **130**(5): p. 815-22.

Correspondance to:

Dima Mirabela,
University of Medicine and Pharmacy "V. Babes" Timisoara
P-ta E. Murgu, No. 2,
Timisoara,
Romania,
E-mail: dima_mirabela@yahoo.com

POLYORCHIDISM: A CASE REPORT AND REVIEW OF THE LITERATURE

I Skondras[1], C Velaoras[1], C Erikat[1], I Alexandrou[1], E Christianakis[1]

Abstract

We report the case of a 21-month-old boy who was referred for the surgical management of a left undescended testis. A preoperative ultrasound examination was negative for supranumerary testis. Surgery revealed complete separation of the epididymis from the testis; one well-developed testis was found in the internal ring of the inguinal canal. A second atrophic testis was also detected in the inguinal canal and this was removed. Histological evaluation revealed the presence of an atrophic, undeveloped testis with its own epididymis and spermatic duct. The risk of malignancy in polyorchidism warrants the removal of an atrophic and ectopic testis.

Key words: Undescended testis, polyorchidism

Introduction

The presence of more than two testes confirmed by histopathology is known as polyorchidism. The first histologic reference to this condition was made in 1880 and the first confirmed case was described by Lane in 1895 [1]. The majority of cases involve triorchidism with occasional bilateral duplication [2]. Over 100 histologically confirmed cases have been reported in the literature, of which half had spermatogenic potential [3]. Despite advancements in imaging modalities and their widespread use, diagnosis is usually incidental as polyorchidism is generally identified during surgery. It is not uncommon for the condition to be associated with other anomalies including cryptorchidism (40%), inguinal hernia (30%), testicular torsion (15%), hydrocele (9%) and neoplasia (6%) [4]. Fifty per cent of cases are diagnosed between the age of 15 and 25 years [1].

Case presentation

A 21-month-old boy was admitted to our department for surgical management of left cryptorchidism. He had undergone surgery 3 months earlier for right orchidopexy due to congenital cryptorchidism. On clinical examination the right testis was found within the hemiscrotum while the left was palpable in the upper third of the inguinal tract, which concurred with the finding of the preoperative ultrasound examination. At surgery, an incision was made to the inguinal canal. Surgical preparation of the spermatic cord elements uncovered the presence of a small atrophic testis with vestigial epididymis and normal spermatic duct. Despite the evident testicular hypoplasia, the preoperative findings prompted us to explore the internal inguinal ring for a palpable mass. Downward traction of the spermatic cord elements and the pressure exerted along the inguinal canal revealed another testicle of standard size with normal epididymis and duct which apparently was a third testis (pics. 1,2); fortunately, after surgical dissection and mobilization to the ipsilateral hemiscrotum it had achieved fixation, following excision of the atrophic testis. Histologic examination confirmed the presence of an undeveloped testis with its own epididymis, spermatic cord and duct but without testicular cannulas (pics. 3,4)

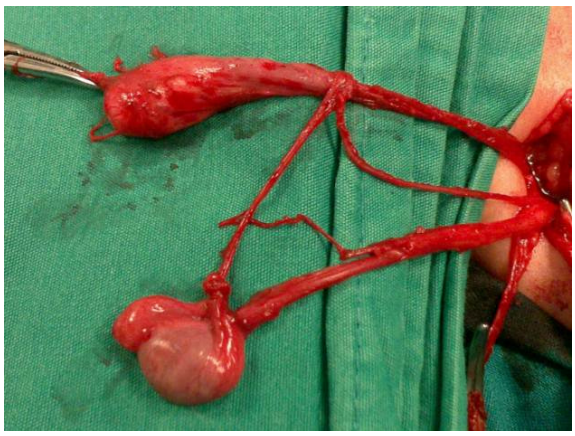

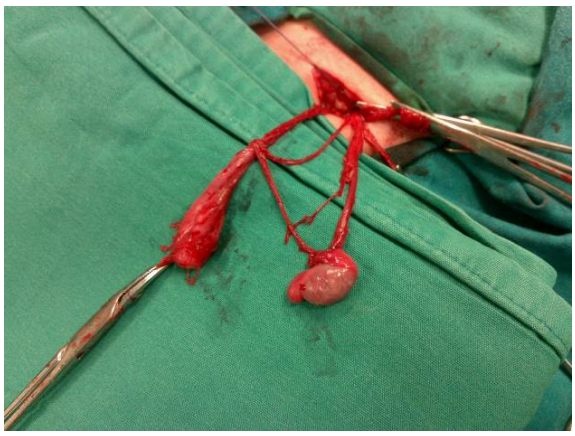

Pictures 1, 2. Surgical specimen.

[1]Paediatric Surgical Department, Penteli Children's Hospital
E-mail: skondras@yahoo.gr, kvelaoras@yahoo.gr,erikatkhalil@yahoo.gr,
Inalexantrou@hotmail.com, xristianakis@yahoo.gr

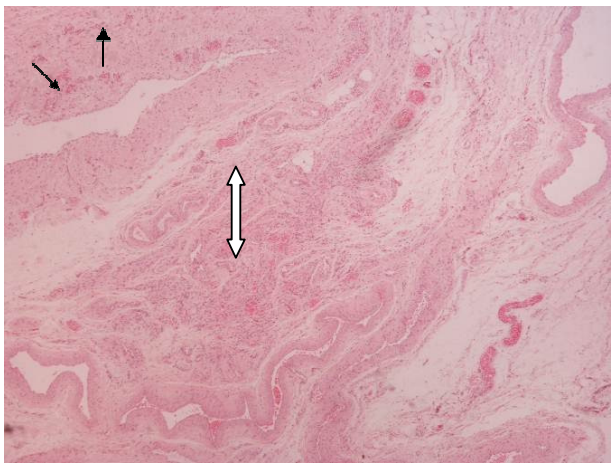

Picture 3: Surgical specimen of cryptorchidism. Undeveloped testis in the place of which a dense capillary network can be seen in a substroma of connective tissue (double arrow).Visceral tunica vaginalis lined by mesothelial cells (thin arrows H-E x400).

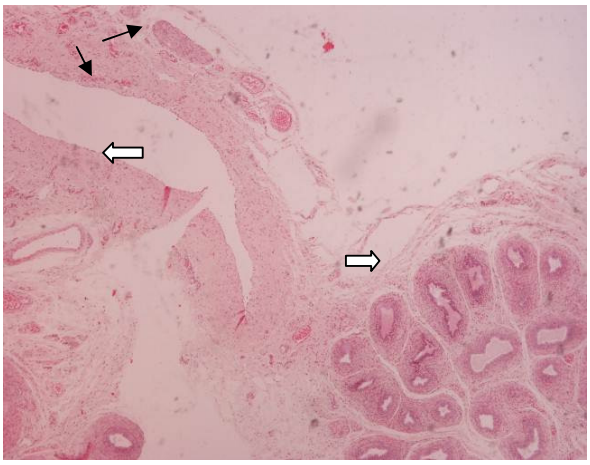

Picture 4: Surgical specimen of cryptorchidism. Epididymis (right arrow), vascular connective tissue (undeveloped testis) (left arrow) and thin stroma of mesothelial cells that line visceral tunica vaginalis. (thin arrows H-E x400).

Discussion

With only 100 cases reported in the literature, polyorchidism constitutes a rare condition that is thought to stem from the abnormal division of the genital ridge during fetal development [5]. Generally an incidental finding at surgery, its most common form is thriorchidism, although there are some reported cases of as many as five or even six testes [6] About 75% of supranumerary testes are intrascrotal and patients normally present with an unusual scrotal mass. Another 20% are found within the inguinal canal while 5% are located in the retroperitoneal space [7]. Testicular duplication must be differentiated from transverse testicular ectopia where both healthy testes migrate from the inguinal canal to the same hemiscrotum [8]. Polyorchidism is often associated with other anomalies including cryptorchidism (40%), inguinal hernia (30%), testicular torsion (15%), hydrocele (9%) and neoplasia (6%) [4] without any evidence to date of chromosomal abnormality [9]. A 66% prevalence is noted for left-sided lesions and 20% for the right while 14% are bilateral [1].

Thirty-seven per cent of numerary testes display tubular atrophy and lack of spermatogenic potential [1,10]. According to the literature, malignancy has been reported in 4-7% of cases [11]. However, it is difficult to establish its precise incidence given the rarity of the condition and frequent coexistence of congenital cryptorchidism [12]. Theories surrounding the embryologic origin of polyorchidism include the degeneration of mesonephric components and duplication or division of the genital ridge [13-16]. The most plausible explanation is the transverse division of the urogenital ridge at 4th to 6th week of pregnancy. The theory related to degeneration of mesonephric components has been rejected on the basis that this does not appear to influence the genital ridge nor the developing testicle [14,16,17]. Duplication can only account for some of the anatomic variations whereas division can justify all anatomic diversities.

In 1988, Leung maintained that transverse division or duplication of the genital ridge and tubules by peritoneal bands could explain all forms of polyorchidism and went on to describe anatomic variations on the basis of embryological development. More specifically, type I supranumerary testis lacks an epididymis, spermatic duct or contact with the healthy testis, type II shares a common epididymis and spermatic duct with the healthy testis, type III has its own epididymis and shares the spermatic duct of the ipsilateral healthy testis whereas type IV represents the complete duplication of testes, epididymis and spermatic duct. The most common presentation is that of type II; types II and III together account for 90% of cases of polyorchidism [5].

The management of polyorchidism remains a subject of controversy, particularly when the supranumerary testis is viable, asymptomatic and only identified incidentally. Formerly, the traditional approach was the surgical excision of the smaller in size testicle [18]. However, Bhogal et al, favour conservative management that entails regular follow-up with magnetic resonance imaging, a non-invasive and sensitive method, providing that the condition is not accompanied by other disorders and does not pose a risk for malignancy [11,14].

Nonetheless, it should be noted that surgical management enables testis fixation and formation of a single testicular mass, thereby protecting if from possible torsion and facilitating biopsy if needed. Furthermore, it enables us to confirm the presence of an outflow tract and the potential for spermatogenesis [10,17]. Malignancy, dysplastic changes or absence of spermatogenic potential, as shown by biopsy, are absolute indications for excision [3].

Some authors advocate excision on the grounds that the majority of cases involve supranumerary testes with reduced or total lack of spermatogenic potential and display an increased incidence of neoplastic disease. Their surgical removal is particularly recommended if the testis is not viable or is associated with cryptorchidism or testicular ectopia, all of which increase the risk for malignancy [19,20].

Others favour the preservation of supranumerary testes as two thirds of cases do not present any histological changes or increased risk for malignancy [1]. Excision of the ectopic supranumerary testis in our patient was decided by virtue of its atrophic nature combined with the malignant risk associated with every undescended or dysplastic testis.

Conclusion

All patients displaying cryptorchidism should be examined for the likely presence of a second ipsilateral testicle. Should the supranumerary testis be healthy, fixation is recommended to prevent torsion and to preserve spermatogenesis. Surgical removal is indicated in cases of atrophy or dysplasia. When in doubt, a biopsy is recommended. Depending on his age, the personal view of the patient, in terms of his psychological and cosmetic needs, should also be taken into consideration before reaching a decision.

References

1. Spranger R. Gunst M, Kuhn M. Polyorchidism; a strange anomaly with unsuspected properties. J Urol 2002; 168:198
2. Wolly B, Youndson GG. Polyorchidism. Pediatr Surg Int 1998; 13:65-66
3. Kharrazi SM, Rahmani MR, Sakipour M, Khoob S. Polyorchidism: a case report and review of the literature. Urology 2006;3:180-183.
4. Yeniyol CO, Nergiz N, Tuna A. Abdominal polyorchidism: a case report and review of the literature. Int Urol Nephrol 2004; 36:407-408
5. Leung AK. Polyorchidism. Am Fam Physician 1988; 38:153-166
6. Paolo Repetto , Pierluca Ceccarelli, Anastasia Bianchini, et al. Three small testes in left hemiscrotum: a rarer case of polyorchidism. Journal of Pediatric Surgery (2010) 45, E21–E23
7. Bostwick DG. Spermatic cord and testicular adnexa. In: Urologic Surgical Pathology. Bostwick DG, Eble JN(eds).Mosby, Pt Louis 1997;140:582-583
8. Leung AK, Wong AL, Kao CP. Duplication of the testis with contralateral anarchism. South Med J 2003;96:809-810
9. Nacey JN, Urquhan Hay D. Polyorhidism. Br J Urol 1987;59:280
10. Ozok G, Taneli C, Yazici M, Herek O, Gokdemir A. Polyorchidism: a case report and review of the literature. Eur J Pediatr Surg 1992;2:306-307
11. Bhogal RH, Palit A, Prasad KK. Conservative management of polyorhidism in a young man: a case report and review of the literature. Pediatr Surg Int 2007;23:689-691
12. Umeda H, Yoshimura Y, Ishibashi K, Yamaguchi O. A case report of polyorchidism with embryonal carcinoma. Nippon Hinyokika Gakkai Zasshi 1998;89:441-444
13. Thum G. Polyorchidism: case report and review of literature. J. Urol. 1991;145: 370–2.
14. Singer BR, Donaldson JG, Jackson DS. Polyorchidism: functional classification and management strategy. Urology 1992;39: 384–8.
15. Nocks BN. Polyorchidism normal spermatogenesis and equal sized testes: a theory of embryological development. J. Urol.1978; 120: 638-40.
16. Wilson WA, Littler J. Polyorchidism: a report of two cases with torsion. Br.J.Surg.1952;41: 302–7.
17. O'Sullivan DC, Biyani CS, Heal MR. Polyorchidism: causation and management. Postgrad. Med. J. 1995; 71: 317–18.
18. Kale N, Basaklar AC. Polyorchidism. J. Pediatr. Surg. 1991;26:1432–4.
19. Scott KWM. A case of polyorchidism with testicular teratoma. J. Urol. 1980;124: 930.
20. Abbasoglu L, Salman FT, Gun F, Asicioglu C. Polyorchidism presenting with undescended testes. Eur J Pediatr Surg 2004;14:355–357

Correspondance to:

Ioannis K Skondras
Ivis 11, Chalandri,
Athens
15234
Tel/Fax: 210-6825625, 6932572226, 2106834338
E-mail: skondras@yahoo.gr

THE IMPORTANCE OF THE EARLY DIAGNOSIS IN THE CONGENITAL HEARING LOSS – CASE PRESENTATION

Maria Domuta[1,2], Ramona Dorobantu[1], Valeria Filip[1], Raluca Iurcov[1], S Cotulbea[2], Delia Horhat[2]

Abstract

The congenital hypo auditory hearing means hearing loss present at birth, due to genetics or non-genetics.

According to the data provided by the National Institute of Deafness and other Communication Disorders (NIDCD), hearing loss is met at 1-3/1000 live healthy infants, but the prevalence grows to 10-50 times to infants with risk. [1,2,3] The purpose of the neonatal auditory screening is to select from the general population, the infants with risk of having hearing loss, given that out of the 10 infants with congenital hypo auditory hearing 9 come from parents who do not have hearing problems. [4]

The article presents three clinical cases of congenital hypo auditory hearing diagnosed in families with or without a history of hearingloss, with or without risk factors for hearing loss associates. Thus, it aims to attract attention to the importance of the neonatal hearing loss in the general population and not only in the presence of the risk factors.

Key words: congenital hearing loss, risk factors, universal neonatal auditory screening

Introduction

Deafness, if it is bilateral especially, trains a sensory deprived the more prejudiced as it occurs in children. If it remains undetected, even an average decrease of unilateral hearing may have negative consequences. [5] Therefore, to minimize the consequences of a deficiency, the hearing loss should be detected early, so that by the age of 3 months to be established the diagnosis and up to 6 months to initiate an appropriate treatment. [6]

The sensory deprivation consequences are even more dramatic as the hearing loss is larger and as occurs earlier.

The early detection and the management of the hearing loss in infants are essential for the normal development of speech, language, literacy and cognitive capacity.

They demonstrated that the early treatment improves the speech, language and intellectual performance of the children, regardless of the initial level of the hearing loss.

Presentation of case

Case I. S.P. new born sweep of 2700 g. female, in the urban environment, from gemelar pregnancy of 38 weeks, with physiological evolution, without suffering at birth; APGAR 8/9.

The result of the auditory screening carried out by OEA to hospital discharge was REFER, and the retest performed at a month from birth had a negative result: REFER.

The auditory testing of the twin sister -6/7-APGAR has not revealed pathological changes: PASS.

The heredo-collateral antecedents have not revealed historically of hearing loss in family, it probably being the reason of the family negation who did not want at the time in question the continuation of the investigations.

The somatic development was normal according to the stages of age, with the first steps made around the age of 11 months and the articulation of the first words at about 18 months.

Around the age of 2 years, the parents have noted that the girl does not react to sounds and have requested a consult ENT, which not revealed pathological changes. On 25.05.2011 (at the age of 3 years and 1 month) for the diagnosis of chronic adenoiditis; bilateral serous otitis they carried out the adenoidectomy and bilateral transtympanal drainage.

The plant evolution in the terms of purchase of the language and the reaction to sounds caused an auditory evaluation by an ABR (Auditory Brainstem Response) and ASSR (Auditory Steady State Responses) on 12.08.2911-at the age of 3 years and 4 months.

After the clinical exam, family investigation, interdisciplinary consulting (Pediatrics) and the performed investigations (less the genetic ones) has established the diagnosis of the bilateral average sensorineural hearing loss right ear and severe left ear.

They recommended bilateral auditory prosthesis, logopedical recovery and ENT periodical revaluation.

Case II. V.I. The newborn premature female from rural areas, from a 28 weeks pregnancy with birth weight of 900 g, APGAR 2/3 with asphyxia during birth and bouts of apnea during neo-natal period. She received hyperbaric for 10 days, remaining hospitalized in the intensive care unit for a month and the total hospital stay duration being of three months.

[1]Faculty of Medicine and Pharmacy Oradea, Romania
[2]University of Medicine and Pharmacy "Victor Babeş" Timişoara, Romania
E-mail: maria.domuta@yahoo.com, dorobanturamona@yahoo.com, valeriafilip@yahoo.com, raluirimie@yahoo.com, cotulbea-cotulbea@umft.ro, deliahorhat@yahoo.com

The auditory testing performed initially by OEA and then by ABR (08.09.2008, three months after the birth) resulted: REFER-REFER.

The heredo-collateral antecedents have not revealed historically of hearing loss in family.

They recommended the continuation of the auditory objective investigations but have not been presented at this stage of diagnosis and could not be seen. The investigation made thereafter established that presents a normal somatic development, but without can quantifying the hearing loss (if it exists).

Case III. G.E. new born mature 2900 g, male, from urban area, derived from the physiological pregnancy of 39 weeks with physiological evolution, birth-cranial spontaneous presentation, without suffering at birth; APGAR 9/10.

The heredo-collateral antecedents revealed historically of hypo auditory hearing in family: mother-congenital hearing loss, father acquired hearing loss, and grandfather paternal- hearing loss probably acquired.

The auditory screening performed on 25.08.2008 by OEA and then to a month by OEA and ABR raised the suspicion of a hearing loss (REFER-REFER).

On 04.10.2011 (at the age of 3 years and 2 months) is performed the auditory evaluation balance by OEA and the tympanometric measures, ABR and ASSR and they establish the diagnosis of the bilateral severe sensorineural hearing loss.

They recommend bilateral auditory prosthesis, auditory recovery and ENT revaluation (to the cochlear implant).

Discussions

1. The importance of the early identifying of the hearing loss is long time accepted, but only in the recent years it has put in place a national identification program of the hearing loss even from birth (program where also Oradea enters).

They use two types of tests:

The first test was developed in England and carries the name of acoustic oto-emissions (OEA) that evaluates the function of the inner ear; it takes a few minutes and is performed during the natural sleep. If the test result is "REFER" does not mean that the babe shows hearing loss (may be restless or can present still liquid in the external auditory conduct during the childbirth, the result being not conclusive if there is a pathology of the external ear). If OEA are missing, the new infant has a neuro-sensory hearing loss at least 30 dB.

If also the second test by OEA does not get a positive response, the second type of test is to be done: AABR- (automated auditory brainstem response). This test reflects the function of the conductive ways up to the level of the brain stem and is carried out during the natural sleep - the average long 5-30 min.

The most effective screening is based on the pairing of the two objective tests, this being mandatory in the infants who require inpatient in ATI (neonatal intensive care unit) for more than 5 days. 6,7

2. Initially, since 1975, the J.C.I.H. (The Joint Committee of Infant Hearing) recommended that the neonatal screening for hearing loss to be carried out by ABR to all children with the risk factors present. But only 50% of children which present hearing loss present one or more risk factors (as seen in the above cases), so, even if the screening program would work perfectly, about 50% of children with hearing loss would not be detected. In addition, through the program of screening of all the risk factors would be very difficult that the parents to be recalled for diagnostic evaluation. Incidentally, the first reaction and (most anticipated) of the parents is denial.

According to the J.C.I.H. Year 2007 for the children detected with permanent hearing loss must be performed at least once an assessment by ABR until the age of 3 years within the complete auditory evaluation. 6

For the children who pass the neonatal screening but present risk factors must be performed at least once an auditory evaluation between the months 24-30, repeated for the children with the cytomegalovirus infection, syndromes associated with hearing loss progressive, neuro-vegetative disorders, trauma or any other positive cultures for postnatal infections, for the children with history of hearing loss or who had chemotherapy or ECMO (extracorporeal membrane oxygenation). 6

3. The early identification and intervention can prevent the severe psychosocial, educational and linguistic repercussions. Ideally, new birth babe screening must be completed at the age of one month (NCHAM) and diagnosed before the age of three months to be enlisted in the program of early intervention until the age of 6 months. 6,8

4. There are researches that have compared the children with hearing loss who were early detected and when that occurred before the age of 6 months with the children intervened over the age of 6 months. In time, they noticed that the children that were early detected are 1-2 years ahead of those identified later in language, mental development and social attitude. 9

Thus, in the long term, we can make serious savings for the education of the hypo auditory hearing children hearing early tracked down.

References

1. National Institute on Deafness and other Communication Disorders (NIDCD). Statistics and epidemiology. [online] [Accessed 2004-2009] http://www.nidcd.nih.gov/health/statistics/hearing.asp
2. White, K. R. (October, 1997). The scientific basis for newborn hearing screening: Issues and evidence. Invited keynote address to the Early Hearing Detection and Intervention (EHDI) Workshop sponsored by the Centers for Disease Control and Prevention, Atlanta, Georgia.
3. The National Center for Hearing Assessment and Management (NCHAM) – Universal Newborn Hearing screening [online]

4. York J, Devoe M. Health Issues in survivors of prematurity: hearing loss. [online] [accesat 2009] http://www.medscape.com/viewarticle/442880_6
5. Bess, F. H., & Tharpe, A. M. (1986). Case history data on unilaterally hearing-impaired children. Ear and Hearing, 7(1), 14-19.
6. Joint Comitee of Infant Hearing. Year 2007 Position Statement: Principles and Guidelines for Early Hearing Detection and Interventions Programs. Pediatrics 2007;120 (4):898-921.
7. http://www.deafnessresearch.org.uk/factsheets/hearing-tests-for-babies.pdf
8. Joint Committee on Infant Hearing. American Academy of Pediatrics. American Speech–Language –Hearing Association. Directors of Speech and Hearing Programs in State Health and Welfare Agencies. Year 2000 position statement: principles and guidelines for early hearing detection and intervention programs. Pediatrics.2000; 106:798-817.
9. Yoshinaga-Itano, C., Sedey, A., Apuzzo, M., Carey, A., Day, D., & Coulter, D. (July 1996). The effect of early identification on the development of deaf and hard-of-hearing infants and toddlers. Paper presented at the Joint Committee on Infant Hearing Meeting, Austin, TX. Moeller, M. P. (October 1996). Early intervention of hearing loss in children. Paper presented at Fourth International Symposium on Childhood Deafness, Kiawah Island, South Carolina.
10. Medscape Reference – Newborn Hearing screening http://emedicine.medscape.com/article/836646-overview [online]

Correspondance to:

Maria Domuta – MD PhD Student of
UMF "Victor Babes", Timisoara
Dimitrie Cantemir Street, No.2, Sc. A1, ap.9
Oradea, Romania
410519
Email: maria.domuta@yahoo.com

PEDIATRIC ACL RECONSTRUCTIONS USING TRANSPHYSEAL HAMSTRINGS

H Haragus[1], R Prejbeanu[1], D Vermesan[1], G Damian[2], S Vermesan[3]

Abstract

Anterior cruciate ligament (ACL) injuries are increasing in skeletally immature patients. In the adult population management is fairly standardized with surgical reconstruction using hamstrings autograft being the most common current treatment. However, for the pediatric population with open physes concern exists regarding surgical management since the distal femur and proximal tibia accounts for an important lengthening and alignment of the lower limb.

For this purpose we performed a retrospective evaluation of our cohort of pediatric ACL reconstructions. 4 girls and 3 boys met the inclusion criteria out of 628 consecutive cases operated by a single surgeon over the last 5 years.

The girls were 13, 14 and two 15 respectively and the boys were 15 and two 16. All were competing athletes coming from: one girl volley and three hand-ball and the boys soccer. All had subjective instability and received single bundle transphyseal primary ACL reconstruction performed by the same surgeon using quadruple hamstrings (semitendinosus and gracillis) with cortical femoral and absorbable interference screw tibial fixation. All patients had associated lesions: 5 chondral, 3 internal 2 external and one both menisci; Time from injury to surgery was on average 9.1 weeks (5 to 17).

6 out of seven were available for a final follow-up of 1.9 years. All had returned to sports at preinjury activity levels and had IKDC (international knee documentation committee) scores for excellent (A) and good (B) outcomes. No clinical and radiographic growth arrests could be identified.

We conclude that single bundle transphyseal ACL reconstructions using hamstrings autografts for skeletally immature patients yields favorable outcomes. However, only small portions of estimate incidence undergo specialist evaluation and surgical treatment. Further collaborations should be encouraged to allow more pediatric patients to benefit from surgical ACL reconstruction. In addition, for such cases, exact height and Tanner skeletal maturity should be noted at the time of index surgery in order to improve retrospective evaluations.

Key words: pediatric, ACL reconstruction, transphyseal, hamstrings

Clinical background

Anterior cruciate ligament (ACL) injuries are increasing in skeletally immature patients. In the adult population management is fairly standardized with surgical reconstruction using hamstrings autograft being the most common current treatment. However, for the pediatric population with open physes concern exists regarding surgical management since the distal femur and proximal tibia accounts for an important lengthening and alignment of the lower limb.

Historically there have been large practice variations in initial management and reconstruction techniques. Surgeons feared growth disturbance complications such as: distal femoral valgus deformity with arrest of the lateral distal femoral physis, tibial recurvatum with arrest of the tibial tubercle apophysis, genu valgum without arrest and leg length discrepancy. Based on this experience, a guarded approach to ACL reconstruction in the skeletally immature patient was advocated [1].

Nevertheless, over the years attitudes have changed towards favoring early surgical treatment as opposed to conservative management. Clear evidence shows that the same correlations from the adult populations exist in the skeletally immature patients regarding increase meniscal and chondral injuries with delayed treatment. This is concerning because studies have shown that, regardless of knee stability obtained after ACL reconstruction, meniscectomy accelerates degenerative joint changes. Lawrence et al [2] found that out of 70 young patients who underwent surgical reconstruction of an acute ACL tear more than 12 weeks after the injury (odds ratio 4.1) more were noted to have a significant increase in irreparable medial meniscal tears and lateral compartment chondral injuries (odds ratio 11.3) at the time of reconstruction. When a subjective sense of knee instability was present, this association was even stronger (odds ratio 11.4). Dumont et al [3] performed a retrospective chart review of 370 pediatric patients undergoing primary arthroscopic ACL reconstruction. They identified that index ACL reconstructions after more than 150 days since injury have a higher rate (odds ratio 1.8) of medial meniscus tears than those treated earlier. Increased age (odds ratio 1.6) and weight (odds ratio 2.2) are independently associated with a higher rate of medial meniscus tears.

[1]I-st Clinic of Orthopedics and Trauma, 'Victor Babes' University of Medicine and Pharmacy Timisoara
[2]University of Medicine and Pharmacy 'Vasile Goldis' Arad
[3]Clinical Emergency Plastic Sugery and Burns Hospital Bucharest
E-mail: horia.haragus@yahoo.com, raduprejbeanu@gmail.com, vermesan@gmail.com
drdamiangratian@yahoo.com, simover1@yahoo.com

Patients with ACL tears and a medial or lateral meniscus tear are more likely to have a chondral injury in that particular compartment than those without meniscal ruptures.

Regarding the most appropriate graft choice there is growing support in favor of autologus hamstrings (semitendinosus and gracilis) and concern with bone – patellar tendon – bone since the bone plugs have led to premature physeal ossifications in animal models. Gebhard et al [4] analyzed twenty-eight patients who underwent ACL reconstruction with hamstrings, 16 patients with bone-patella-bone, 12 patients with quadriceps grafts and 12 patients with facia lata. The mean follow-up was 32 months. Neither leg length discrepancy nor angular deformities were noted. None of the four methods studied showed major differences in outcome compared to the other.

Thus, surgical stabilization should be considered as the first line of treatment for immature patients with ACL tears. The existing literature suggests that transphyseal reconstruction can be safely done in this population if a few rules are considered, and there are physeal-sparing procedures that provide excellent results with less theoretical risk to the growth plate. Conservative or delayed surgical treatment, which carries an increased risk of secondary joint injury, should be reserved only for selected cases [5].

This change of perspective has not been fully agreed upon especially regarding surgical procedure with respect to physeal growth plates. Moksnes et al [6] performed a recent literaure review and found that there is no consensus on the management of anterior cruciate ligament injuries in skeletally immature children, and the methodological quality of published studies is questionable. The transphyseal reconstructions, physeal-sparing reconstructions, and nonoperative treatment algorithms that are advocated have little supportive data.

In our center we have been performing over 150 ACL reconstructions every year. A recent analysis has revealed an increase in the percentage of skeletally immature which has led us to perform a review of the literature and our cases in order to evaluate our current standard of treatment.

Material and Method

For this purpose we performed a retrospective evaluation of our cohort of pediatric ACL reconstructions. Criteria for inclusion were up to 15 years of age for girls and 17 for boys at index surgery and open physis evaluated using postoperative x-rays. These were the only reliable measurements available, even though in the literature the standard bone age evaluation for pediatric ACL reconstructions is the one proposed by Tanner and Whitehouse; this system scores 20 indicators on hand and wrist radiograph, yielding total scores ranging from 0 to 100. However, we were not able to use this scale in retrospect. 4 girls and 3 boys met the inclusion criteria out of 628 consecutive cases operated by a single surgeon over the last 5 years. The girls were 13, 14 and two 15 respectively and the boys were 15 and two 16. The probable estimate Tanner stage was III and IV. Example of MRI appearance can be seen in fig.1 - 3.

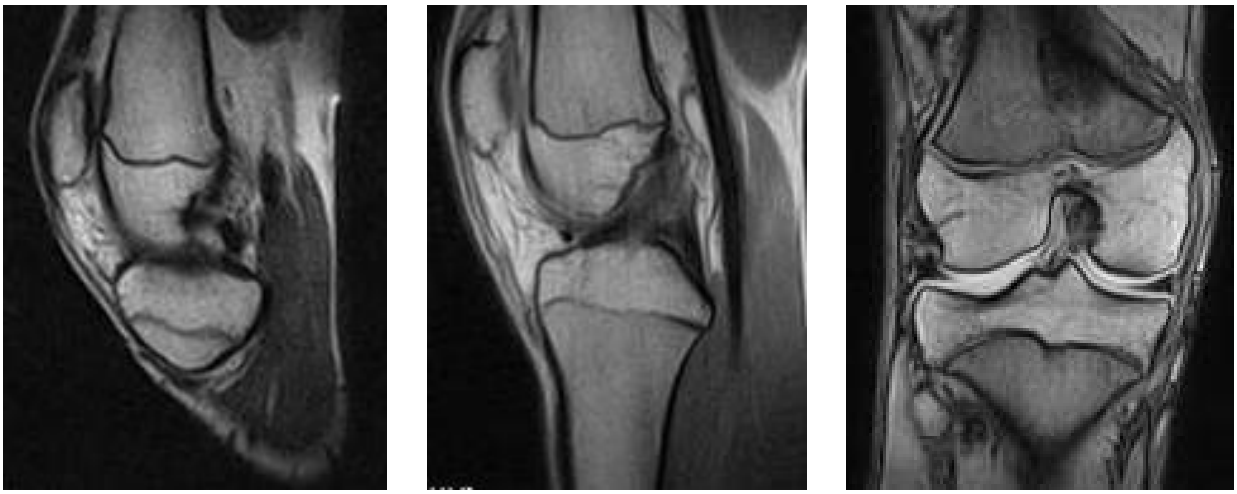

Fig.1 RISE and fig. 2 T1 sagittal and fig. 3 T1 coronal views of 16 years old boy with open physis and ruptured ACL.

Results

All had subjective instability and received single bundle transphyseal primary ACL reconstruction performed by the same surgeon using quadruple hamstrings (semitendinosus and gracillis) with cortical femoral and absorbable interference screw tibial fixation (fig.4 – 9). All patients had associated lesions: 5 chondral, 3 internal 2 external and one both menisci; all meniscal lesions were addressed by partial resection. Time from injury to surgery was on average 9.1 weeks (5 to 17).

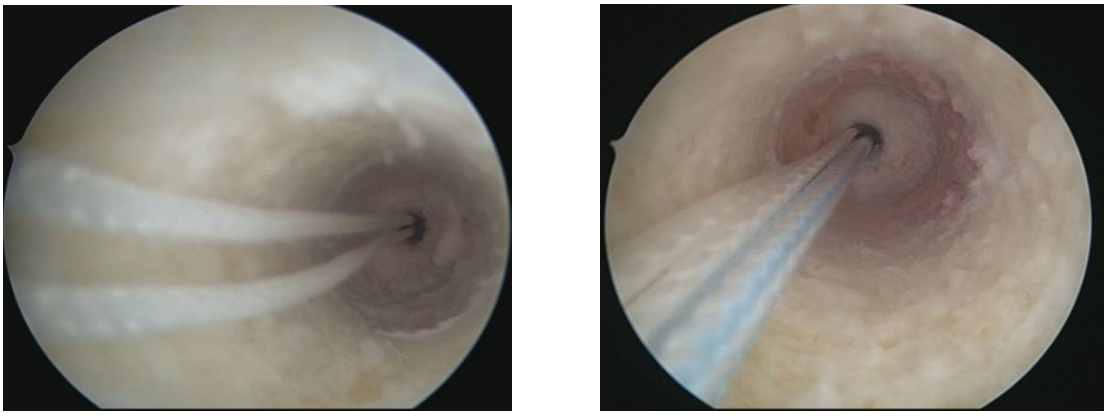

Fig.4 and 5: femoral tunnel of two cases showing the arthroscopic view of the transphyseal ACL reconstruction.

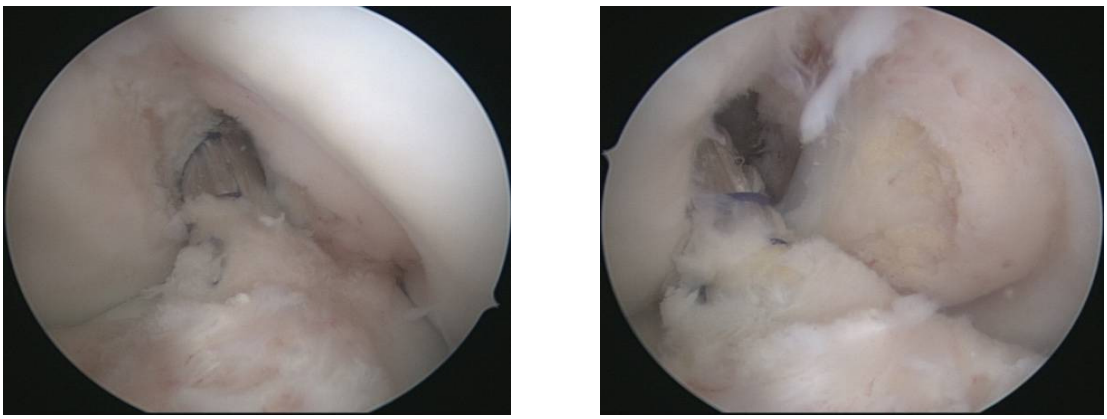

Fig.6 medial and fig.7 lateral portal views of the case above of 16 years old boy with anatomic single bundle (transphyseal) ACL reconstruction using ipsilateral hamstrings (semitendinosus and gracilis) autograft (quadruple).

Fig.8 and 9 show AP and lateral radiographs of a 16 years old boy with open physis and ACL reconstruction using transphyseal technique with hamstrings autograft, cortical femoral fixation and absorbable tibial interference screw.

All were competing athletes coming from: one girl volley and three handball and the boys soccer. Postoperative regimen also resembled that of adult population and began with partial weightbearing for the first 3 weeks with passive and active ROM exercises followed by progression to complete return to sports at an average of 5.5 months (4 to 7).

6 out of seven were available for a final follow-up of 1.9 years. All had returned to sports at preinjury activity levels.

AP knee radiographs showed no degenerative progression comparative to immediately postoperatively and no visible signs of tunnel enlargement. No clinical and radiographic growth arrests could be identified. However, no exact estimate of height increase could be made due to inaccurate height recordings at index surgery. One case had had persistent pain and stiffness until approximately one year postoperatively which resolved spontaneously with inconclusive MRI findings.

Discussions

Similar studies have found favorable results for autologus hamstrings grafts using transphyseal techniques (7,x,9). Redler et al [10] showed that transphyseal ACL reconstruction with autogenous quadrupled hamstring graft with metaphyseal fixation in skeletally immature (14.2 years) patients yielded excellent functional outcomes in a high percentage of patients without perceived clinical growth disturbance at a mean of 43.4 months.

Drill hole placement during ACL reconstruction produces a zone of physeal injury. The overall volume of injury is relatively low, which reduces the risk of physeal arrest. With careful placement, the region of injury is central on the tibia, and the total volume of injury can be less than 5.0% of the physeal volume. For the femur, the total volume can be less than 5.0% as well. However, the region of injury is peripheral, which carries a higher risk of physeal arrest. For the tibia, drill holes that started more medial, distal, and with a steeper angle of inclination reduced the amount of physis and apophysis violated when compared with holes placed more lateral, proximal, and with a shallow angle of inclination [11,12].

Other authors [13] have used MRIs to identify physeal sparring directions of the femoral tunnel using transphyseal techniques and proposed drilling from the center of the ACL femoral footprint to the insertion of the popliteus tendon; this could result in a mean tunnel length of 27 to 30 mm, and it might allow the safe placement of a femoral tunnel at least 7 mm in diameter in patients six to seventeen years old. The center of the ACL femoral footprint and the popliteus insertion are easily identifiable landmarks and will allow safe, reproducible, anatomic ACL reconstruction in the skeletally immature patient.

A retrospective case series of 933 knees with a mean age at the time of surgery of 15 years and an average follow-up from index surgery of 6.3 years evaluated the overall prevalence of arthrofibrosis and found it to be 8.3%; 77 knees had at least one procedure to treat arthrofibrosis after ACL reconstruction. Arthrofibrosis was defined as a loss of 5 degrees or more of extension or a loss of 15 degrees or more flexion compared with the contralateral knee that required a follow-up procedure. Risk factors for arthrofibrosis were female sex, higher age (16 to 18 years odds ratio 3.51), patellar tendon autograft (odds ratio 1.7), and concomitant meniscal repair (odds ratio 2.08). Prior knee surgery and ACL reconstruction within one month of injury were not significantly associated with arthrofibrosis after ACL reconstruction [14].

Frosh et al [15] identified a total of 55 articles reporting on 935 patients (median age 13 years) with a median follow-up of 40 months; their review found the weighted rate of leg-length differences or axis deviations was 1.8% and that of reruptures was 4.8%. Excellent or good function (International Knee Documentation Committee grade A or B) was achieved in 84.2% of knees and Lysholm scores averaged 96.3. Transphyseal reconstruction was associated with a significantly lower risk of leg-length differences or axis deviations compared with physeal-sparing techniques (1.9% versus 5.8%; relative ratio 0.34) but had a higher risk of rerupture (4.2% versus 1.4%; relative ratio 2.91). Sutures did not result in any growth disturbances, with a weighted rerupture rate of 4.6%. Fixation far from the joint line fared better than close fixation with regard to this endpoint (1.4% versus 3.2%; relative ratio 0.42). Bone-patellar tendon-bone grafts, which are also less likely to fail, were associated with higher risks of leg-length differences or axis deviations than were hamstrings (3.6% versus 2.0%; relative ratio 1.82). Meta-regression did not show a significant impact of the publication year on event rates.

Kaeding et al [16] aimed to determine whether any anterior cruciate ligament reconstruction technique is clinically superior in skeletally immature patients having at least one of the following criteria: chronologic or bone age of less than 15 years in boys or less than 14 years in girls, Tanner stage I, II, or III and at least 10 cm of total growth after the reconstruction. Thirteen case series were included. Four studies used physeal-sparing techniques. Six studies used transphyseal techniques. Two studies used a combined technique, and a multicenter study reported results of both techniques. Within the physeal-sparing group, there were 2 studies that used an entirely extra-epiphyseal technique and 2 studies that used intra-epiphyseal techniques. Overall clinical outcomes were excellent, with growth complications being very rare in all of these series. The authors concluded that both physeal-sparing and transphyseal reconstructions can produce excellent clinical outcomes with a very low incidence of growth complications in Tanner stage II and III patients. Tanner stage I patients had excellent clinical results with physeal-sparing techniques (both extra- and intra-epiphyseal techniques). Not enough Tanner stage I patients underwent transphyseal techniques to support or discourage their use. This evidence supports considering the expansion of transphyseal reconstruction indications from Tanner stage IV patients to Tanner stage II and III patients.

Conclusions

In our clinical setting we conclude that single bundle transphyseal ACL reconstructions using hamstrings autografts for skeletally immature patients yield favorable outcomes. However, only a small portion of estimate incidence undergoes specialist evaluation and surgical treatment. Further colaborations should be encouraged to allow more pediatric patients to benefit from surgical ACL reconstruction. In addition, for such cases, exact height and Tanner skeletal maturity should be noted at the time of index surgery in order to improve retrospective evaluations.

References

1. Kocher MS, Saxon HS, et al. Management and complications of anterior cruciate ligament injuries in skeletally immature patients: survey of the Herodicus Society and The ACL Study Group. J Pediatr Orthop. 2002 Jul-Aug;22(4):452-7.
2. Lawrence JT, Argawal N, et al. Degeneration of the knee joint in skeletally immature patients with a diagnosis of an anterior cruciate ligament tear: is there harm in delay of treatment? Am J Sports Med. 2011 Dec;39(12):2582-7. Epub 2011 Sep 14.
3. Dumont GD, Hogue GD, et al. Meniscal and chondral injuries associated with pediatric anterior cruciate ligament tears: relationship of treatment time and patient-specific factors. Am J Sports Med. 2012 Sep;40(9):2128-33. Epub 2012 Jun 22.
4. Gebhard F, Ellermann A, et al. Multicenter-study of operative treatment of intraligamentous tears of the anterior cruciate ligament in children and adolescents: comparison of four different techniques. Knee Surg Sports Traumatol Arthrosc. 2006 Sep;14(9):797-803. Epub 2006 Apr 21.
5. Vavken P, Murray MM Treating Anterior Cruciate Ligament Tears in Skeletally Immature Patients Arthroscopy. 2011 May 1; 27(5): 704–716.
6. Moksnes H, Engebretsen L, et al. The current evidence for treatment of ACL injuries in children is low: a systematic review. J Bone Joint Surg Am. 2012 Jun 20;94(12):1112-9.
7. Courvoisier A, Grimaldi M, et al. Good surgical outcome of transphyseal ACL reconstruction in skeletally immaturepatients using four-strand hamstring graft. Knee Surg Sports Traumatol Arthrosc. 2011 Apr;19(4):588-91. Epub 2010 Oct 2.
8. McIntosh AL, Dahm DL, et al. Anterior cruciate ligament reconstruction in the skeletally immature patient. Arthroscopy. 2006 Dec;22(12):1325-30.
9. Streich NA, Barié A, et al. Transphyseal reconstruction of the anterior cruciate ligament in prepubescent athletes. Knee Surg Sports Traumatol Arthrosc. 2010 Nov;18(11):1481-6. Epub 2010 Feb 4.
10. Redler LH, Brafman RT, et al. Anterior Cruciate Ligament Reconstruction in Skeletally Immature Patients With Transphyseal Tunnels. Arthroscopy. 2012 Aug 27. [Epub ahead of print]
11. Shea KG, Apel PJ, et al. The anatomy of the proximal tibia in pediatric and adolescent patients: implications forACL reconstruction and prevention of physeal arrest. Knee Surg Sports Traumatol Arthrosc. 2007 Apr;15(4):320-7. Epub 2006 Aug 15.
12. Shea KG, Belzer J, et al. Volumetric injury of the physis during single-bundle anterior cruciate ligament reconstruction in children: a 3-dimensional study using magnetic resonance imaging. Arthroscopy. 2009 Dec;25(12):1415-22. Epub 2009 Nov 7.
13. Xerogeanes JW, Hammond KE et al Anatomic landmarks utilized for physeal-sparing, anatomic anterior cruciate ligament reconstruction: an MRI-based study. J Bone Joint Surg Am. 2012 Feb 1;94(3):268-76.
14. Nwachukwu BU, McFeely ED et al Arthrofibrosis after anterior cruciate ligament reconstruction in children and adolescents. J Pediatr Orthop. 2011 Dec;31(8):811-7.
15. Frosch KH, Stengel D, et al. Outcomes and risks of operative treatment of rupture of the anterior cruciate ligament in children and adolescents. Arthroscopy. 2010 Nov;26(11):1539-50.
16. Kaeding CC, Flanigan D, et al. Surgical techniques and outcomes after anterior cruciate ligament reconstruction in preadolescent patients. Arthroscopy. 2010 Nov;26(11):1530-8.

Correspondance to:

Horia Haragus,
I Bulbuca 10,
300376,
Timisoara,
România,
Telephone: 0747025064
E-mail: horia.haragus@yahoo.com

LIVER CHIRRHOSIS – ULTRASOUND ASPECTS OF PORTAL CIRCULATION

Roxana Folescu[1], Alina Şişu[1], Elena Pop[1], Izabella Şargan[1], B Hogea[1], Delia Zăhoi[1], Ecaterina Dăescu[1], A Motoc[1]

Abstract

Doppler ultrasound is a non-invasive method for assessing vascular port system. The aim is to study the changes in structure of the liver with the portal flow in patients with cirrhosis. Evolution of liver cirrhosis with portal hypertension makes the essential changes of portal vein. One of the objectives of the study was the investigation of the Doppler axis spleno-portal hemodynamics, evaluated and analyzed in relation to liver functional reserve, which we estimated classified as Child - Pugh. Our study followed 187 patients with cirrhosis and portal hypertension. The study is retrospective, based on analysis of inpatient observation sheets in County Emergency Hospital, Timisoara, during the last five years. Sectional area of the hepatic portal vein is another criterion for evaluation of patients with cirrhosis area we reported a study in functional classes: Child class "A" → VP sectional area = 175 mm^2 class Child "B" → sectional area VP = 236 mm^2; Child class "C" → VP sectional area = 183 mm^2.

Key words: vascular port system**,** Doppler ultrasound, portal hypertension.

Introduction

Liver cirrhosis represents the tenth death cause worldwide, according to the latest statistical data. The frequent complications which may appear in this disease are: ascites (50% of the patients develop ascites in a period of 10 years since the diagnosis), hepatic encephalopathy and variceal bleeding (25 % of the patients), while portal hypertension is the result of the increased intrahepatic resistance and portal blood flow. (1)

The incidence of the liver cirrhosis is not well known in Romania. The majority of the patients who come to the doctor due to the ascitic syndrome, have liver cirrhosis (75%), the other etiologies being rarely come across: malign tumors (10 % of the cases), heart failure (3%), peritoneal tuberculosis (2%), chronic pancreatitis (1%) etc.

Doppler Ultrasound represents an invasive method of evaluation for the vascular port system. The purpose of the study is that of changes in liver's structure determination along with those of portal blood flow, in the case of patients with liver cirrhosis. Several diagnostic elements are considered in favor of liver cirrhosis:

- Hepatic structure: it is modified at 1/ 2 of the cases; it is heterogeneous and scratchy.
- Liver surface: it is wavy, micro or macro wane (nodules bigger than 5 mm);
- Caudate lobe hypertrophy: in about 70-80 % of the cirrhosis, the anterior-posterior diameter is > 35-40 mm;
- The presence of the portal hypertension signs: hepatic portal vein dilation over 14 mm(the normal value is up to 13 mm), lack of variability in hepatic portal vein in forced inhale or exhale , enlargement of the splenic vein > 10 mm (preaortic), umbilical vein , re-permeability of the umbilical vein ,the presence of ascites (2).
- Ascites and splenomegaly are not always specific to liver cirrhosis;

The latest data invoke a relatively high frequency of the portal thrombosis to cirrhotic patient. The role of this phenomenon in the development of portal hypertension's complications is not well defined nowadays, fact which requires further research in this domain (3, 4).

Material and method

Ultrasonography is an invasive, anatomic and functional examination method, which allows the simultaneous viewing of both the parenchyma and the hepatic vessels.

[1]Department of Anatomy and Embryology, University of Medicine and Pharmacy "Victor Babes" Timisoara,
E-mail: roxanafolescu@yahoo.com, alinasisu@gmail.com, alexandra_2987@yahoo.com, dr.sarganizabella@yahoo.com, hogeabg@yahoo.com, dzahoi@umft.ro, tinadaescu@yahoo.com, amotoc@umft.ro

Ultrasound examination of the vascular system port has the following indications: the diagnosis of portal hypertension, etiologic diagnosis, and evaluation of portal and systematic shunt surgery, evaluation of hepatic transplant even in pharmacological and dynamic studies of portal hypertension (5).

The evolution of hepatic cirrhosis with portal hypertension leads to essential changes of hemocirculation in the hepatic portal vein basin. One of the study's objectives is that of hemodynamics' Doppler research on the spleno-portal axis evaluated and analyzed in relation to functional liver reserves, which we estimated according to Child- Pugh classification, with the severity score assessment of liver function disorders. (CHART 1).

Our group had 187 patients with liver cirrhosis and portal hypertension; they were endoscopically treated for hemorrhages of esophageal varices and for ascitic syndrome associated with splenomegaly and hypersplenism. The study is a retrospective one, being based on the analysis of the observation sheet of the patients which have been hospitalized in County Emergency Clinical Hospital of Timisoara during the last 5 years.

CHART 1: Child - Pugh criteria of liver functional reserve assessment.

INDEX	VALUE		
	1 point	**2 points**	**3 points**
Albumin (g/l)	>35	30 - 35	<30
Bilirubin (mmol/l)	<35	35 - 50	>50
Prothrombin (%)	>70	40 - 70	<40
Ascites	absent	insignificant	moderate/severe
Encephalopathy	absent	insignificant	moderate/severe

According to this classification, the patients of Child "A" category gather 5 or 6 points , Child "B" → 7 - 9 points, Child "C" → 10-15 points; this classification was obtained depending on the score of the estimated factors, which are to be seen the above chart.

Results and discussions

We have studied 187 patients wit liver cirrhosis (111 males and 76 females) (Diagram 1).

With the age between 18 and 82 years old; 115 patients were from urban and 72 were from rural; the diagnosis to these patients was established on the basis of clinical, biochemical, endoscopic, imaging and morphological criteria.

The etiology of liver cirrhosis was made by the identification of serological markers of viral hepatitis to all patients. Cirrhosis of viral etiology was come across in 102 cases-representing 54,5% of the total.

The etiological specification certified the essential role of chronic viral infection which certainly leads to chronic, persistent and often worsening clinically asymptomatic hepatitis in its future development. Serological investigations did not notice a statistically significant difference regarding the etiology of liver cirrhosis and patients' distribution by gender. Thus, in our group, the viral factor was identified to 64 (57.7%) out of 111 investigated males and respectively, to 45 (59,2%) of 76 females.

There were studied the particularities of portal blood circulation depending on the hepatic functional reserve.

The appreciation of hepatic functional reserves according to Child- Pugh classification of the patients with acute hemorrhages (due to esophageal varices) found compensated hepatic functions → Child "A" in 29 cases (15,5%), sub compensated → Child „B" – 102 cases (54,4%) and decompensated → Child „C" in 56 cases (30,1%) (Diagram 2). Thus, in the group of the patients with hepatic cirrhosis, complicated with active hemorrhages, due to esophageal varices, remarked a certain prevalence of patients with sub compensated and decompensated functional hepatic status (84,5%).

We found out that to Child "A" and "B" patients, it is established a spleno-portal flow with large hyperkinetic volume and while the cirrhosis progresses to the decompensation stage, these indexes essentially decrease.

The asymmetry phenomenon of intrahepatic portal blood circulation was demonstrated and manifested by right liver lobe hemodynamic deprivation and prevalence of left portal branch circulation at the same time with the increase of splenic venous inflow (6).

The area of hepatic portal vein constituted another criterion of the patients' evaluation, area which we reported to the studied functional classes: Child „A" class→ sectional area VP = 175 mm^2 Child „B" class → sectional area VP = 236 mm^2; Child „C" class → sectional area VP = 183 mm^2 (Diagram 3).

Once with the decrease of hepatic functional reserves, one could notice a tendency to hypertrophy of the left liver lobe. Thus, to the patients in Child A, B, C categories, the ultrasound dimensions of LHS were the following: 74 mm / 81 mm / 87 mm (Diagram 4).

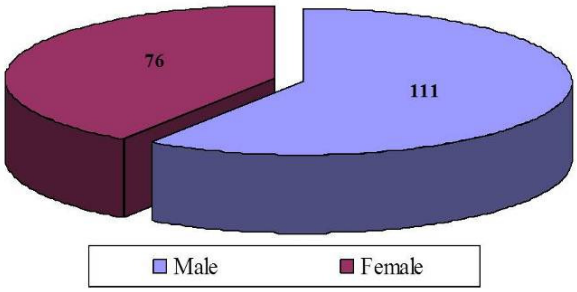

Diagram 1: Distribution by gender.

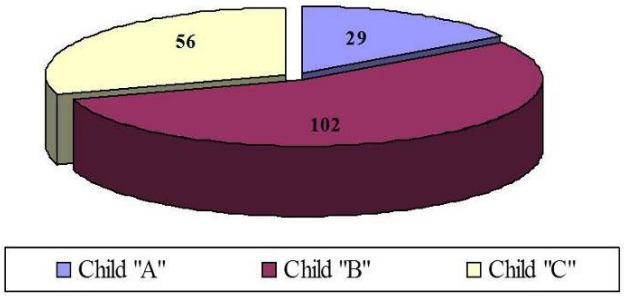

Diagram 2: Distribution of our group according to Child- Pugh classification.

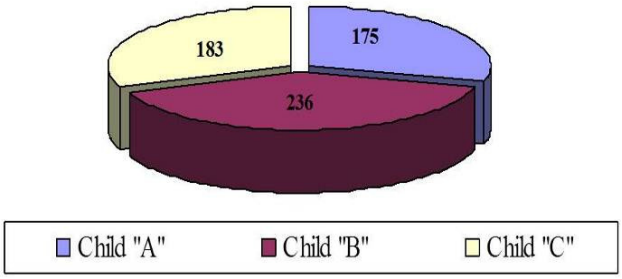

Diagram 3: Sectional area of the hepatic portal vein to the studied functional classes.

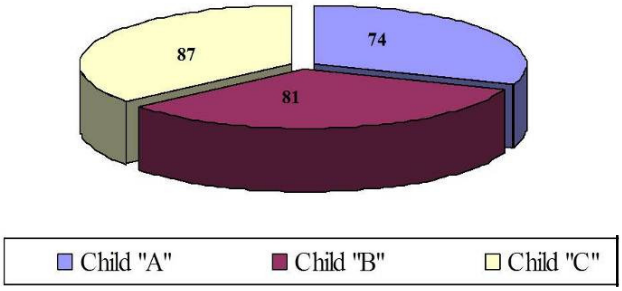

Diagram 4: Ultrasound dimensions of the liver left lobe, in Child-Pugh categories.

The ultrasound should always be interpreted in the clinical context of the patients. The information anterior to examination is extremely important in performing the ultrasound and drawing the attention of the doctor who performs the ultrasound to a certain organ or region.

The liver can be sonographically normal or increased with the hepatic portal vein and main branches thickening which become highly echogenic, especially around the hepatic portal vein. Splenic veins can be dilated and, if there is portal hypertension, there is also splenomegaly. An increase in collateral circulation can occur around the splenic hilum and along the medial edge of the liver (Figure 1, Figure 2). This can be seen under the form of rigid vascular structures, without echo, which must be distinguished from fluid-filled intestines.

Figure 1: The ultrasound aspect in hepatic cirrhosis (I.S., 47 years old, diagnosed with alcoholic liver cirrhosis).

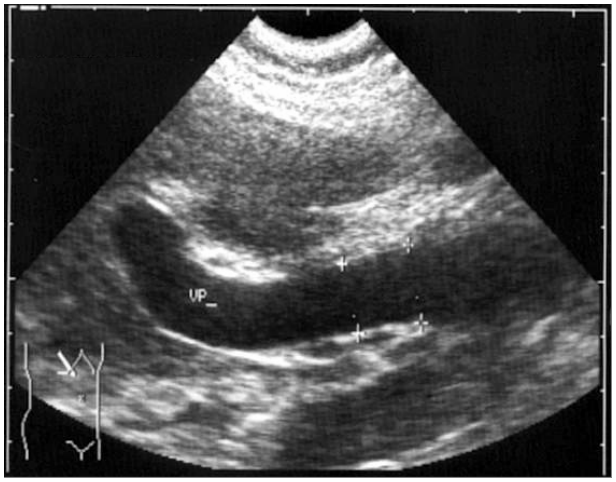

Figure 2: Signs of portal hypertension: VP dilation (21 mm) (C. A., 32 years old, diagnosed with virus liver cirrhosis).

All the patients were endoscopically evaluated for the staging of esophageal varices: 12 patients did not have esophageal varices (6,4 %), 31 patients had esophageal varices of first rank (16,6 %), 101 patients had esophageal varices of second rank (54%) and 43 patients had esophageal varices of third rank (23%) (Diagram 5).

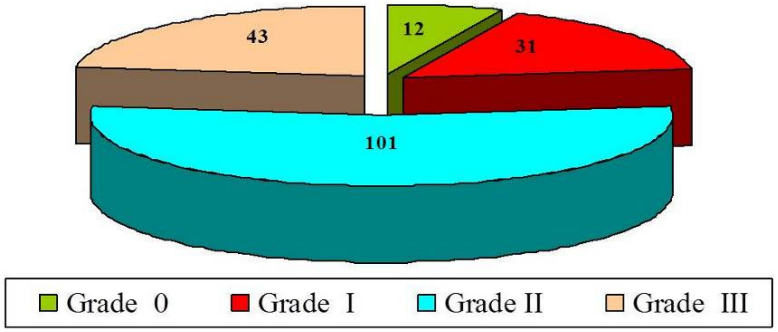

Diagram 5: Distribution of the group according to the rank of esophageal varices.

Conclusions

1. Extremely useful, noninvasive, without the risk of nephrotoxicity given by the contrast substance (as it happens in the case of computer tomography), cost-good efficiency, unlaborious and available- it is the abdominal ultrasound, the first investigation to be performed in the case of cirrhosis suspicion.
2. The portal hypertension is determined by multiple and diverse etiopathogenic factors, primarily based on angioarchitechtonic and morphological denaturation of liver.(7)
3. The gradual changes of liver parenchyma lead to an increased vascular resistance to the portal flow, at the same time with a splanchnic hyperemia with excessive blood inflow. These mechanisms, initially adaptive and compensatory are then reflected by expressive disturbance of portal hepatic hemo -circulation and adversely affect the liver status.
4. In portal hypertension a part of the portal blood volume is derived through portal-systemic shunts, intra and extra hepatic, thus, the functional hepatic flow stream being reduced; it is a hemodynamic phenomenon which introduces the decompensation of liver functions.
5. Once with the diminution of functional liver reserves and increase of intrahepatic vascular resistance, there occurs a decreased portal blood flow and liver functional current. (8). That finds its explanation through the emergence, development and functioning of multiple intrahepatic portal –systemic anastomosis with a substantial deviation and redirection of the portal blood flow to the systemic one within portal hypertension.
6. According to Gorka and Plestina (9, 10), the splenic flow venous report in relation to the portal one represents a predictive factor in the development of esophageal and gastric varices and in digestive haemorrhages bleeding by triggering their eruption and intensifying portal gastropathy, altogether with worsening of secondary portal hypertension splenopathy; this fact was also found in our studied group.
7. By estimating the role of splenic venous hemocirculation in portal hypertension's progressing, Kutlu and his co-workers (11) record a right liver lobe hemodynamic deprivation altogether with a decrease in velocity and in portal blood flow on this intrahepatic branch , while mentioning a marked venous congestion. Even in the case of our group, I noticed a tendency of hypertrophy of the left liver lobe.
8. The hemorrhages in the case of patients with liver cirrhosis and portal hypertension have certain specific features to this pathology, because they trigger in extreme conditions of portal- hepatic circulation, distorted by congestion and regional vein stasis, trophic disorders of the gastro-esophageal mucosa, associated with dysfunctions of the coagulation system.
9. Esophageal varices occur in the case of an excessive portal pressure and result in shunting the venous flow in submucosal esophageal veins, while gastric varices are caused by portal blood flow derivation throughout the short gastric veins (12, 13).
10. Digestive bleeding by esophageal and gastric varices rupture is one of the worst complications of liver portal hypertension.
11. The analysis of laboratory indexes in our study group found significant changes in the values of prothrombin, bilirubin and liver enzymes.

References

1. DOMLAND M., GEBEL M., CASELITZ M. et al. - Comparison of portal venous flow in cirrhotic patients with and without paraumbilical vein patency using duplex-sonography. Hochshull Med, 2000, vol.21, no.4, p.165-169.
2. MANGIA A., SANTORO R., CAPPUCCI G., LENDRO G. et al. - Portal venous thrombosis in cirrhotic patients: Role of genetic and biologic factors. Hepatology, 2001, vol.34, no.4, p.532-536.
3. RADOVICH P.A. - Portal vein thrombosis and liver diseases. J Vasc Nursing, 2000, vol.18, no.1, p.1-8.
4. SCHRAMM A, PECHAN J, KANDRIK R. - Portal vein thrombosis. Uncommon clinical picture. Bratisl Lek Listy, 2006, vol.107, no.1-2, p.31-33.
5. SEITZ K.,WERMKE W. – Ultrasound diagnosis of portal hypertension – current concepts. In: Sonography in portal hypertension and TIPS, Falk Foundation, Freiburg, 198, 5-46.
6. DHIMAN R.K., CHAWLA Y., TANEJA S. et al. - Endoscopic sclerotherapy of gastric variceal bleeding with N-butyl-2-cyanoacrylate. J Clin Gastroenterol, 2002, vol.25, no.3, p.222-227.
7. GOYAL N., SINGHAL D., GUPTA S. et al. - Transabdominal gastroesophageal devascularization without transection for bleeding varices: Results and indicators of prognosis. J Gastroenterol Hepatol, 2007, vol.22, no.1, p.47-50.
8. SHI B.M., WANG X.Y., MU Q.L. et al. - Value of portal hemodynamics and hypersplenism in cirrhosis staging. World J Gastroenterol, 2005, vol.11, no.5, p.708-711.
9. PLESTINA S., PULANIC R., KRALIK M. et al. - Color Doppler ultrasonography is reliable in assesing the risk of esophageal variceal bleeding in patients with liver cirrhosis. Wien Klin Wochenschr, 2005, vol.117, no.19-20), p.711-717.
10. GORKA W., AL MULLA A., AL SEBAEYL M. et al. - Quantitative hepatic venous Doppler sonography versus portal flowmetry in predicting the severity of esophageal varices in hepatitis C cirrhosis. Am J Roentgenol, 1997, vol.169, no.2, p.511-515.
11. KUTLU R, KARAMAN I, AKBULUT A et al. - Quantitative Doppler evaluation of the splenoportal venous system in various stages of cirrhosis: differences between right and left portal veins. J Ultrasound, 2002, vol.30, no.9, p.537-543.
12. SARIN S.K., PRIMIGNANI M., AGARWAL S.R. - Gastric varices. Portal hypertension III. Oxford. Blackwell Science Ltd, 2001, p.76-95.
13. TSAI H.M., LIU X.Z., CHANG Y.C. et al. - Hepatofugal flow on computed tomography of arterial portography: Its correlation with esophageal varices. Hepato-Gastroenterol, 2000, vol.47, no.36, p.1615-1618.

Correspondance to:

Roxana Folescu,
Department of Anatomy and Embryology, University of Medicine and Pharmacy "Victor Babes" Timisoara,
P-ta Eftimie Murgu Nr. 2,
300041,
Timisoara,
România,
E-mail: roxanafolescu@yahoo.com

A PARTICULAR CASE OF OVARIAN TERATOMA IN A CHILD

RE Iacob[1], M Soiu[1], Z Moldovan[1], H Osakwe[1], Maria Trailescu[1], Daniela Iacob[2]

Abstract

Ovarian teratoma or dermoid cyst is usually a benign ovarian tumour composed of a combination of tissues including epithelia, hair, teeth, bone fragments, thyroidal tissue, sebum, etc. This paper presents the case of a 4-year-old girl admitted in emergency with clinical signs suggesting the onset of acute appendicitis. The symptomatology, however, was the result of presence of right ovarian teratoma with torsion.

Key words: ovarian teratoma with torsion, child

Introduction

Ovarian teratoma or dermoid cyst is a round or oval shaped dysembryoma, with gray, ashen or yellowish, smooth, opaque or bright surface, having typically renitent consistency. Inside, we find organ rudiments originating in the three embryonic layers (ectoderm, mesoderm, and endoderm): cartilaginous, osseous, and muscle tissues, hair, teeth, nails, digestive or respiratory glandular epithelia, multi-layer pavement epithelium, thyroidal tissue and other tissues incorporated into a yellowish fat substance or sebum. Embryo fragments may sometimes be found.[1,2]

It has variable size, ranging from few centimetres to gigantic dimensions when it fills up the abdominal-pelvic cavity.

It is a unilocular, pediculate mobile tumour with well defined borders, having its own wall, and being usually located unilaterally.

Clinically, it has polymorphic symptomatology, while the cyst may be asymptomatic for long time. The diagnosis is made when the tumour becomes palpable, which is uncommon in children, or when one of the complications occurs.

Complications that may occur are:

1. Malignization – the most severe complication. Dermoid cysts are quite always benign tumours, but may become malignant.[3,4] Rapid growth of tumour that becomes immobile, onset of pain, adherence to adjacent organs (uterus, intestine), change in consistency, which becomes uneven and irregular, vascular compression disorders with oedema in lower limbs, worsening of general health accompanied by weight loss and ascitic fluid are all signs of malignization.[5,6]

2. Torsion is a frequent complication. It is seen in heavy, not very large cysts with a long pedicle. The symptoms are: onset of long-lasting acute pain, vegetative phenomena (vomiting, accelerated pulse).

3. Compression of surrounding organs and tissues followed by obstructive symptomatology.

4. Rupture – may be secondary to a trauma, torsion or intracystic haemorrhage. The cyst can rupture into the peritoneal cavity or rarely into an abdominal organ (urinary bladder, small bowel, rectum, sigmoid colon, and vagina).[7,8] The signs of rupture are: syncopal pain, signs of shock due to peritoneal irritation, cyst disappearance.

5. The infection is manifesting by: pain exacerbation, increase of body temperature, increased parietal defence. The most commonly implicated organisms are Coliform bacteria.[9,10]

Case presentation

The child CI, female gender, 4 years of age, of normal height and weight, is brought by her parents in the Emergency Room of the County Clinical Emergency Hospital on January 19, 2010 and admitted for abdominal pains starting 24 hours before, accompanied by nausea, vomiting, subfebrilities, and agitation.

Abdominal examination is difficult as the girl is frightened, cries, and voluntarily contracts her muscles. A painful sensitivity in the right iliac fossa is observed during inspiration periods, in the general clinical context suggesting the onset of an acute appendicitis.

Symptoms improvement and calming of patient after acquainting with the hospital room allows us to repeat under appropriate conditions the clinical examination, during which we find a normal abdomen that participates in the respiratory movements. A slight sensitivity is still present at the palpation of the right iliac fossa.

An *abdominal ultrasound* is performed, revealing the presence of a 4.8/3.5 cm tumour formation located posterior to urinary bladder, slightly right paramedian, of inhomogeneous aspect, showing hyperechogenic areas alternating with hypoechogenic and transonic areas, and 2 calcifications with posterior shadow cone – right ovarian tumour.

Laboratory analyses indicate: Erythrocytes = 4.03; Hb = 11.4; Ht = 33.6; Leucocytes = 7.47; Platelets = 326000; Urea= 17; Creatinine = 96; Glycaemia = 73; TGO = 23; TGP = 10; alkaline phosphatase = 168.72; LDH = 270; C reactive protein = negative; fibrinogen = 187; VSH = 123. Levels of CA125, the antigen specific to ovarian tumours, were in normal limits.

[1]County Emergency Hospital Arad – Department of Pediatric Surgery, Arad, Romania
[2]University of Medicine and Pharmacy – Department of Neonatology, Timisoara, Romania
E-mail: radueiacob@yahoo.com, mihai_soiu@yahoo.com, zenomold@yahoo.com, henrysan2007@yahoo.com, trailescumaria@yahoo.com, danielariacob@yahoo.com

We decide to perform *native and contrast CT examination* that during early and late stages indicates the following:

- At the pelvis level, anterior to rectum a space-replacing formation is evidenced, with mixed structure comprising lipid densities and included calcareous formations, as well as multiple cystic formations, with moderate absorption of contrast medium in the parenchyma, without contrast medium absorption at the cystic and calcareous components level. The lesion measures 3.5/5 cm in maxim axial diameters, well delimited, involving the right ovary, but neatly demarcated of the uterine corpus and anterior rectal wall, with urinary bladder compression and displacement.
- The urinary bladder presents walls with neat borders, homogenously opacified after 10 minutes.
- No pathological adenopathies at the retroperitoneal or pelvic levels are evidenced.
- No free fluid in the abdominal pelvic cavity is visualised.

Conclusions of CT Exam

Retrovesical space-replacing formation, involving the right ovary with aspect indicating most probably a dermoid cyst, presenting mixed content, lipomatous, liquid and multiple calcifications, neatly delimited of the uterine corpus and anterior rectal wall, impressing the urinary bladder, without invading the neighbouring structures (figure 1).

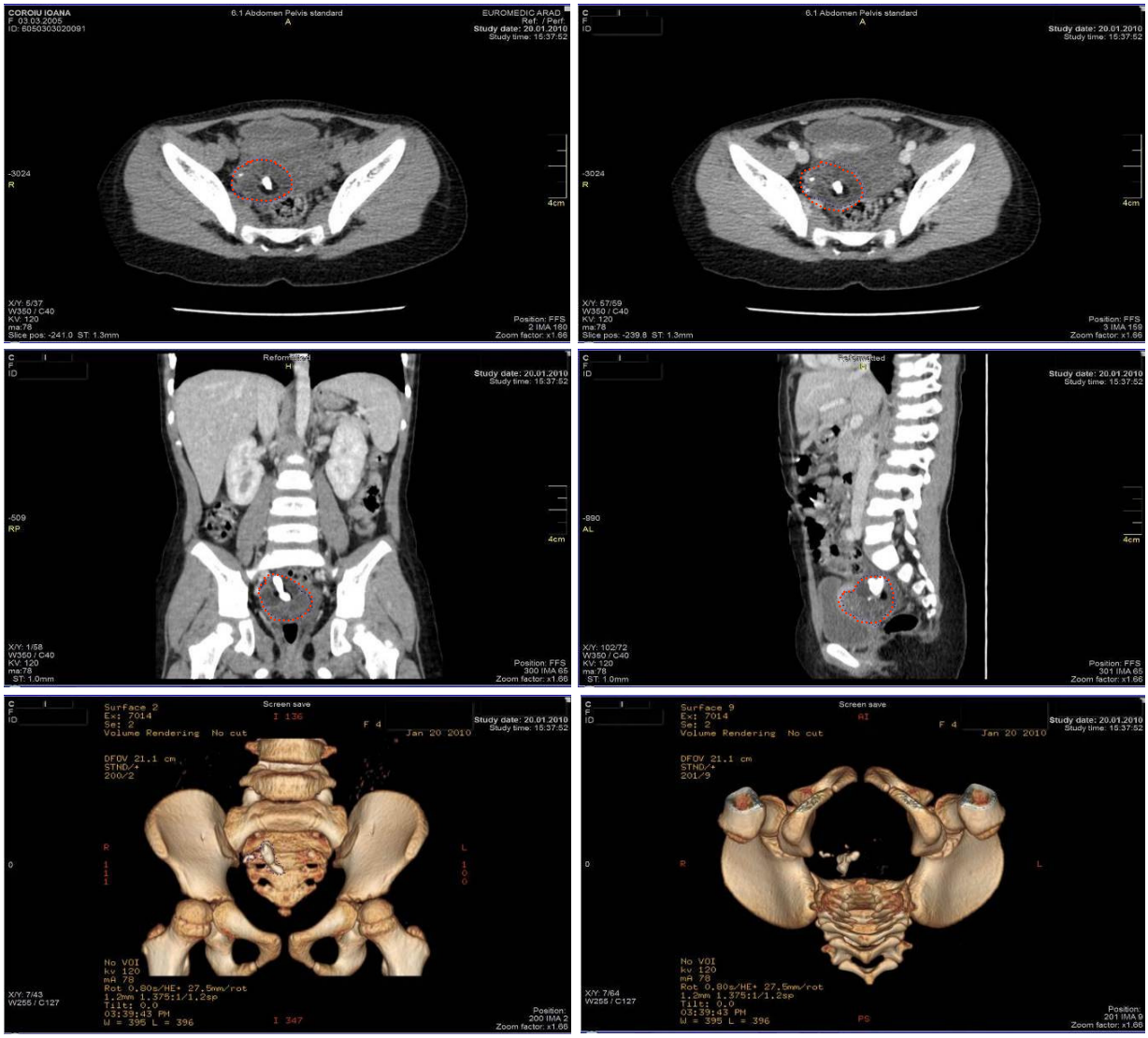

Fig. 1. CT aspect of cystic teratoma of the right ovary with calcifications.

Treatment

Surgery is performed on January 26, 2010 and subumbilical minilaparotomy under general anaesthesia is carried out. A right ovarian tumour formation, torsioned, extended into the Pouch of Douglas, with maximum diameter of approximately 5 cm, relatively round in shape, violaceous in colour, with neat and bright surface is evidenced. Ablation of tumour formation, preventive appendectomy and drainage of Pouch of Douglas are performed. No post-operative complication occurred,

allowing the removal of threads and discharge of patient 7 days after the surgery.

Histopathological exam of the resected formation reveals:

Mature cystic ovarian teratoma containing skin, hair follicles, hair, one molar tooth and nervous tissue (figure 2), with areas of chronic granulomatous inflammatory reaction and "foreign body" multinucleated giant cells and ovarian, pericystic, intraparenchymal haemorrhagic foci; two resting primordial follicles are present.

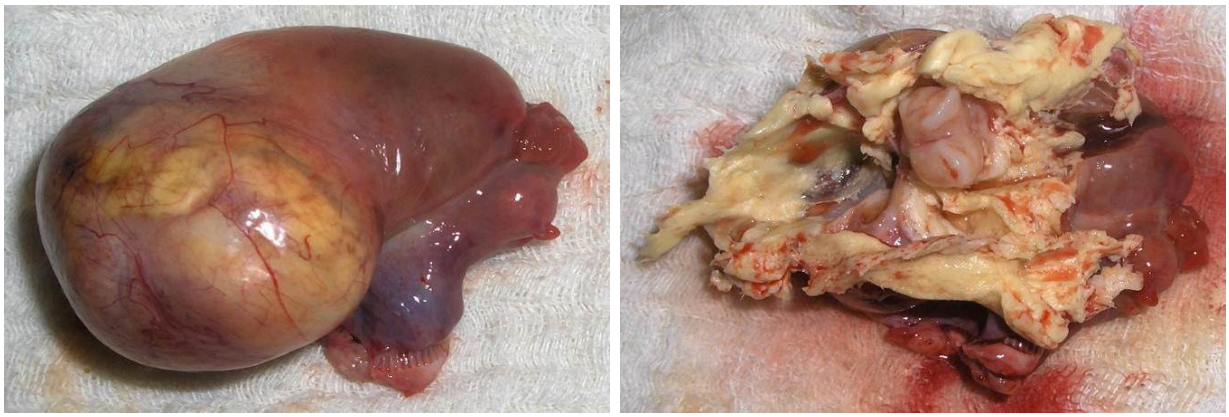

Fig. 2. Macroscopic aspect of torsioned cystic teratoma of the right ovary.

Conclusions

Ovarian teratoma, more frequently seen in adult females, can be rarely diagnosed in the first years of life.

It is usually asymptomatic, while the first sign is most frequently represented by the increase of abdominal volume through tumour growth.

It is occasionally diagnosed following a complication, most often represented by torsion.

When it is located on the right side, the symptomatology may be confused with that in acute appendicitis.

References

1. Kumar V, Abbas AK, Fausto N. Robbins and Cotran Pathologic Basis of Disease. 7th ed. Philadelphia: Elsevier Saunders; 2005.
2. K. K. Deodhar, P. Suryawanshi, M. Shah, B. Rekhi, and R. F. Chinoy, "Immature teratoma of the ovary: a clinicopathological study of 28 cases," Indian Journal of Pathology andMicrobiology, vol. 54, no. 4, pp. 730–735, 2011.
3. Stany MP, Hamilton CA. Benign disorders of the ovary. Obstet Gynecol Clin North Am. Jun 2008;35(2):271-84, ix. [Medline].
4. Wu RT, Torng PL, Chang DY, et al. Mature cystic teratoma of the ovary: a clinicopathologic study of 283 cases. Zhonghua Yi Xue Za Zhi (Taipei). Oct 1996;58(4):269-74. [Medline].
5. Rushton HG, Belman AB. Testis-sparing surgery for benign lesions of the prepubertal testis. Urol Clin North Am. Feb 1993;20(1):27-37. [Medline].
6. Ulbright TM. Germ cell neoplasms of the testis. Am J Surg Pathol. Nov 1993;17(11):1075-91. [Medline].
7. V. Upadhye, S. Gujral, A. Maheshwari, R. Wuntkal, S. Gupta, and H. Tongaonkar, "Benign cystic teratoma of ovary perforating into small intestine with coexistent typhoid fever," Indian Journal of Gastroenterology, vol. 24, no. 5, pp. 216–217, 2005.
8. A. R. von-Walter and R. S. Nelken, "Benign cystic ovarian teratoma with a fistula into the small and large bowel," Obstetrics & Gynecology, vol. 119, part 2, no. 2, pp. 434–436, 2012.
9. Ayhan A, Bukulmez O, Genc C, Karamursel BS, Ayhan A. Mature cystic teratomas of the ovary: case series from one institution over 34 years. Eur J Obstet Gynecol Reprod Biol. Feb 2000;88(2):153-7. [Medline].
10. Benjapibal M, Boriboonhirunsarn D, Suphanit I, Sangkarat S. Benign cystic teratoma of the ovary : a review of 608 patients. J Med Assoc Thai. Sep 2000;83(9):1016-20. [Medline].

Correspondance to:

Radu Emil Iacob,
Transilvania Street, No. 13, Sc. C, Ap. 7,
Timisoara, 300143,Romania
Telephone: 0745614590
E-mail: radueiacob@yahoo.com

LAPAROSCOPIC APPROACH IN RECTO-COLIC DISEASES IN CHILDREN

M Oancea[1,2], Lorena Vatra[2], Anna Kadar[2]

Abstract

Objectives: This paper is intended to analyze the clinical applicability and efficiency of the laparoscopic recto-sigmoidian resection in children suffering from congenital megacolon and chronic idiopathic constipation.

Material and method: Between April 2001 - June 2012 were operated on 49 children diagnosed with congenital megacolon or medically intractable chronic constipation. We excluded from the analysis 7 children operated on according to the Duhamel procedure, 6 cases in which the intervention was performed in a transanal (TERPT) manner, a newborn with a total aganglionic form who died shortly after ileostomy and two cases who were out of the records after colostomy. A laparoscopic rectosigmoidian resection was practiced in 31 cases, with a mean age of 3.8 years (6 weeks-17 years), and in two cases the intervention was limited to multiple intestinal biopsy. Recto-colic laparoscopic biopsy was performed in 20 patients: 5 times before surgery, 8 times when practicing colostomy and in 7 cases during definitive surgery. In the remaining patients the resection was assessed by changes in the colic wall appearance; histological examination were practiced on the fragments of the specimen. In 8 cases the final operation was preceded by temporary colostomy practice and in a single case by an ileostomy. Preoperative preparation of the colon was made after a variable schedule depending on the age of the patient and volume of the fecal retention. The standard approach- rectosigmoid resection is performed with optic trocar in the right upper quadrant and with two pararectal working trocars placed on the right and on the left. Oral nutrition was allowed from the first postoperative day, depending on recovery of the bowel movement. Patients were discharged on average, 9 days after surgery.

Results: There were no significant differences in postoperative outcome between children operated on for congenital megacolon (21 patients) and those for severe constipation (10 patients). Intestinal transit recovery was noted immediately, in day I-III, but, in some cases, followed by variable periods of bowel movement disorders requiring treatment. Patients were discharged, on average, 9 days after surgery. Soiling persisted in 4 of the patients at the time of analysis. In one of the patients redo surgery was required because of inadequate resection of the aganglionic segment. We recorded two cases of anastomotic fistula resolved by temporary colostomy. One of the patients developed an anastomotic stenosis. In this series we registered no deaths.

Conclusions: Laparoscopic approach allowed personalized diagnostic strategy and improved surgical therapy results in colic motility disorders in children.

Key words: congenital megacolon, chronic constipation, laparoscopy.

Introduction

Aganglionic colorectal resection and restoration of digestive continuity with preservation of functional anal sphincter structures was felt that the logical treatment of megacolon and applied in the clinic for the first time by Orvar Swenson in 1948 (1). The analysis of Swenson operation results allowed the identification of complications and unsatisfactory results that were directly related to the surgical approach- low rectal resection with coloanal anastomosis performed by combined abdomino-perineal approach. Trying to correct the Swenson operation, B.Duhamel proposed in 1956, an operation in which, after bowel resection, aganglionic rectum is preserved under the promontory (2), and in 1964 F.Soave proposed rectal mucosectomy, keeping rectal muscle sheath and pull through of the normal bowel within it (3). Accumulating significant number of patients, operated through these methods, showed that keeping the rectum becomes a source of limiting quality therapeutic results. In 1995 K.Georgeson (4) enters into practice rectosigmoidian resection and abdomino-perineal pull-through in one stage performed by laparoscopy.

The purpose of this paper is to present the initial series of patients operated on laparoscopic and to evaluate the safety and effectiveness of the method.

Material and method

From April 2001 to June 2012 were treated 49 children affected by severe forms of colic motility disorders, diseases occurring outside a general, endocrine or lumbo-sacral spinal injuries. We use both contrast enema(fig.1, fig.2) and histopathologic exam to diagnose congenital megacolon or idiopathic constipation. Patients diagnosed with idiopathic constipation were operated on only after failure of medical therapy and bowel management program.

[1]University of Medicine and Pharmacy "Victor Babes" Timisoara – phD student
[2]"M.S.Curie" Emergency Hospital for Children Bucharest – Pediatric Surgery Department
E-mail: mar_oancea@yahoo.com, lorena.vatra@rodelta.ro, kadar_anna@hotmail.com

Fig. 1 Congenital megacolon-contrast enema.

Fig. 2 Idiopathic constipation-contrast enema.

This study refers to 33 children, with a mean age of 3.8 years (2 weeks-17 years) who were operated on by laparoscopy. 31 recto-colic resections and coloanal anastomosis were practiced and 5 colic biopsies as unique laparoscopic surgery. In 4 cases the resection exceeded the left angle of the colon. "Full-thickness" colic biopsy was practiced 5 times preoperatively and 7 times in the beginning of surgery (extemporaneous histopathological examination). In the other 8 cases histopathological examination was performed before definitive surgery, when practicing external digestive derivation. In the remaining patients, the level of the colic resection was determined intraoperative according to appearance of the colon. Temporary colostomy was closed at the time of definitive surgery, except in a case with multiple postnatal cecal perforations, in which we left in place ileostomy practiced at birth. General preoperative preparation of patients was the standard one for major surgery. Colic preparation for surgery was performed according to the child's age. It was limited to evacuation and colic lavage with antiseptic solution on the operating table in infants, and went to the mechanical evacuation under anesthesia followed by administration of laxatives and enemas in cases with important fecal impaction.

OPERATIVE TECHNIQUE:

Very young children are placed supine across the operating table. We start with sterile drape below the nipple designed for double approach: abdominal and perineal - "total body preparation". The surgeon is placed at the patient's head, the camera at the operator's left arm and the video system at patient's feet. Pneumoperitoneum is set to achieve values of (6) 8-12 mmHg, the optical trocar is placed in the right upper quadrant in an open manner. Working trocars are positioned right and left at the level of the pararectal line. An additional working trocar can be placed in the left upper quadrant. The surgery begins by creating a mesenteric window at the level estimated as the upper limit of the resection. Sigmoid dissection is followed by rectal dissection beneath the levator's level. The perineal stage includes exposure of the anal canal and rectum using circumferentially stiches placed approximately 1 cm above the dentate line. It is followed by the incision and dissection of the mucosa up to 3-4 cm, crossing the muscular wall and dissecting in the perirectal space to meet the plane of the abdominal dissection. Then we pull through and resect the dissected bowel performing a coloanal anastomosis.(fig.3 and 4) It is recommended in postoperative period to keep the nasogastric tube in place for decompression and to give nothing per oral for 12-24 hours, depending on the extent of the surgery. It is recommended checking the caliber of the anastomosis at 14 days after surgery.

Results

Digestive tolerance and bowel movements were restored in 24 -36 hours after surgery, depending on the patient's age, but there were noticed in some cases, variable periods of bowel movement disorders requiring medical treatment. In one patient there was a late recovery of intestinal transit, on the 7 p.op. day, without any sign of anastomotic or peritoneal complications. Oral feeding was allowed 12-24 postoperative hours. Analgesic therapy was always kept 72 hours postoperatively. Discharge patients was made, on average, 9 days after surgery, the average value over the published series, but directly influenced by the 3 cases with complicated evolution: two anastomotic fistulas and one incomplete resection. Persistent soiling uninfluenced by medical treatment, is present in 4 patients at the time of evaluation. Two of the operated patients developed anastomotic fistula with generalized peritonitis.

Those two have been revised by laparotomy and temporary colostomy was performed. In one patient, which first underwent a laparoscopic resection surgery, I practiced initially a temporary colostomy and then I practiced a redo laparoscopic approach for remaining aganglionic bowel resection. We recorded one single anastomotic stenosis - an anastomotic fistula consequence which we controlled by periodic dilatations. There is no death recorded.

Fig. 3 Resection of the pulled bowed.

Fig. 4 Laparoscopically dissected bowel.

Comments

K.Georgeson was the first who reported a rectosigmoidian resection for megacolon by laparoscopic approach (4). The operation is actually a Swenson intervention with adaptation of the anal stage with technical elements taken from Soave technique. N.Bax reported laparoscopic reproduction of the Duhamel technique (5), but the largest reported series reveals a preference for lap Swenson technique. Laparoscopic surgery corrects one of the issues that were considered key quality outcomes for surgery: the aggressiveness of pelvic dissection of the various techniques. Compared with open surgery, minimally invasive approach is characterized by significantly reducing operative trauma, absence of parietal incisions, limiting visceral handling, reduced postoperative pain, decreased need for medication, general status and rapid recovery of gastrointestinal function, early resumption oral diet, limit the duration of hospitalization (6). Certain superiority of laparoscopic approach consists of quality of the pelvic rectal dissection, one of the risk elements in classic operations that can be done, in perfect conditions of visibility and safety in laparoscopic surgery (7). Improvement of all immediately postoperative clinical parameters is a common feature in laparoscopic surgery, but we should underline that some patients are carriers of intestinal stoma and may require laborious adhesions dissection, or closing or repositioning the stoma, partially modifying the immediate postoperative data. In our clinical series 8 patients had colostomy at the time of definitive surgery. We performed colostomy in emergency situations, when it was impossible to perform curative surgery and in those situations when colonic emptying was impossible in order to perform a safe surgery.

We prefer to perform laparoscopic Swenson approach with optical trocar in the right upper quadrant and pararectal working trocars right and left below the umbilicus. When the colon is too much distended we add a left upper quadrant working trocar. This type of trocar placement allows easily to restore the operating field for total colectomy when it is necessary to mobilize the left colic angle or transversal colon resection. We resected the transverse colon below the right colic angle in 4 cases: in higher forms (1 case) and because of colostomy placed at this level (3 cases). We prefer to take colic biopsy before definitive surgery. We avoid endorectal biopsies due to subsequent intraoperative difficulties and prefer taking them when practicing colostomy. We performed multiple colic biopsies in 13 patients, of which 8 (16%) when practicing colostomy. Biopsy was performed 7 times at the beginning of definitive surgery. In the absence of biopsy, intraoperative appearance of the colon is an important decision regarding the resection level, but not enough. Under these conditions we performed an inadequate resection requiring colostomy and reoperation by laparoscopic approach. Two of our patients developed anastomotic fistula requiring open reintervention and temporary colostomy.

We believe that fistula occurred as a consequence of difficulties during coloanal anastomosis due to a mismatch segments (one case) and because of the tension at the level of the anastomosis. It is recommended to resect the dilated segment even if is histologically healthy, but we should avoid, in general, descending a very much stretched colon to the perineum, because it can cause further development of incontinence. Laparoscopic surgery favors early recovery of intestinal functions in the postoperative period, but we found difficulties in bowel movement recovery in those children in whom the preoperative preparation was made with strong medication or for a longer period of time (more than 2 days). We did not recorded acute enterocolitis in the immediate postoperative period, but 12 of the patients needed 3-5 months to reach a number of 1-2 bowel movements/day. At the time of follow-up 4 children presented soiling. All these patients were included in a

bowel management program consisting of: constipating diet, administration of pectin, small volume enemas and medication that reduces colic motility. (8) One of the patients present a minor degree of anastomotic stricture secondary to postoperative fistula and he is on a regularly program of dilatation –once in three months. Our series does not register patients that develop chronic constipation in the postoperative period. It is estimated that rectosigmoid resections performed by laparoscopy avoid residual constipation which is noted in approximately 15-20% of patients operated according to Duhamel or Soave procedures, but favors increased frequency of postoperative incontinence. It is estimated that excessive exposure of the anal canal disrupt the internal anal sphincter fibers, decreasing its functional capacity.

Conclusions

Autonomous innervation disorders of the rectum and colon are the most common cause of low intestinal obstruction in children. Excluding the technical imperfections regarding these cases, we believe that unsatisfactory results in the treatment of these types of lesions should be sough to the limit where the pathology of the autonomic nervous system of the intestine is understood in this moment. Laparoscopic approach for rectocolic resection minimize intraoperative trauma and improve early and late postoperative outcome.

References

1. Swenson O, Bill AH Jr:-Resection of rectum and sigmoid with preservation of sphincter for benign spastic lesion producing Hirschsprung's disease. An experimental study.-Surgery 24:212-220, 1948
2. Duhamel B: Une nouvell operattion pour le megacolon congenital: l'abaissement retrorectal transanal du colon et son application possible au traitement de quelques autres malformations. Presse Med. 64, 22-49, 1956.
3. Soave F: A new surgical technique for treatment of Hirschsprung's disease; Surgery 56:1007-1014, 1964
4. Georgeson KE, Feufner MM, Hardin WD, - Primary laparoscopic pull-through for Hirschsprung's disease in infants and children. J.Pediatr.Surg. 30: 1017-1022, 1995
5. Bax NMA, van der Zee DC (1994): Laparoscopic removal of the aganglionic bowel according to Duhamel-Martin in five consecutive infants. Pediatr.Surg.Int. 10:226-228
6. Oancea M, Draghici Isabela, Cristea D, Simionescu Lorena, Stefan D: Coborarea abdomino-perineala pe cale laparoscopica in tratamentul megacolonului congenital la nou nascut si copil – Nota de tehnica chirurgicala, Med. Moderna vol.X Nr 2 /2003 pg 77-79
7. Curran TJ, Raffensperger JG: Laparoscoppic Swenson Pull-Through: A Comparison With the Open Procedure, J.Pediatr.Ssurg. 31: 1156-1157 1996
8. Levitt MA, Dickie B, Pena A: Evaluation and treatment of the patient with Hirschsprung's disease who is not doing well, Semin.Ped.Surg. 19: 146-153, 2010
9. Saleh W, et al. Management of Hirschsprung's disease: a comparison of Soave's and Duhamel's pull-through methods Pediatr.Surg.Int.20: 590-593 2004

Correspondance to:
Marcel Oancea,
Spitalul Clinic de Urgenta pt.Copii "MS Curie"
B-dul. C-tin Brancoveanu, Nr.20, Sect. 4
Bucuresti,
România,
E-mail: mar_oancea@yahoo.com

JUVENILE NASOPHARYNGEAL ANGIOFIBROMA - CASE REPORT

Dana Florentina Gidea[1], G Iovanescu[1,2], S Cotulbea[2,3], Ghiran Ramona Maria[3], Delia Horhat[1,2]

Abstract

Juvenile nasopharyngeal angiofibroma is a rare highly vascular, benign tumor, very aggressive locally, affecting male adolescents or those at puberty. The occurrence in other age groups or in women is exceptional. The agresiveness and high vascularization make surgery very difficult, and surgical biopsy is not recommended. Surgery is the main method of treatment used, especially for early stages, while for advanced stage cases and having intracranial extension, radiation remains the chosen therapeutic option. In order to establish a preoperative diagnosis and staging, we use CTscan imaging or MRI with and without contrast material as well as angiography. In this study we will present a 20-year-old patient suffering from juvenile nasopharyngeal angiofibroma who was diagnosed using a CT scan. The tumor was successfully removed surgically and the HP examination confirmed the diagnosis. The 7 months post-surgery evolution was favorable.

Key words: Angiofibroma, nasopharyngeal, paralatero-nasal, CTscan

Introduction

Juvenile nasopharyngeal angiofibroma is a rare, histologically benign tumor of the nasopharynx, affecting almost exclusively male teenagers or at puberty, being diagnosed in 14-25 old boys. It is a highly vascularized tumor with high tendency towards local and loco-regional invasion, with extension within the subbmucosa. For this reason it's a distructive tumor. From a histological point of view, it's a mezenchymal tumor, vascular, having high cells, composed of fibrous connective tissue and abundant vascular endotelium lined spaces (1). There are various theories regarding the formation of angiofibroma, but the most accepted theory is the theory of angiogenesis and histogenesis. This describes angiofibroma as a pure vascular tumor which proliferates in a hemangiomatous manner and in which all other components, including fibrous connective tissue, are derived from non-differentiated vasoformator mezenchymal (2). The tumor origin can be found on the posterolateral wall of the nasopharynx at the upper edge of the sphenopalatine foramen, which is also a way for the sphenopalatine artery, a branch of the internal maxillary artery (3,4). More exactly, it is located where the sphenoid process of the maxilar bone meets the horizontal wing of the vomer and pterygoid foot of the sphenoid (5). The juvenile nasopharyngeal angiofibroma represents 0.5% of head and neck neoplasms and is considered the most common benign neoplasm of the nasopharynx (2, 5, 6, 7). Despite its benign nature, the local growth and destruction method can cause bone remodeling. Although it does not produce bone erosion, the tumor has a high potential of life threatening complications such as: epistaxis, intracranial extension and massive intraoperative bleeding (8-10).

Classic signs of juvenile nasopharyngeal angiofibroma are progressive nasal obstruction and / or epistaxis and rhinorrhea, together with other symptoms that are dependent on the direction and extent of the tumor (6). The tumour extension in adjacent areas can cause "swelling facial" type deformities as well as proptosis.

Diagnosis is based on history, clinical examination and radiological and imaging results, knowing that biopsy is not recommended.

Angiography helps demarcate the tumor's blood supply and identify the vessels that feed it. However its real use is still questionable. Surgical excision was the main angiofibroma treatment and the approach normally depends on the tumor extension. An important role in this regard is played by the CT scan and appropriate staging.

Case Report

In February 2012, a 20-year-old male residing in a rural area arrives at the ENT Clinic in Timisoara. From history we learn that the young man suffers from left side unilateral nasal obstruction, headaches, oral breathing, repeated epistaxis from the left nasal fossa which have been persisting for 2 years. From history we learn that the young man was operated in 2001 for nasal polyps.

The ENT clinical examination reveals while performing anterior rhinoscopy that the posterior half of the left nasal fossa is occupied by a white tumoral formation, smooth, firm, without other local changes. While performing posterior rhinoscopy we observe a nasopharynx occupied entirely by the tumor. The external facial aspect shows no phisionomy or left / right symmetry feature changes.

[1]Emergency Country Hospital Timisoara
[2]UMF Victor Babes Timisoara
[3]Municipal Emergency Hospital Timisoara
E-mail: danafv@yahoo.com, giovanescu@gmail.com, cotulbea@umft.ro, ramonaghiran@yahoo.com, deliahorhat@yahoo.com

A CT scan with bone contrast and MRI are performed, which show a well defined left nasopharyngeal tumor mass, containing soft tissue, which reaches the soft palate on the left and enters the left nasal fossa and bulges the medial wall of the maxillary sinus by volume compression, without causing bone erosion (left maxillary sinus integral medial wall bone contour), left maxillary sinusitis with nasal septum deviation to the right due to tumor volume in the left nasal fossa, without changing its bone contour, and extension in the pterygopalatine fossa and left infratemporal fossa (fig. 1 and 2).

Fig.1. Skull MRI axial section highlighting left nasal fossa tumoral extension, nasopharynx, pterygopalatine fossa and infratemporal left fossa.

Fig.2. Skull CT scan axial section visualizing the lump in the left nasal cavity, nasopharynx, and pterygopalatine fossa and infratemporal left fossa.

The patient is hospitalized in our ENT clinic in Timisoara on 03/07/2012 when after clinical examination and imaging he is diagnosed with juvenile nasopharyngeal angiofibroma and is proposed to have surgery, which is accepted by the pacient. We begin preoperative preparations with biological and interdisciplinary investigations appropriate for this type of surgery, according to agreed protocol, which includes preanesthezic consultation. The surgical intervention takes place on 03/13/2012 in AG with IOT, intraoperative bleeding control technique by controlled hypotension.

Surgery is performed in two stages:

- *stage 1* - left laterocervical horizontal incision, 4 cm of the mandibular arch, removing the subcutaneous tissues, highlighting the left sternocleidomastoid muscle, highlighting the hypoglossal nerve, and the tiro-glossal-facial veinous trunk - anteroinferior (Farabeuf triangle); with highlighting the common carotid artery and its bifurcation. Necessity ligation of the venous trunk is performed and a waiting thread is placed on the left external carotid artery. (fig. 3).

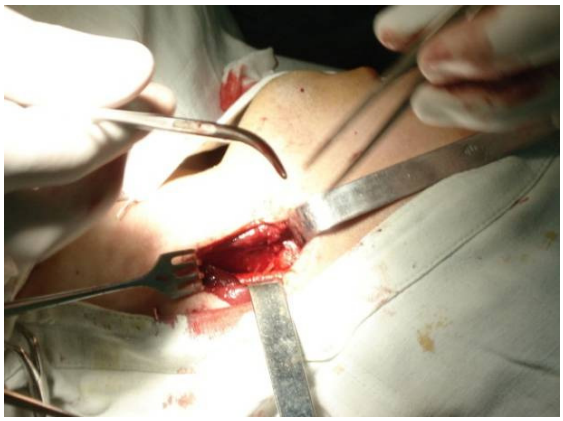

Fig. 3. Ligation of the venous trunk and waiting thread on the left external carotid artery.

- *stage 2* – the chosen approach was a left paralateronasal incision ranging from the nasal vestibule to 1 cm of the internal edge, removing and delimiting a firm, hard tumoral formation, with very fixed insertion on the maxillar, on the ethmoid bones and sphenoid horn. Total tumor ablation is performed as well as hemostasis by anterior and posterior compressive dabbing (fig. 4). A sample is taken from the extracted piece for histopatological examination. On the 16.03.2012 dabbing is done with no active bleeding.

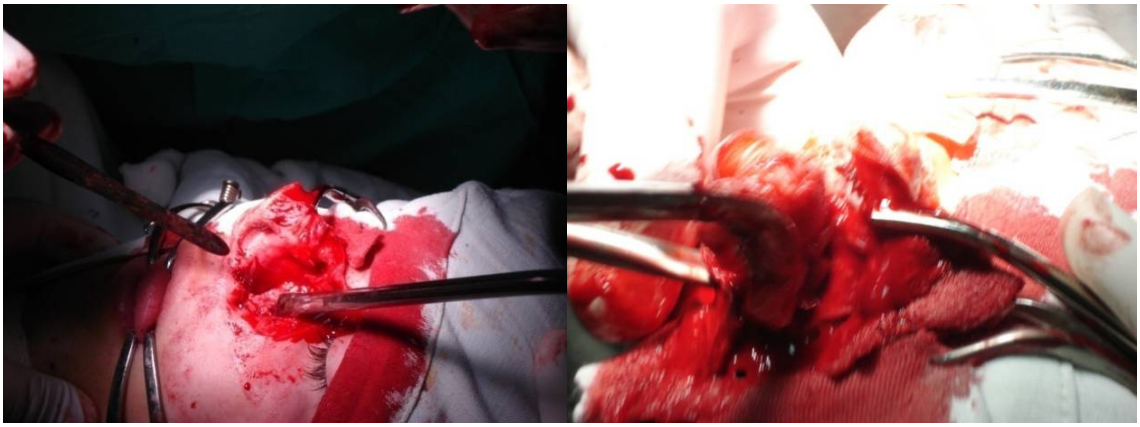

Fig. 4. Paralateronasal approach and extraction of the lump.

Positive diagnosis was based on history, clinical ENT examination imaging laboratory tests, intraoperative findings and HP (fig. 5). The histopathological examination describes a proliferating tumor consisting of connective-fibrous tissue, with hyalinization areas including vascular thin-walled spaces and blood vessels of different sizes (small and large), some with thin walls, some with thickened walls or deformed by compression exerted by connective tissue. Myxoid areas focally observed. Stromal cells present nuclei with moderate pleomorphism. These histological aspects advocate for nasopharyngeal angiofibroma. Thus the diagnosis of juvenile nasopharyngeal angiofibroma clinical stage IIC, according to the Radkowski classification of 1996.

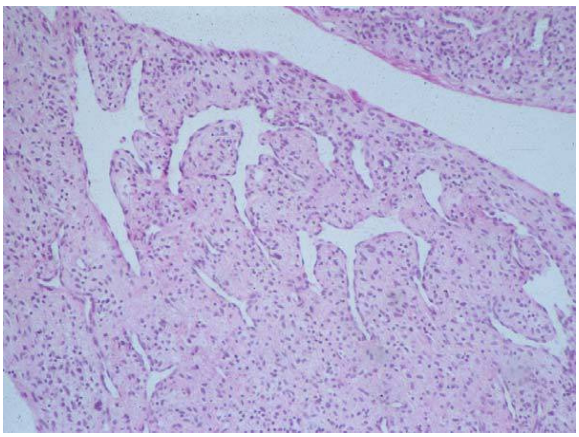

Fig. 5. Cells of origin are myofibroblast.

Differential diagnosis is made: sinuso-choanal polyp, osteom, craniopharyngioma, neuroblastoma, chordoma, chondrosarcoma, rhabdomyosarcoma, nasopharyngeal carcinoma, hemangiopericytoma.

Evolution is expected to be good, with no further relapse, given that the patient underwent radical surgery and that he is at an adult age. The patient will be clinically and imagistically cared for in a dispensary (nasal and nasopharyngeal endoscopy). The prognostic is positive.

Currently, 7 months after the surgery, the patient has a good evolution without recurrence of clinical changes; the imaging assessment being performed at 24 months postoperatively.

Postoperative complications that can occur are: infraorbital nerve injury, atrophic rhinitis crust, anosmia, serious medium otitis, local dental complications, sinusitis.

Discussions

Tumor incidence is rare, being found predominantly in the developing males. The occurrence age varies between 11-20 years with an average of 14 years (3). The ocurrence exclusively in boys is probably related to androgen receptors (5). Diagnosis is made mainly on clinical manifestations of the tumor. Most of the times, the present of the triad: progressive nasal obstruction, epistaxis and nasopharynx tumor in young men suggests the diagnosis of juvenile nasopharyngeal angiofibroma. In some studies the appearance of anterior radiological bulging of the posterior wall maxillary sinus (antral sign) is a pathognomonic sign. An essential role in preoperative diagnosis of the angiofibroma is played by endoscopic evaluation of the patient, and imaging: CT scan and MRI, which apply to all patients evaluated in our clinic. It is well known that

preoperative biopsy should be avoided because of the risk of subsequent massive hemorrhage. Therefore preoperative diagnosis is a stage diagnosis, because the safety diagnosis is established only postoperatively by histopathological examination from the surgically extracted piece.

The choice of surgical technique is still debatable, but surgery remains the main treatment that completely removes the tumor. Traditional techniques used in surgical treatment of juvenile nasopharyngeal angiofibroma are: transpalatal technique, transpharyngean, Denker-Rouge, medial maxilectomy, lateral transfacial rhinotomy, mediofacial degloving and Le Fort I osteotomy, as well as infratemporal or subtemporal lateral approach. In this case the technique used was the paralateronasal approach (12).

The preoperative hormonal therapy with estrogen and progesterone is without noticeable effects (5).

External radiation radiotherapy treatment is made with doses of 3600-4600 cGy/23Fr/5Fr/week/31 days after CT simulation. Complications that can occur after or during radiation therapy are: epistaxis, panhypopituitarism, temporal lobe necrosis, cataracts, post-irradiation keratitis (6).

Regional selective embolization proves to be effective only for stage I patients. It can be used preoperatively to reduce the vascular intake in case of endoscopy approach. It is burdened by complications such as soft tissue and skin necrosis, facial paralysis or endocranial complications.

For unresectable tumors, chemotherapy may be used as an alternative to radiotherapy; the most commonly used chemotherapy drugs are Adriamycin and Decarbazin (8).

Conclusions

Juvenile nasopharyngeal angiofibroma is a benign, rare tumor of the nasopharynx, which, due to its strategical anatomical position can affect several vital structures of the skull base.

The tumor almost exclusively affects male teenagers. The triad: progressive nasal obstruction, epistaxis and tumor mass in the nasopharynx leads to the clinical diagnosis of juvenile nasopharyngeal angiofibroma. The nasopharynx tumor size is not necessarily in accordance with the real tumor extension and size, it can be only the "tip of the iceberg". Extranasopharyngeal extension is very common in all cases - the most common being the nasal extension.

A CTscan with contrast material is pathognomonic for the diagnosis of juvenile nasopharyngeal angiofibroma and allows accurate staging of the tumor, which is very necessary for choosing the surgical technique, estimating prognosis and reporting results.

Radio therapy must be reserved for inoperable cases, for recurrences or for patients who refuse surgery because of various reasons.

References

1. Ungkanont K, Byers RB, Weber RS, Callender DL, Wolf PF, Goepfert H (1996) Juvenile nasopharyngeal angiofibroma: an update of therapeutic management. Head Neck 18:60–66
2. Beranek JT, Massayeff R, Desmet VJ (1986) Hyperplastic capillaries and their possible involvement in the pathogenesis of fibrosis. Histopathology 10:543–551
3. Antonelli AR, Cappiello J, Di Lorenzo D, Donajo CA, Nicolai P, Olandi A(1987) Diagnosis, staging, and treatment of juvenile nasopharyngeal angiofibroma(JNA). Laryngoscope 97:1319-1325
4. Barnes l, Kapadia SB (1994) The biology and pathology of selected skull base tumors. J Neuro Oncol 20:213–240
5. Brentani MM, Butugan O, Oshima CT, Torloni H, Paiva LJ (1989) Multiple steroid receptors in nasopharyngeal angiofibroma. Laryngoscope 99:398–401
6. Enepekides DJ (2004) Recent advences in the treatment of juvenil angiofibroma. Curr Opin Otolaryngolog Head and Neck Surg 12:495-499
7. Gantz B, Seid AB, Weber RS (1992) Controversies: nasopharyngeal angiofibroma. Head Neck 14:67–71
8. Glad H, Vainer B, Buchwald C, Petersen BL, Theilgaard SA, Bonvin P, Lajer C, Jakobsen J (2007) Juvenile nasopharyngeal angiofibromas in Denmark 1981–2003: diagnosis, incidence, and treatment. Acta Otolaryngol 127:292–299
9. Gruber B, Kron TK, Goldman ME (1985) Nasopharyngeal angiofibroma in two young children. Case reports. Otolaryngol Head Neck Surg 93:803–806
10. Herman P, Lot G, Chapot R, Salvan D, Huy PT (1999) Longterm follow-up of JNA. Laryngoscope 109:140–147
11. Hofmann T, Bernal-Sprekelsen M, Koele W, Reittner P, Klein E, Stammberger H (2005) Endoscopic resection of juvenile angiofibromas-long term results. Rhinology 43:282–289
12. Kennedy JD, Haines SJ (1994) Review of skull base surgery approaches with special reference to pediatric patients. J Neuro Otol 20:291–312
13. Paris J, Guelfucci B, Moulin G, Zanaret M, Triglia JM (2001) Diagnosis and treatment of juvenile nasopharyngeal angiofibroma. Eur Arch Otorhinolaryngol 258:120–124
14. Marshall AH, Bradley PJ (2006) Management dilemmas in the treatment and follow-up of advanced juvenile nasopharyngeal angiofibroma. ORL 68:211–216
15. Mann WJ, Jecker P, Amedee RG (2004) Juvenile angiofibromas: changing surgical concept over the last 20 years. Laryngoscope 114:291–293
16. Radkowski D, Mcgill T, Healy GB, Ohlms L, Jones DT (1996) Angiofibroma: changes in staging and treatment. Arch Otolaryngol Head Neck Surg 122:122–129
17. Reda HK (1996) Transnasal endoscopic surgery in JNA. J Laryngol Otol 110:962–968

18. Scholtz AW, Appenroth E, Kammen-Jolly K, Scholtz LU, Thumfart WF (2001) Juvenile nasopharyngeal angiofibroma: management and therapy. Laryngoscope 111:681–687
19. Schuon R, Brieger J, Heinrich UR, Roth Y, Szyfter W, Mann WJ(2007) Immunohistochemical analysis of growth mechanisms in juvenil nasopharyngeal angiofibroma.Eur Arch Otorhinolaryngolog 264:389-394
20. Tosun S, Ozer C, Gerek M, Yetiser S(2006) Surgical approaches for nasopharyngeal angiofibroma: comparative analysis and curent trends. J Craniofac Surg 17:15-20

Correspondance to:
Dana Florentina Gidea
Brandusei Street, numb.9,
Timisoara
Phone: 0748117540
E-mail: danafv@yahoo.com

TIBIAL SPINE AVULSIONS IN THE SKELETALLY IMMATURE

D Vermesan[1], R Prejbeanu[1], H Haragus[1], S Vermesan[2], G Damian[3]

Abstract

In children, displaced avulsions of the tibial spine are equivalent to ruptures of the anterior cruciate ligament. They present to general orthopaedists as well as a wide variety of orthopedic subspecialty surgeons including sports medicine and pediatrics. Restoration of normal knee kinematics is dependent on anatomic reduction and fixation of the avulsed fragment. Given these premises we aimed to evaluate the current treatment of displaced tibial spine fractures in the skeletally immature in our clinic.

We performed a retrospective review of displaced avulsions of the tibial spine in skeletally immature patients treated in our clinic over the last years and identified 4 cases: 3 girls and one boy, with a mean age of 12 (11-14). One case was type II and three were type III. All were treated operatively: 2 with arthroscopic / mini-open reduction and internal fixation using wire, one with screw and one with 2 K wires.

The patients had the final follow-up evaluation at a mean of 20 months after index surgery. All had IKDC scores for excellent and good outcomes. Three out of four cases had increased manual antero-posterior tibial translation without subjective feeling of instability. All patients had regained full range of motion by the time of final examination even though incomplete recovery was noted for the three cases which returned for implant removal before the second operation.

In our patients, surgical treatment has offered good final outcomes. Arthroscopic evaluation has proved extremely useful in articular exploration for associated lesions as well as reduction and internal fixation. However, extended approaches were needed for adequate stabilization, although this was at most at the mini-open level. Wire has offered good fixation but the screw offered less postoperative symptoms and did not require removal. All three methods were comfortably kept within the epiphyses and did not create concern regarding the open growth cartilage.

Key words: tibial spine, avulsion fracture, pediatric ACL

Clinical background

Avulsions of the tibial spine are functionally equivalent to ruptures of the anterior cruciate ligament (ACL) in adolescent athletes. It therefore presents to general orthopaedists as well as a wide variety of orthopedic subspecialty surgeons, including sports medicine and pediatrics. Restoration of normal knee kinematics is dependent on anatomic reduction and fixation of the avulsed fragment. Because this injury is typically sustained by the skeletally immature patient, epiphyseal fixation is ideal to avoid physeal injury, which can lead to angular limb deformity [1].

Lafrance et al [2] consider that although most fractures heal successfully, residual laxity usually persists because of prefracture anterior cruciate ligament midsubstance attenuation. This does not typically manifest in subjective instability, and reconstruction of the anterior cruciate ligament is rarely required.

Prince et al [3] found that ACL injuries in skeletally immature patients are seen more often in boys. In addition, tibial avulsion fractures and partial tears are more common in younger, less rigid skeletons that can absorb the forces of trauma. As children mature, complete ACL tears and associated injuries occur in frequencies approaching those patterns seen in adults.

Sometimes when close reduction of the fragment is attempted this is obtained incompletely due to soft tissue interposition. Kocher et al [4] found that 65% of type III fractures and 26% of type II fractures had entrapment of the anterior horn of the meniscus, most commonly medial. This has been confirmed by other authors as well, particularly in type III fractures. This is why most authors such as Accousti et al [5,6] consider the treatment algorithm for tibial eminence fracture management with regard to displaced and irreducible fractures to require arthroscopic or open treatment, based on surgeon preference. Objective sagittal plane laxity does not translate into long-term clinical or subjective instability. However, every effort should be made to obtain the best possible reduction with stable fixation, when needed, to maximize function.

Given these premises we aimed to evaluate the current treatment of displaced tibial spine fractures in the skeletally immature in our clinic.

Material and Method

The classification system of Meyers and McKeever is the current standard used to classify these fractures and to guide treatment. It is based on the degree of displacement, mainly on the lateral x-ray. Zaricznyj modified this classification to include a fourth type - comminuted fractures of the tibial spine, which applies mostly to adults:

[1]I-st Clinic of Orthopedics and Trauma, 'Victor Babes' University of Medicine and Pharmacy Timisoara
[2]Clinical Emergency Plastic Sugery and Burns Hospital Bucharest
[3]University of Medicine and Pharmacy 'Vasile Goldis' Arad
E-mail: vermesan@gmail.com, raduprejbeanu@gmail.com, horia.haragus@yahoo.com, simover1@yahoo.com, drdamiangratian@yahoo.com

- type 1: minimal displacement of the tibial spine fragment
- type 2: displacement of the anterior third to half of the avulsed fragment, which is lifted upward but remains hinged on its posterior border
- type 3: complete separation of the avulsed fragment from the proximal tibial epiphysis, usually associated with upward displacement and rotation

We performed a retrospective review of displaced avulsions of the tibial spine in skeletally immature patients treated in our clinic over the last 6 years and identified 4 cases (fig.1 and 2): 3 girls and one boy, with a mean age of 12 (11-14). One case was type II and three were type III. All were treated operatively: 2 with arthroscopic / mini-open reduction and internal fixation using wire (fig.3 – 6), one with screw and one with 2 K wires.

Fig.1 and 2: AP and lateral x-ray views of a 12 years old girl with a type III tibial spine avulsion.

Fig.3 and 4: AP and lateral X-rays after arthroscopic reduction and internal fixation.

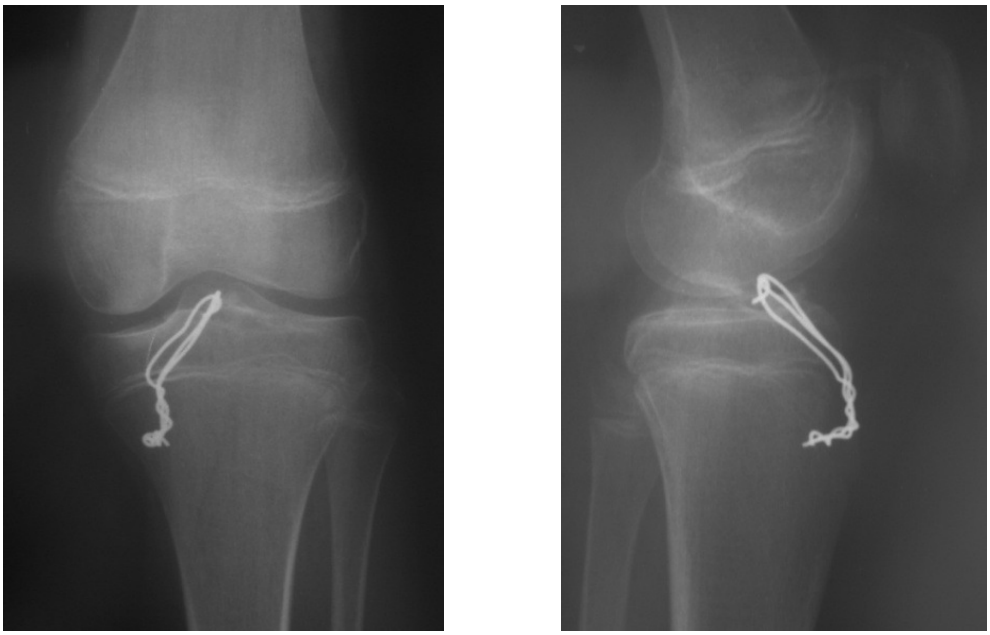

Fig. 5 and 6: the same case at 6 months (final) follow-up.

Results

The patients had the final follow-up evaluation at a mean of 20 months after index surgery. All had IKDC (international knee documentation committee) scores for excellent (A) and good (B) outcomes. Three out of four cases had increased manual antero-posterior tibial translation (2mm comparative bilateral as measured by KT-1000) without subjective feeling of instability. All patients had regained full ROM (range of motion) by the time of final examination even though incomplete recovery was noted for the three cases which returned for implant removal before the second operation. Both wires and the 2 K wires have been removed at an average of 6 months postoperatively. All cases have been diagnosed using standard X-rays; one case also had MRI examination. One case had an intraoperative finding of entrapped medial meniscus. Two cases were operated by a slight extension of the anteromedial arthroscopic portal and a third small incision (the cases with wire internal fixation) and two by small medial arthrotomy. All cases were followed by 3 weeks of immobilization in 15 degrees of flexion. None had associated meniscal or chondral lesions identified intraoperatively. One case had a ruptured medial collateral ligament on the MRI.

Discussions

Song et al [7] reviewed their cohort of patients with displaced tibial spine avulsions and identified eight cases of type II and ten of type III in children and two cases of type II, fifteen of type III, and five of type IV in adults. A higher incidence of type IV fractures was encountered in the adult group. Adults had higher incidences of accompanied meniscal injuries and type IV fractures than children. Significant differences were found in mean Lysholm scores, 99.3 points in children and 89.5 in adults. However, no significant differences were found between adults and children in terms of range of motion, the Lachman test and the Pivot-shift test, and instrumented anterior laxity. Lysholm scores of ACL avulsion fractures were better in children than in adults. Possible causes of these results are higher incidences of accompanying meniscal injury and type IV fracture in adults. However, no intergroup differences were found in terms of stabilities.

Arthroscopic treatment is advocated by the majority of authors as the best current option [8,9]. This allows for a complete evaluation and treatment of associated lesions, optimal reduction with removal of any possible soft tissue entrapment, accurate estimate of the size of the fragment (the chondral part is not visualized on x-rays and thus the fragment is usually undersized) and adequate internal fixation using suture, wire or screws. Reynders et al [10] presented a series of 26 cases of displaced fractures of the intercondylar eminence of the tibia treated with an arthroscopically placed, intrafocal screw with washer. Sixteen patients had a type II tibial eminence fracture according to Meyers and McKeever (mean age, 15 years; male/female ratio, 11:5). And ten patients had a type III tibia eminence fracture (mean age, 17 years; male/female ratio, 1:1). They encountered neither stiffness nor iatrogenic chondral abrasion. All but three patients with type II had some degree of residual laxity, without apparent impact on the clinical result. In four patients with a type III lesion, a residual laxity without functional deficit was noticed. In two cases with a type III lesion, a reconstruction of the anterior

cruciate ligament was necessary 3 years after trauma. In four patients with a type III fracture, the fragment remained elevated, with minor impairment of the mobility (extension lag). No mechanical failure or infection was seen in this series. The authors found the intrafocal screw fixation for displaced fracture of the intercondylar eminence to be a reliable and safe technique, although complete restoration of the anteroposterior knee stability was seldom seen. Lubowitz et al [11] recommend arthroscopic reduction and internal fixation for all displaced (type III) fractures and believe this should also be considered for all cases of displaced type II fractures. Fractures without displacement after closed reduction require careful evaluation to rule out meniscal entrapment. Subjective results are found to be uniformly excellent, despite reports of objective anteroposterior laxity.

Early range-of-motion exercises are essential to prevent loss of extension. Repair using nonabsorbable suture fixation, when of adequate strength to allow early range-of-motion, has the advantages of eliminating the risks of comminution of the fracture fragment, posterior neurovascular injury, and need for hardware removal, compared with screws.

Kocher et al [12] reviewed their results in six patients at minimal 2-year follow-up. They found mean postoperative Lysholm and Tegner scores of 99.5 and 8.7, respectively. One patient had a grade A Lachman (normal) test, three had grade B (nearly normal), and two had grade C (abnormal). Instrumented knee laxity showed side-to-side differences of greater than 3 mm in four of six patients.

In contrast, Wilfinger et al [13] performed a retrospective clinical analysis in a single department and identified forty-three patients. Twenty-three were female and twenty male. The mean age at trauma was 11.5 years (6-16 years). Only 1 patient required a change of therapy and needed open reduction. Thirty-eight patients were available for follow-up at an interval of 1-7.5 years after trauma (mean 3.5 years). None of the patients reported pain, swelling, disability or giving-way, or was handicapped in their daily life. Of 26 magnetic resonance imaging examinations, we found a missing anterior cruciate ligament in 1 and a partial rupture in another patient. Based on these results, the authors recommend nonoperative management as the primary treatment for tibial spine fractures in children.

Rademakers et al [14] included 44 displaced tibial spine fractures in a study. The mean age at time of accident was 24 years (range 9-57 years). Out of these, sixteen patients had an open physis at the time of trauma. After a mean follow-up of 16 years (range 5-27 years), the median knee ROM was 130 degrees (range 115-140 degrees). As measured with an objective testing device, no statistically significant difference of anteroposterior stability between the injured and uninjured legs was found, with a mean difference of 1 mm (range -3.9 to 6.9 mm). The Lysholm score showed good to excellent results in 86% of the patients. The patients with open physis at the time of index surgery did not develop axial malalignment in the long term.

Conclusions

In our patients, surgical treatment has offered good final outcomes. Arthroscopic evaluation has proved extremely useful in articular exploration for associated lesions as well as reduction and internal fixation. However, extended approaches were needed for adequate stabilization, although this was at most at the mini-open level. Wire has offered good fixation but the screw provided less postoperative symptoms and did not require removal. All three methods were comfortably kept within the epiphyses and did not create concern regarding the open growth cartilage.

References

1. Fabricant PD, Osbahr DC, Green DW. Management of a rare complication after screw fixation of a pediatric tibial spine avulsion fracture: a case report with follow-up to skeletal maturity. J Orthop Trauma. 2011 Dec;25(12):e115-9.
2. Lafrance RM, Giordano B, Goldblatt J, Voloshin I, Maloney M. Pediatric tibial eminence fractures: evaluation and management. J Am Acad Orthop Surg. 2010 Jul;18(7):395-405.
3. Prince JS, Laor T, Bean JA. MRI of anterior cruciate ligament injuries and associated findings in the pediatric knee: changes with skeletal maturation. AJR Am J Roentgenol. 2005 Sep;185(3):756-62.
4. Kocher MS, Micheli LJ, Gerbino P, et al Tibial eminence fractures in children: Prevalence of meniscal entrapment. Am J Sports Med 31(3):404-407, 2003.
5. Accousti WK, Willis RB. Tibial eminence fractures. Orthop Clin North Am 2003;34:365375
6. Hudgens JL, Dahm DL Treatment of Anterior Cruciate Ligament Injury in Skeletally Immature Patients Intl Jour of Pediatrics, Volume 2012 doi:10.1155/2012/932702
7. Song EK, Seon JK, Park SJ, Yoon TR Clinical outcome of avulsion fracture of the anterior cruciate ligament between children and adults Journal of Pediatric Orthopaedics Part B, vol. 18, no. 6, pp. 335–338, 2009
8. Binnet MS, Gurkan I, Yilmaz C, et al. Arthroscopic fixation of intercondylar eminence fractures using a 4-portal technique. Arthroscopy 2001;17(5):450460.
9. Senekovic V, Veselko M. Anterograde arthroscopic fixation of avulsion fractures of the tibial eminence with a cannulated screw: five-year results. Arthroscopy. 2003 Jan;19(1):54-61.
10. Reynders P, Reynders K, Broos P. Pediatric and adolescent tibial eminence fractures: arthroscopic cannulated screw fixation. J Trauma. 2002 Jul;53(1):49-54.
11. Lubowitz JH, Elson WS, Guttmann D. Part II: arthroscopic treatment of tibial plateau fractures: intercondylar eminence avulsion fractures. Arthroscopy. 2005 Jan;21(1):86-92.

12. Kocher MS, Foreman ES, Micheli LJ Laxity and functional outcome after arthroscopic reduction and internal fixation of displaced tibial spine fractures in children Arthroscopy, vol. 19, no. 10, pp. 1085–1090, 2003.
13. Wilfinger C, Castellani C, Raith J, Pilhatsch A, Höllwarth ME, Weinberg AM. Nonoperative treatment of tibial spine fractures in children-38 patients with a minimum follow-up of 1 year. J Orthop Trauma. 2009 Aug;23(7):519-24.
14. Rademakers MV, Kerkhoffs GM, Kager J, et al Tibial spine fractures: a longterm follow-up study of open reduction and internal fixation. J Orthop Trauma 23:203–207, 2009

Correspondance to:
Horia Haragus,
I Bulbuca 10,
300376,
Timisoara,
România,
Telephone: 0747025064
E-mail: horia.haragus@yahoo.com

HISTOLOGICAL FETO-PLACENTAL INTERFACE CHANGES IN THE GESTATIONAL DIABETES MELLITUS

Rodica Ilie[1,2], C Ilie[2,3], Ileana Enatescu[2,3], M Craina[2,3], Alexandra Nyiredi[2], Rodica Heredea[1]

Abstract

Introduction. Gestational diabetes mellitus (GDM) is a complication associated with pregnancy defined as any degree of glucose intolerance that occurs- or is first discovered during pregnancy, with normal values signaled before, and usually after pregnancy. Material and Method. This study analyzed the cellular differences that might contribute to the injuries of the feto-placental interface of insulin-controlled GDM patients. An optical microscopic analysis was performed on 26 full term placentas, of which 15 were of gestational diabetes mellitus and 11 control group. The histological observation centered upon the: *trophoblast, villous stroma* and *fetal capillary*. The fetal average weight was 3840 g for the studied group vs. 2760 g for the control group. Results. Through optical microscopy were identified varying degrees of lesions consisting of: *villous edema, proliferation and villous fibrosis of the capillaries, large number of syncytial knots, important fibrinoid necrosis, moderate fibrin thrombi, hyperplasia of the syncytiotrophoblast, chorangiosis, slightly thickened of the basement membrane of the feto-maternal interface*. Conclusion. The increased angiogenesis of feto-placental vessels of the terminal villi – considered to be the cause of the placental abnormalities; and the increased risk of complications for e.g. miscarriage, stillbirth, macrosomia, and congenital anomalies may be prevented by a good control over the glycemic levels.

Key words: Gestational diabetes mellitus, angiogenesis, feto-maternal interface abnormalities, trophoblast, villous stroma, fetal capillary.

Introduction

In diabetes there is an altered balance of substances such as nutrients, hormones, leptin and other cytokines which have been well documented as contributors to the potential regulation of placental function in GDM (1). The study is centered upon the analysis of histopathological modifications in placentas originating from pregnancies associated with gestational diabetes mellitus, given the lack of information on the histological pathognomonic lesions of the feto–maternal interface abnormalities.

Material and method

The samples used in this study were collected in between January 2009 – December 2011 from the 26 placentas collected immediately after delivery at „Bega" Clinic of Obstetrics, Gynecology and Neonatology, Timisoara. 15 were from patients with gestational diabetes mellitus and 11 from the control group. The placental pathological examination was performed by the same pathologist, who was blinded to the clinical data. Placental tissue samples were dissected from the central part of the placental bed.

Specimens

Two samples were collected from the middle–sections, from both – maternal and fetal – sides of the placenta. They were fixed in 4% buffered formalin, for 24 – 48 hours. Then 2 types of histological stains were used – Hematoxylin–Eosin and Masson's Trichrome. The histological examination of the slides was performed with an AmScope optical microscope in order to observe mainly the feto–maternal interface changes. The placental histopathological analyses were performed on images obtained by a digital camera. From each slide, 7 fields were randomly selected.

Hematoxylin–Eosin technique

- fixation in a 10% formalin solution
- dehydration in ethanol gradated series
- sedimentation in xylene
- sections
- paraffining
- deparaffining
- hydration and coloring with hematoxylene–eosine

Masson's Trichrome technique

- deparaffinize and hydrate to distilled water
- slides in 40 ml of Bouin's solution contained in a plastic coplin jar and microwave
  mix solution with beral pipet
- incubate slides in heated Bouin's solution for 15 minutes in a fume hood
- wash slides in tap water until sections are clear
- stain in working Weigert's hematoxylin 5 minutes
- wash slides thoroughly in tap water

[1]"Louis Turcanu" Emergency Children Hospital, Pathology, Timisoara
[2]„Victor Babes" University of Medicine and Pharmacy, Timisoara
[3]„Bega" Clinic of Obstetrics, Gynecology and Neonatology, Timisoara
E-mail: rodicailie2005@yahoo.com, constantinilie@umft.ro, mariuscraina@hotmail.com, lena_urda@yahoo.com, alexnyiredi@gmail.com, heredearodica@yahoo.com

- 0.5% Hydrochloric acid alcohol for 5 seconds
- wash in running tap water for 30 seconds and rinse in two changes of distilled water
- stain in Trichrome solution for 15 minutes and wash slides in tap water
- rinse in 0.5% Acetic acid 10 seconds and in distilled water
- dehydrate through graded alcohols
- mount with resinous mounting media

Results

The differences between the histological changes of the placentas from the control group (of normal pregnancies) and those from the group of gestational diabetes pregnancies can be seen in Table 1.

Table 1 - Histological changes of the placentas.

Histopathological changes	Normal Pregnancy = 11		GD Pregnancy = 15	
	Number	%	Number	%
Inflammatory				
Villitis	**0**	**0**	**0**	**0**
Amnionitis	**0**	**0**	**1**	**0,11**
Degenerative				
Villous fibrosis and edema	**0**	**0**	**1**	**0,11**
Fibrinoid necrosis	**1**	**0,11**	**3**	**27,27**
Trophoblastic basic membrane thickening	**0**	**0**	**4**	**36,36**
Hyaline degeneration	**2**	**18,18**	**3**	**27,27**
Calcification	**2**	**18,18**	**4**	**36,36**
Proliferative				
Syncytial knots	**1**	**0,11**	**3**	**27,27**
Hofbauer hyperplasia	**0**	**0**	**2**	**18,18**
Peri- and intervillous fibrosis	**0**	**0**	**4**	**36,36**
Chorioangiosis	**1**	**0,11**	**1**	**0,11**
Circulatory				
Chorial and intimal edema	**0**	**0**	**0**	**0**
Interstitial hemorrhage	**1**	**0,11**	**3**	**27,27**
Nucleated red cells	**0**	**0**	**4**	**36,36**

After a general optical microscopic examination there were found varying degrees of lesions to the feto-maternal interface, trophoblast, villous stroma and fetal capillary such as:

- capillary proliferation and interstitial hemorrhage – Figure 1
- villous capillaries fibrosis – Figure 2
- syncytiotrophoblast hyperplasia – Figure 3
- trophoblastic basic membrane thickening of the feto-maternal interface – Figure 4
- peri– and intervillous fibrosis – Figure 5
- a large number of syncytial knots and Hofbauer cells hyperplasia – Figure 6
- fibrinoid necrosis – Figure 7
- nucleated red cells – Figure 8

We consider that the cause of fetal hypoxia in diabetic pregnancy remains still unknown, however the lesions at these levels are connected to the abnormalities in the structure of capillaries and the perivascular space may be an essential factor in the explanation of fetal hypoxia in diabetic pregnant women. The relationship between the vascular surface of the terminal villi to its total surface, evaluation of the endothelial structure, perivascular space and basal membrane of the trophoblast could show us the injuries constituted to the fetal–maternal interface, leaving this research area opened for further studies.

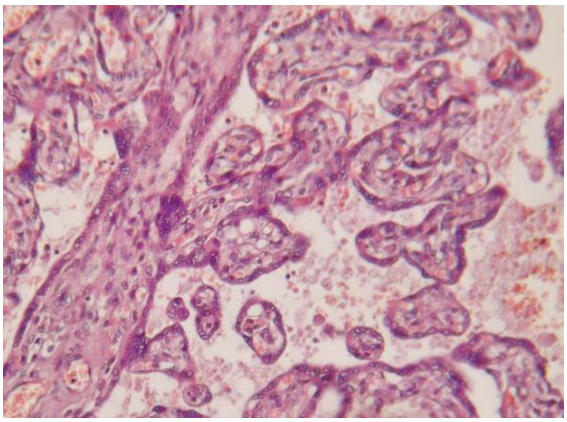

Figure 1 – capillary proliferation and interstitial hemorrhage (H.E. x 100).

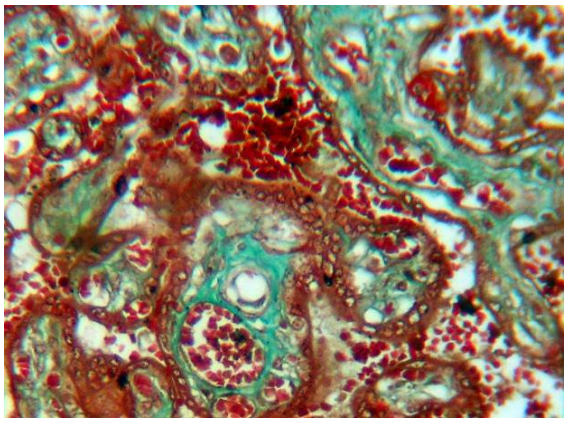

Figure 2 – villous capillary fibrosis (Masson's Trichrome x 200).

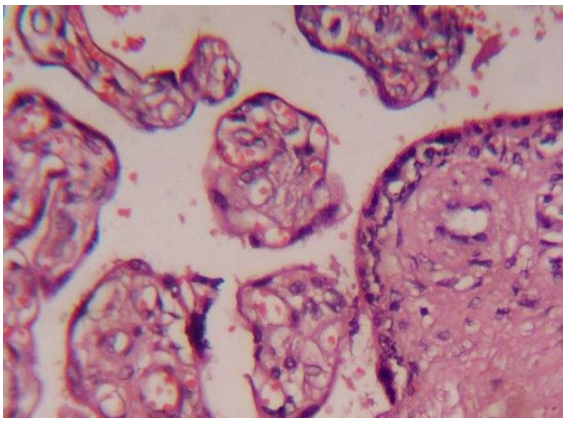

Figure 3 – syncytiotrophoblast hyperplasia (H.E. x 200).

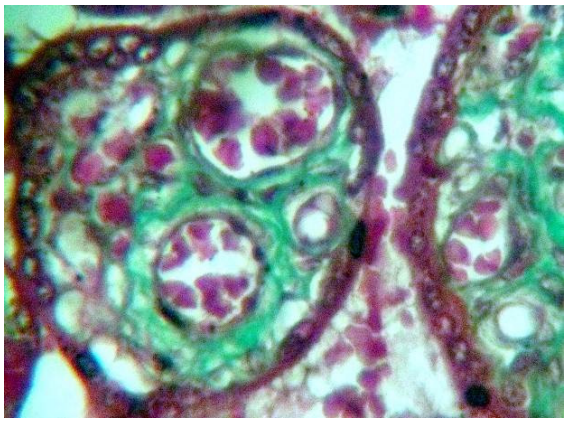

Figure 4 – trophoblastic membrane thickening of the feto-maternal interface (Masson's Trichrome x 400).

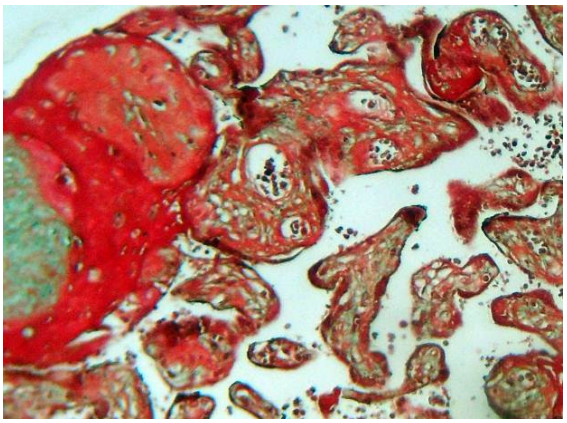

Figure 5 – peri - and intervillous fibrosis (H.E. x 100).

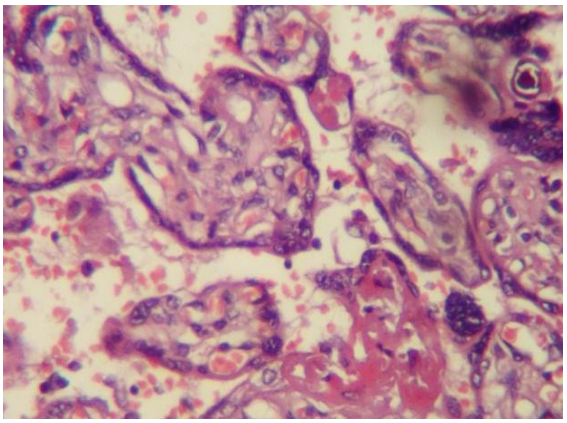

Figure 6 – a large number of syncytial knots and Hofbauer cells hyperplasia (H.E. x 200).

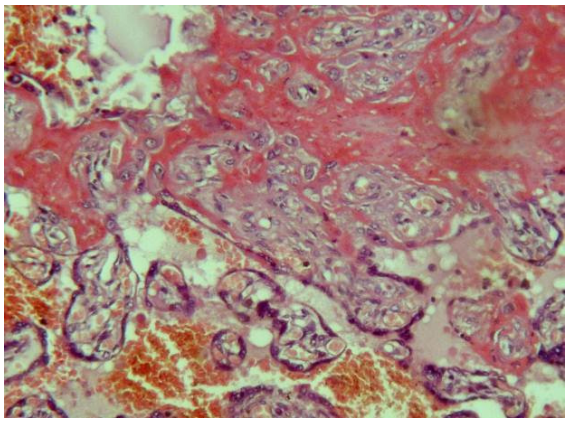

Figure 7 – fibrinoid necrosis (H.E. x 40).

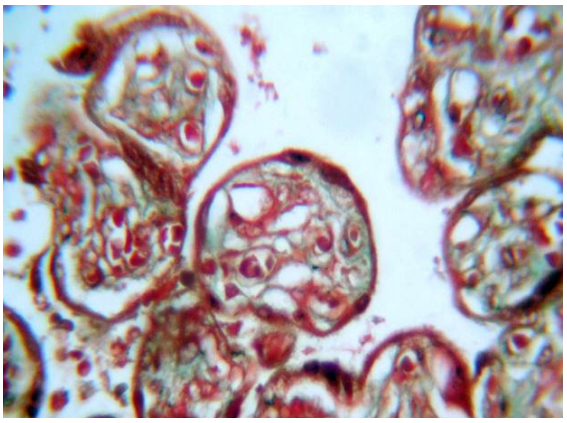

Figure 8 – nucleated red cells (Masson's Trichrome x 200).

Discussions

Optic microscopy analysis revealed various degrees of injuries consisting of numerous syncytial nuclei in the placentas of GDM, chromatin clumping, a feature of senescence, and most of them were arranged in clusters known as syncytial knots. In diabetics' placentas 25% of the villous surface is taken up by the capillary, while in normal placenta about 50% of the villous surface is taken up by the capillary bed (2). Diabetic milieu causes vascular dysfunction, increasing angiogenesis. Maternal (and fetal) hyperglycemia may impact on placental vascular permeability. The rise in blood glucose has several effects on the surrounding vasculature (3) demonstrated by the proliferation of small fetal vessels, partial or total obstruction of the vascular lumen was also seen in the vessels of the villous trunk having hemodynamic consequences (4). Fibrinoid necrosis, villous edema and villous fibrosis were observed, these being a result of hyperglycemia, as it acts as a pro-constrictor, pro-coagulator, pro-inflammatory, pro-angiogenic and pro-permeability agent (4); fibrinoid necrosis, peri– and inter-villous fibrosis, villous edema, crowding of villi and trophoblastic basement membrane were present being a real consequence of the metabolic disturbances which leads to accumulation of carbohydrate and fat in the placenta (5). These abnormalities in the fetal microcirculation are due to the microvascular changes associated with fibrinoid necrosis and villous immaturity and can also affect oxygen exchange leading to chronic fetal hypoxia (6).

Conclusions

Histological changes in the placentas of pregnant women with gestational diabetes – disarrangements distention and proliferation of the cells of the fetal–maternal interface, or perivascular space and cells, thickening and separation of membranes of trophoblast and capillaries – are significant factors contributing to fetal anoxia with impact on placental vascular permeability. We were able to demonstrate that the diabetic milieu causes vascular dysfunction, increasing angiogenesis in pregnancy complicated with gestational diabetes mellitus. No significant relations were shown between various injuries of the fetal-maternal interface and neonatal condition, in diabetic pregnant women with fetal eutrophy.

The studies performed during the last few years brought increasing evidence to the theory that in addition to sugars, other metabolic fuels, from ketones to deranged lipid peroxidation, may be responsible for the pathomechanisms of congenital malformations. Metabolic fuels may play a crucial role and besides the classical theories about the strict glucose control, manipulations or replacements for deficient substracts, free oxygen radical scavengers and antioxidants, might become a huge promise for the near future (7).

References

1. Desoye G, Hauguel-De Mouzon S, *The Human Placenta in Gestational Diabetes Mellitus*, Diabetes Care, 2007 july; 30 (suppl 2) : 120-126.
2. Verma R, Mishra S, Kaul J. M, *Ultrastructural changes in the placental membrane in pregnancies associated with diabetes.* Int. J. Morphol., 29(4):1398-1407, 2011.
3. Leach L, Taylor A, Sciota F, *Vascular dysfunction in the diabetic placenta-causes and consequences*. Journal: J Anat. 2009 July; 215 (1) : 69–76.
4. Kingdom J, Huppertz B, Seaward G, Kaufmann P. *Development of the placental villous tree and its consequences for fetal growth.* Eur J Obstet Gynecol Reprod Biol. 2000; 92 (1):35–43.

5. Vineeta Tewari, Ajoy Tewari, Nikha Bhardwaj, *Histological and histochemical changes in placenta of diabetic pregnant females and its comparision with normal placenta.* Asian Pacific Journal of Tropical Disease (2011)1-4.
6. Ian W Campbell, Catriona Duncan, Rennie Urquhart and Margaret Evans, *Placental dysfunction and stillbirth in gestational diabetes mellitus.* British Journal of Diabetes & Vascular Disease 2009 9: 38
7. Carrapato MR, Marcelino F, *The infant of the diabetic mother - The critical developmental windows.* Early Pregnancy. 2001 Jan;5(1):57-8.

Correspondance to:
Rodica Ilie,
RemusTasala Street, No.1, Sc. A, Ap. 14,
300345,
Timisoara,
Raomania
E-mail: rodicailie2005@yahoo.com

RESPIRATORY THERAPY IN A LOT OF NEWBORN WITH EXTREMELY LOW BIRTH WEIGHT

Aniko Manea[1*], Marioara Boia[1], C Ilie[1], Daniela Iacob[1], Mirabela Dima[1], RE Iacob[2]

Abstract

Introduction: Newborns with extreme prematurity are considered those who have a birth weight under 1000 grams. Morpho-functional plurivisceral immaturity leads to particular diseases, through frequency and gravity. The most common lung problem in a premature baby is respiratory distress syndrome. Another common respiratory problem of premature is apnea of prematurity.

Objectives: The authors aim to study the pathology and the treatment of respiratory pathology at a lot of premature newborns with extremely low birth weight.

Material and method: The study was carried out in the Premature and Neonatology Department during two years, on a group of 34 premature newborns with birth weight under 1000 grams (800 grams- 1000 grams).

Results: In the studied lot respiratory distress syndrome was present in 22 cases (64,7%), and 29 (85,2%) presented apnea episodes. In 17 cases these two were associated. From newborns with mild respiratory distress syndrome and apnea, 7 required only supplemental oxygen. In 11 cases with severe respiratory distress syndrome and repeated apnea crisis was necessary treatment with continuous positive airway pressure through nasal prongs for different periods of time. In 16 cases with severe respiratory distress syndrome and due to persistence of apnea and modification of blood gas parameters, was needed oro-tracheal intubations and mechanical ventilation.

Conclusions: Extreme prematurity is an important risk factor in increasing neonatal morbidity and mortality, premature with extremely low birth weight being the most exposed to all major complications of prematurity. Nasal continuous positive airway pressure is a useful method of respiratory support that reduces the incidence apnea, and in the treatment of respiratory distress syndrome and in reducing the necessity of the initiation of mechanical ventilation.

Key words: Extreme prematurity, respiratory support

Introduction

An extremely low birth weight (ELBW) infant is defined as one with a birth weight of less than 1000g.

Plurivisceral morpho-functional immaturity causes some particular diseases through frequency and severity: respiratory distress syndrome, peri- and intraventricular hemorrhage, apnea crisis, patent ductus arteriosus, enterocolitic ulceronecrotis and infections). The complications of prematurity can be classified as follows:

- Early pathology: idiopathic respiratory distress syndrome, recurrent apnea, intra and periventricular hemorrhage, lung hemorrhage, jaundice, infections
- Late sechele: at eyes (retinopathy of prematurity-retrolental fibroplasia, myopia, strabismus), auditive (hypoacusis, deafness), neurological (cerebral paralysis, diplegie, choreoathetosis, epilepsy), intellectual (IQ lower than 70), psychic (behavior disturbances).

The most common lung problem in a premature baby is respiratory distress syndrome.

Respiratory distress syndrome an early complication of extreme prematurity is respiratory distress syndrome (RDS) caused by surfactant deficiency.

By the old statistics respiratory distress syndrome affects 5% of the 1st degree premature, 20% of the 2nd degree premature, 50% of the 3rd degree premature, 70% of the 4th degree premature, and only 0,5% of the term newborn. Related to the gestational age the incidence of the disease is: 20% when gestational age is 34-32 weeks and 40% when gestational age is 32-30 weeks.

The frequency of respiratory distress syndrome related to gestational age and antenatal steroids therapy:

Gestational age	Antenatal steroid therapy	
	without	Yes
<30 weeks	60%	35%
30-34 weeks	25%	10%
>34 weeks	5%	-

Physiologically the volume of surfactant is insufficient to prevent collapse of the alveoli. Normal functional residual capacity is not established because of the collapse alveoli; therefore, oxygenation and ventilation are not sufficient, and each breath requires increased energy output.

The lungs in RDS have low compliance. Little change in volume is achieved with a relatively great amount of pressure, which contributes to increased work of breathing.

[1]Dept. of Neonatology – University of Medicine and Pharmacy Timisoara, Romania
[2]County Emergency Hospital Arad – Department of Pediatric Surgery, Arad, Romania
[*]**Research supported by PhD fellowship POSDRU107/1.5/S/ID 78702**
E-mail: aniko180798@yahoo.com, marianaboia@yahoo.com, constantinilie@umft.ro, danielariacob@yahoo.com, dima_mirabela@yahoo.com, radueiacob@yahoo.com

However, the chest wall is very compliant. A slight amount of pressure results in a large change in volume. The neonate may not be able to create enough inspiratory pressure to open the alveoli as the chest wall retracts and collapses in about the relatively stiff lungs.

The diaphragm contracts, creating an inspiratory pressure that moves less volume into the lung than expected and simultaneously causes large sternal and intercostal retractions of the chest wall. The increased effort of these opposing forces usually results in hypoxemia and academia that cause constriction of the pulmonary vascular (arterial) musculature, severely limiting pulmonary capillary blood flow. (1, 2, 3)

The chest radiography helps establish the diagnosis of RDS. The distinctive radiographical pattern includes reduced lung volumes, reticulogranular pattern, air bronchograms, and lung opacification. Surfactant deficiency results in diffuse atelectasis, a reduction in lung volume, and decreased lung expansion. Atelectasis increases lung density resulting in visible air bronchograms. Ground glass appearance appears as areas of atelectatic respiratory alveoli adjacent to expanded respiratory units. (2,3)

The disease being characteristic to premature newborn, the treatment will consist of prevention the premature birth. The antenatal therapy with corticosteroids is indicated for women with risk of premature birth. The treatment will be individualized according to the severity of disease. The therapy aims to maintain, in reasonable limits, the PaO2 (45-70 mmHg) and the PaCO2 (34-45 mmHg).

Treatment for infants of RDS consists of oxygen supplementation and assisted ventilation with continuous distending pressure, conventional mechanical ventilation, high frequency ventilation, and CPAP. Mechanical ventilation is usually weaned as soon as possible because of ventilator associated lung injury and the toxic effects of oxygen. Therefore, use of CPAP after postextubation phase has been effective to prevent atelectasis and to reduce apnea episodes and the need of reintubation. (1, 2, 3 ,4)

Surfactant replacement therapy was implemented immediately. Administration of surfactant leads to a dramatic and rapid improvement in gas exchange decreases the need for high levels of supplemental oxygen and ventilatory support, leads to less barotraumas, and improves lung compliance and lung volumes. A vital importance in the treatment of RDS is the maintenance of thermoregulation because hypothermia increases oxygen consumption; thereby, further compromising neonates with RDS.

Apnea of Prematurity (AOP) is found in 50 to 80% of preterm infants at less than 30 weeks of gestation, and its incidence is even higher in extremely preterm infants .It is almost universal in infants who weigh <1000 g at birth (5). The literature defines clinically significant apnoea in infants as breathing pauses that last for >20 s or <20 s, but with bradycardia or oxygen desaturation (6). The methylxanthines amynophylline, theophylline and caffeine are commonly used for treatment and prophylaxis of apnoea in preterm infants, as they decrease the frequency of apnea and the need for mechanical ventilation during the first seven days of therapy (7). Prolonged apnea may lead to hypoxaemia and reflex bradycardia, and may increase the risk of ventricular hemorrhage, hydrocephalus and abnormal neurological development during the first year of life (6).

Different patterns of apnea can be observed on a neonate: obstructive, central, and mixed sleep apnea. Obstructive sleep apnea is a pause in alveolar ventilation due to obstruction of airflow within the upper airway. Extremely low birth weight infants are particularly prone to obstructive sleep apnea, especially in the supine position, because the pharynx collapses from negative pressure generated during inspiration due to the muscle weakness of the oropharynx. Central sleep apnea is a pause in alveolar ventilation due to a lack of diaphragmatic activity. There is no signal to breathe being transmitted from the CNS to the respiratory muscles due to the immaturity of brainstem control of central respiratory drive. Neonates also manifest an immature response to peripheral vagal stimulation. Recurrent episodes of apnea may affect neurodevelopmental outcome. As the neonate gets older, and the lungs and brain tissues mature, the breathing usually becomes more regular.(6,7)

Objectives

The authors aim to study the pathology and the treatment of respiratory pathology at a lot of premature newborns with extremely low birth weight.

Material and method

The study was carried out in the Premature and Neonatology Department during two years, on a group of 34 premature newborns with birth weight under 1000 grams (800 grams- 1000 grams) and gestational age< 28 week. All the premature newborn received surfactant after birth.

Results

The most common lung problem in a premature baby is respiratory distress syndrome. In the studied lot respiratory distress syndrome was present in 22 cases (64,7%), and 29 (85,2%) presented apnea episodes. In 17 cases these two were associated. (Fig.1)

From newborns with mild respiratory distress syndrome and apnea, 7 required only supplemental oxygen. (Picture. No. 1). In 11 cases with severe distress syndrome and repeated apnea crisis was necessary treatment with continuous positive airway pressure through nasal prongs for different periods of time. (Picture. No. 2). In 16 cases with severe respiratory distress syndrome and due to persistence of apnea and modification of blood gas parameters, was needed oro-tracheal intubations and mechanical ventilation also for different periods of time. (Picture. No. 3)(Fig. 2). There is to be mentioned that at those who needed only supplemental oxygen and treatment with continuous positive airway it was applied INSURE therapy for surfactant administration. At those with mechanical ventilation immediate extubation was not possible.

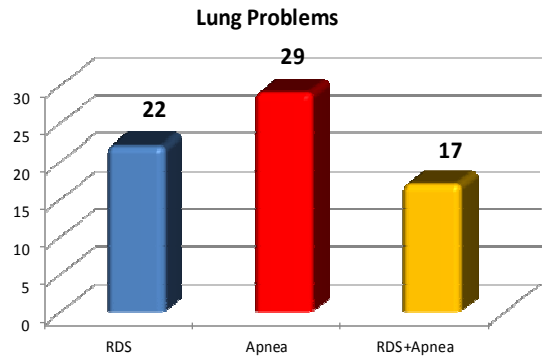

Fig. 1 Lung problems.

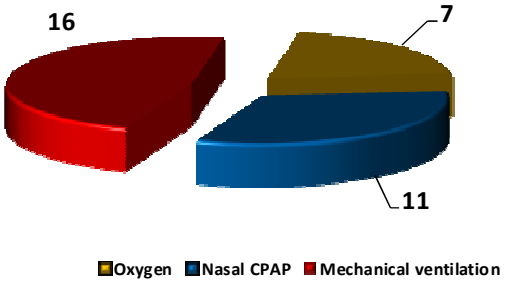

Fig. 2 Respiratory treatment.

Picture1. Oxygen administration to a premature newborn.

Picture 2. Treatment with continuous positive airway pressure through nasal prongs.

Picture 3 Premature newborn with intubation and mechanical ventilation.

Conclusions

Extreme prematurity is an important risk factor in increasing neonatal morbidity and mortality, premature with extremely low birth weight being the most exposed to all major complications of prematurity.

Nasal continuous positive airway pressure is a useful method of respiratory support that reduces the incidence apnea, and in the treatment of respiratory distress syndrome and in reducing the necessity of the initiation of mechanical ventilation.

References

1. Avery, G. & Fletcher, M.A. & Macdonald, M. (1999) Neonatology Pathophysiology and Management of the Newborn Philadelphia, Pa: Lippincott Williams & Wilkin Desktop Division
2. Stern, L (1984) Hyaline Membrane Disease Orlando, Fl: Grune & Stratton, Inc.
3. Lillian Alday, Annie Gin, Kristina Setrakyan, Respiratory Distress Syndrome, May 12, 2006, www.smccd.net/accounts/.../rpth485/rds.pdf
4. Whitaker,K. (2000) Comprehensive Perinatal and Pediatric Respiratory Care Albany, NY: Thomson Learning, Inc.
5. Finer NN, Higgins R, Kattwinkel J, Martin RJ (2006). Summary proceedings from the apnea of prematurity group. Pediatrics, 117:S47-S51.
6. McCallum AD, Duke T (2007). Evidence behind the WHO guidelines: Hospital care for children: Is caffeine useful in the prevention of apnea of prematurity? J. Trop. Pediatr., 53: 76-77.
7. Schmidt B (2005). Methylxanthine therapy for apnea of prematurity: Evaluation of treatment benefits and risks at age 5 years in the international caffeine for apnea of prematurity (CAP) trial. Biol. Neonate, 88: 208-213.

Correspondance to:
Aniko Manea,
University of Medicine and Pharmacy "V. Babes" Timisoara
P-ta E. Murgu, No. 2,
Timisoara,
Romania,
E-mail: aniko180798@yahoo.com

AN UNUSUAL COMPLETE DUPLICATION OF THE HINDGUT AND UROGENITAL TRACT: CASE REPORT AND LITERATURE REVIEW

Muazez Cevik[1]

Abstract

Complete duplication of the hindgut associated with duplication of the genitourinary tract and double termination is an extremely rare condition. The presence of complex duplications have fascinated most lay clinicians and parents. The present study describes a case of duplication of the hindgut associated with duplication of the genitourinary systems. A review of the literature revealed six reported patients with the same condition.

Key words: Complete duplication, hindgut, newborn, genitourinary tract

Introduction

Duplication commonly refers to the alimentary tract from the anus to the oropharynx. The earlist description of duplication may have been reported by Calder in 1733 [1]. Duplication may occur in the sagittal or coronal plane, and there is slight predominance for the male sex and the sagittal plane [1,2]. This anomaly is characterized by different presentations depending on the anatomy of the duplication.

A stillborn newborn with duplication of the bladder, urethra, vagina, uterus, and anus was first reported by Schatz in 1871 [2]. This condition was subsequently reported by Suppiger in 1876. Since that time, there have been few reports of this condition [3]. However, treatment remains a dilemma. Beach et al. reported that duplication of the hindgut and genitourinary can be separated because they are usually not fused and have a separate blood supply, and thus resection of one side of the duplication is possible [4]. When reconstructive surgery is not planned, the possibility of neoplastic changes in alimentary tract duplications should be kept in mind [5]. We herein report a case of total complete duplication of the colon, anus, vagina, vulva, urethra, and bladder in the coronal plane with no additional congenital anomalies. In our patient, both fecal and urinary functions were normal.

Case

A 10-day-old term female infant was admitted with fecal and urine material passing from two openings in the perineum (fig. 1a, 1b, 2). There were no additional congenital anomalies. The physical examination revealed a separeted double vagina, double vulva, double clitoris, double urethra, and two well-formed ani. One anus was in the right hip, and the other anus was in the left left hip. The two anal openings were widely separated with no communication between them.

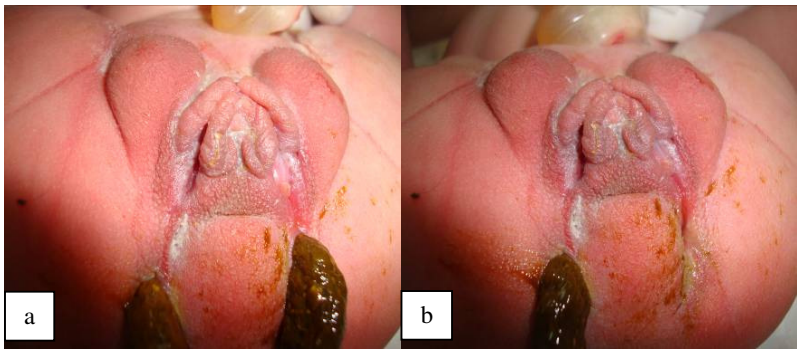

Figure 1a, 1b: The figures showing the duplication of extraurogenital strictures and ani.

Figure 2: The figures showing the extraurogenital strictures at 6 months old of the case.

[1]Harran University Faculty of Medicine, Department of Pediatric Surgery, Sanliurfa, Turkey
E-mail: cevikmuazzez@gmail.com

Due to the complexity of these abnormalities, the patient underwent plain X-ray, ultrasonography, contrast X-ray, magnetic resonance imaging, and videocysto-urethrography studies for investigation of these anatomical associations. Imaging of the upper digestive tract showed a normal esophagus and stomach. Contrast X-rays were obtained with installation of dye through the two anal openings, two urethral openings, and the upper digestive tract. Two colons were visible up to the cecum, two bladders were also visible, and the left bladder demonstrated reflux. The patient had no tailbone or pelvic anomalies. Ultrasonography revealed a horseshoe kidney at the pelvis. At the 6-month follow-up, the defecation and urinary functions of the child were normal.

Discussion

Complete duplication describes the presence of two of the same organ with separate walls of mucosal and muscular layers; each organ empties through its own tract. Complete duplication of the hindgut is rare and is usually associated with genitourinary tract duplications and neural tube defects [6,7]. In patients with this kind of complex abnormality, both openings are usually blind or inadequate [8]. The present patient had duplication of the hindgut and genitourunary systems, but both anal and urethral openings were adequate and functional. This anomaly has a widely variable anatomy and presents in different ways [6]. There is a female predominance [6]. The present patient was female; however, when we reviewed the literature, we found more male than female patients. In our review, we found seven similar cases of a duplicated hindgut and genitourinary tract (table 1). Most cases have been reported both of ani or one of ani had any type of anal atresia, and mostly included sacrum and vertebral column anomalies [8]. The present case showed normal function of both ani; however, both were malpostioned and without vertebral anomalies.

Table 1: Demographic and clinical characteristics of the present case with cases in the literature duplication of the hindgut and urogenital system

No	Cases	Age / Gender	Anomaly	Additional anomalies	Operation	Outcomes
1	Banu T et al.[7]	42-day/ Female	2 ani,2 vagina, 1vulva, 1 clitoris, 1 urethral orifice	Total colon duplication, vestibule fistula ani, polidaktili	No	Follow up for 17 months growing well
2	Azmy AF[8]	1-day/ male	2 penis, 2 ani,2urethra, 2 bladder, total colon duplication	Adbominal hernia, omphalocel, pes ecinovarus, horse-shoe kidney, vertebral column abnomaly, undescending testises, thoracic scoliosis	Neorecrum and anal canal, colon divided, bladders are jonied, testis was descended, and excision left phallus, urethras were corresponding	Follow up for 2 years, good stream urine, has regular bowel movement growing well
3	Okur Het al. [5]	1-day/ female	2 ani,2 vagina, 2 colon,1vulva, 1 clitoris, extrophy of the bladder	malrotation	no	Un clear
4	Smith ED[11]	Not clear	2 ani and 2 genitouriner tract	Not clear		
5	Cohen SJ[12]	1-day/ male	2 ani,2 fallus, 2 urethra 2 bladder, 2 colon	Anal atresia fistula with bladder	Staged procedure	Not clear
6	Liu et al. [13]	13 year/ male	İncomplet 2 phallus,2 colon 2 urethra,2 bladder, 2 ani	Hemicorpus vertebra fusion, accsessoir ear	Remeved colon, septum of bladder, and a fallus	Follow-up for2 years
7	The present case	10-day/fama le	2ani, 2colon, 2 urethra, 2 bladder, 2 clitoris, 2 vagen	Horse-shoe kidney	No	6 months follow-up

Most previous studies are case reports. Therefore, their descriptions were not sufficient to explain the etiopathogenesis of this complex anomaly. Several theories have been proposed regarding the etiology of this duplication. However, the embryologic basis of it is speculative and unknown. One hypothesis is that duplication of the hindgut and geniturinay structures is a result of partial or abortive splitting or twinning of embryonic structures during the early stages of development [9-11]. The separation may start with a divided notochord that fuses again cranial to the separation, beneath the paired notochord where the endoderm forms two hindguts, each of which gives rise to the allantoic stalk and a cloaca [8]. This explanation does not apply to the present case because no vertebral column abnormality was present. In patients with these associated abnormalities, one or both ends of the

urinary tract or intestine is usually either blind or has an inadequate opening. In the present case, all openings were adequate and at the coronal plane. Previous studies have shown a slight male predominance, and the sagittal variant appears to be more common than the coronal plane. However, the coronal is more common than the sagittal plane in females.

Duplications present in a variety of ways depending on their size, location, and associations. Most duplications have few or no symptoms and are therefore diagnosed incidentally or late in life. The present patient had a pair of extra urogenital structures and ani; therefore, she was diagnosed early in life.

Antenatal diagnosis of duplication has become common with the availability of prenatal ultrasonography [1].

Not only plain radiography, but also postnatal ultrasonography, contrast studies, computed tomography, and magnetic resonance imaging may help to localize the duplication.

Previous studies have identified malignant changes of the duplicated segment and removal of the segment was thus performed. The operative technique depends on the duplicated segment. The present patient was female, so the two anuses and urethras were not apparent. Therefore, her condition may not socially affect the patient later in life. In our case, both urethras and anuses were well functional. Poor postoperative activity of the rectal muscles was anticipated; therefore, surgical reconstruction was extended. In terms of operative timing, we suggest waiting until it is apparent which duplicated segment has impaired function. The possibilty of neoplastic changes must be kept in mind during follow-up. Banu et al. did not treat their patient, and no problems occurred during the 17-month follow-up. Another previous study described two female patients who were 22 and 25 years old, respectively. They had normal lives, and the 25-year-old gave live birth [7]. The other had a miscarriage and was subsequently diagnosed with this condition [6]. Therefore we suggest that may be best to accept the permancence of the two ani and urethras.

Three of seven patients who underwent surgery were male, and their operations were long and comprised many stages [8,12,13]. Therefore, the goal of treating this kind of complex anomaly is to relieve symptoms, not to restore normal anatomy.

In conclusion, the goal of treatment, case with many complete duplication should be monitored closely without surgery. Duplicate segments in which is insufficient according to plan surgical treatment.

References

1. Lund DP. Alimantry tract duplications. In: Grosfeld JL, O'Neill JA, Fonkalsrud EW, et al. Pediatric Surgery. 6th ed. Philadelpia: Mosby , Inc;2006;1389-1398
2. Coker AM, Allshouse MJ, Koyle MA. Complete duplication of bladder and urethra in a sagittal plane in a male infant:case report and literature review.J Pediatr Urol. 2008;4(4):255-9.
3. Suppiger J. Bildungs Fehler der weiblichen beckenorgane, correspondenz-blatt fur. Schweizer Aerzte. 1876;6:418.
4. Beach PD, Brascho DJ, Hein WR, et al: Duplication of the primitive hindgut of the human being. Surgery 1961;49:779.
5. Okur H, Keskin E, Zorludemir U, et al. Tubular duplication of the hindgut with genitourinary anomalies. J Pediatr Surg. 1992;27(9):1239-40.
6. Shah KR, Joshi A.Complete genitourinary and colonic duplication: a rare presentation in an adult patient. J Ultrasound Med. 2006 ;25(3):407-11.
7. Banu T, Chowdhury TK, Hoque M, et al. Congenital double anus with total colon duplication: a case report.J Pediatr Surg. 2007;42(1):1-2
8. Azmy AF. Complete duplication of the hindgut and lower urinary tract with diphallus. J Pediatr Surg. 1990;25(6):647-9.
9. Ravitch MM.Hind gut duplication; doubling of colon and genital urinary tracts.Ann Surg. 1953 ;137(5):588-601
10. Otiang'a-Owiti GE, Oduor-Okelo D, Kamau GK, et al.Morphology of a six-legged goat with duplication of the intestinal, lower urinary, and genital tracts. Anat Rec. 1997;247(3):432-8
11. Smith ED.Duplication of the anus and genitourinary tract. Surgery. 1969;66(5):909-21.
12. Cohen SJ.Diphallus with duplication of colon and bladder. Proc R Soc Med. 1968;61(3):305-6.
13. Liu H, Che X, Wang S, Chen G.Multiple-stage correction of caudal duplication syndrome: a case report. J Pediatr Surg. 2009;44(12):2410-3.

Correspondance to:

Muazez Cevik,
Harran University Faculty of Medicine,
Department of Pediatric Surgery,
TR-63300, Sanliurfa,
Turkey,
Phone: +905327456386
Fax: +90(414) 313 96 15
E-mail: cevikmuazzez@gmail.com

RECURRENT URINARY TRACT INFECTIONS IN CHILDREN WITH SECONDARY VESICOURETERAL REFLUX - STUDY OF 10 CASES

Anca Gabriela Bădescu[1], C Tica[1], Larisia Mihai[1], Mihaela Munteanu[2], C Chiriac-Babei[3], I Bâscă[3]

Abstract

Recurrent urinary tract infection (UTI) raises a question mark regarding the anatomy and functionality of urinary apparatus of the child. (1)

Recurrent UTIs are common in children with renal malformations. Proper treatment can prevent or at least slow down the destruction of the renal parenchyma of the child until the renal abnormalities are, if possible, resolved. (2)

We will try to present a study on a small group of children with recurrent UTIs and secondary VUR, which releases secondary reflux, due to bladder diseases.

Due to a study conducted over a period of 3 years, we found that bladder dysfunction of different causes may maintain VUR, and recurrent UTIs proper treatment helps maintain normal kidney function. Bladder dysfunction may be primary or secondary.

Conclusion: Secondary VUR maintain recurrent urinary tract, and their correct treatment slows down the kidney destruction.

Key words: recurrent UTIs, secondary VUR, child

Introduction

Urinary tract infections are one of the most common infections of the childhood. It is a child's grief, a concern for parents, and may cause permanent kidney damage.(1)

Primary vesicoureteral reflux represents an alteration idiopathic uretero-vesical with junction structure.(2)

Well known is also the association of vesicoureteral reflux with urinary tract infection and the occurrence of secondary nephropathy characterized by renal scarrs and secondary cortical atrophy, called reflux nephropathy. The natural evolution of VUR cases associated with UTI is a well known cause of chronic kidney failure. There are some contradictions known regarding vesicoureteral reflux therapeutic attitude between the pediatricians and surgeons pediatrics, coming not from the interpretation of literature data, but probably from the existence of a case law, very heterogeneous as a personal history.

Neurological dysfunction of the bladder (neurogenic bladder) is the result of congenital or acquired diseases affecting the bladder in nervation. The most common cause of neurogenic bladder in children is the myelomeningocele and spina bifida. Traumatic pathology can not be ignored but it is less relevant than in adults, due to occupational particularities. Another important pathology is the iatrogenic after pelvic interventions in the post operatory child.

The impossibility to ensure the storage function is explained either by hypertonicity of detrusor with bladder instability or bladder incompetence. Failure of emptying is caused either by sphincter hypertonicity or by the inability of detrusor contraction. These characteristics of neurogenic bladder can be objectified by urodynamic studies to guide therapeutic indication. Yet, in our country urodynamic studies can not be performed.

PUVs (Posterior Urethral Valves) occur exclusively in males (fig 1). The homolog to the male verumontanum from which the valves originate is the female hymen.(4)

PUVs are usually diagnosed before birth or at birth, when a boy is evaluated for antenatal hydronephrosis. Before the era of prenatal ultrasonography, PUVs were discovered during evaluation of urinary tract infection (UTI), voiding dysfunction, or renal failure.(3)

Vesicoureteral reflux is present in one half of male patients with a posterior urethral valve and is often thought to be physiologic, with high bladder pressures overcoming the competence of the ureterovesical junction. Reflux may also be anatomic, secondary to abnormal ureteral orifice position resulting from abnormal ureteral bud development during embryogenesis. (3)

Objectives

During this study we tried to follow certain cases in order to prove that everything is done to protect future adult kidney.

We tried to prove that medical management, and implicitly correct treatment of recurrent urinary tract infections, is the only correct treatment in these complex cases. Surgery is reserved only for cases with malformations of urinary system.

Material and method

The clinical-statistical study has been performed within The Pediatric Clinic of the Clinical Hospital „Sfânta Maria" Iaşi.

There were 10 children aged 6 months to 10 years old, with an equal incidence to the area of origin, but with a different provision towards the cause of releasing vesicoureteral reflux.

[1]County Emergency Hospital Constanța
[2]Children Hospital„Sfânta Maria" Iaşi
[3]Children Hospital „Grigore Alexandrescu" Bucharest
E-mail: badescuanca2000@yahoo.com, constantin.tica@yahoo.com, larisia_mihai@yahoo.com, mihaelamunteanu2001@gmail.com, cbcatalin@yahoo.com, ion.basca@gmail.com

Fig .1. Anteroposterior view of the abdomen during a voiding cystourethrographic study. This image demonstrates bilateral grade 4 vesicoureteral reflux. No intrarenal reflux is noted, at child with PUV. (3)

We folowed:

1. Epidemiology of secondary causes of VUR
2. Proper diagnosis of urinary tract infections
3. Monitoring of renal functions
4. Correct treatment of recurrent UTI episodes
5. Physical and psychological means to educate the future adult.

There were cases of posttraumatic neurogenic bladder, through myelomeningocel operated, or unstable bladder syndrome, and 2 cases of posterior urethra valve.

In all cases recurrent UTI led to the establishment of investigations on the association of vesicoureteral reflux, proving once again their association.

Cases were all monitored on a clinical, laboratory, biological and radiological data.(1)

Results

10 cases were studied over a period ranging from 1 to 4 years, from 2003 until 2007.

There were 8 girls and 2 boys, aged 6 months to 10 years old (table 1).

Area of origin was easily dominated by urban (table 2).

Secondary vesicoureteral reflux was facilitated by these diseases (table 3).

Table 1.

Age	0-1 years	1-3 years	4-7 years	More than 7 years
No of cases	3	2	4	1

Table 2.

Urban	**Rural**
6	4

Table 3.

Neuromuscular dysfunction	4
Neurogenic bladder incontinent type	1
Traumatic neurogenic bladder	1
Postoperative neurogenic bladder	2
Posterior urethral valve	2

Biochemistry analysis

Biochemical analyses showed 7 patients with an association of intrainfection anemia in 100% of cases, also the presence of inflammatory tests positive in 50% of cases (table 4).

Pyuria is present in urine tests from all 10 cases during the flare, and the flare-ups who periodically returned, (5)unable to establish favorable conditions (table 5).

Table 4.

No of cases	Normal	High	Low
Hemoglobin			10
No leukocytes		10	
No platelets	10		
Blood urea	10		
Blood Creatinine	10		
Calcium	10		
Blood sedimentation rate	4	6	
FIibrinogen	6	4	
C-reactive protein	6	4	
Total protein	4		

Table 5.

No of cases	Present	Absent
Pyuria	10	-

As an etiology, we found in all cases many types of germs, which shows heterogeneity causes of these infections, and the need to respect rigorous hygiene measures (table 6).

Table 6.

E coli + Enterobacter	1
E coli + candida	1
E coli + pseudomonas	1
Enterobacter + Klebsiella + group D streptococcus	1
E coli + pseudomonas + Klebsiella + Enterobacter	1
Enterobacter + candida + mixed flora	1
Proteus + Klebsiella + enterococcus + mixed flora	2

In all cases, antibiotic treatment was perforemd, according to antibiogram, initially intravenously for 1 to 3 days in order to improve the general condition, and then orally until 10 to 14 days, depending on the severity.(6)

Besides antibiotic treatment,a major role was played by other adjuvant methods (table 7).

Table 7.

Adjuvant methods	No of cases
Fluid consumption 1.5 l liquid / day	10
Correct clining of external genital organs	10
Control monthly urine culture	10
Urine culture if fever	10
Complete evacuation of the bladder and at regular intervals	10
Bladder catheterization	1
Driptane treatment	8
Anemia treatment	10
Combating constipation	10
kinetotherapy and physiotherapy	6

On the 2 children with posterior urethral valve, resection was performed on the posterior urethral valve, and was found a significant improvement in reflux, especially since they were monitored during 1 year (they did not come for the follow-up, for reasons we do not know), and they had no episodes of UTI.

In other cases both children were monitored, and there was no improvement in reflux, although adjuvant methods were used.

Discussions

Secondary vesicoureteral reflux is a serious disease, usually associated with other diseases that alter the general condition of the child, the future adult.

In this paper we tried to show that proper treatment of urinary infections allowed a normal renal function during the follow-up. Vesicoureteral reflux association aggravates long-term prognosis of children. Surgical treatment of two cases with posterior urethral valve, allowed a considerable

decrease of vesicoureteral reflux (from grade IV to grade II), and therefore it stopped urinary infections and the appearance of new renal scarrs and secondary reflux nephropathy.

We have noticed that under prolonged treatment with antibiotics for recurrence prevention of urinary infections it did not improve vesicoureteral reflux in other cases, the clinical conditions did not permit antireflux surgery on children.

In these circumstances, in order to establish a long-term prognosis of future adult, it has been tried a medical manangement. It has also been tried a proper treatment for all urinary infections and adjuvant methods correctly specified.

Conclusions

1. All cases had monitored secondary VUR and UTI.
2. Area of origin was easily dominated by urban, feminine sex were dominant in 80% of cases. Male was present in the 2 children with posterior urethra valve.
3. The etiology of urinary tract infections is multiple and still dominated by E coli.
4. Urinary tract infections treated appropriately according to antibiogram were protected during monitoring renal function, preventing reflux nephropathy in 9 of 10 cases.
5. Cases resolved surgically improved VUR, and UTI has not been revealed.
6. In these complex medical cases associated with vesicoureteral reflux, medical management is the only possibility for the time being.

References

1. Kanwal K Kher, H William Schnaper, Sudesh Paul Makker. *Clinical Pediatric Nephrology*. Ed. a 2-a, Informa Healthcare, Milton Park, 2007 p.713 -720
2. Bâscă Ion. *Refluxul vezico-ureteral la copil*. Editura Ştiinţifică, Bucureşti, 1998 p.87-90
3. Horowitz M, Harel M, Combs A, Glassberg K. *Surveillance cystoscopy in the management of posterior urethral valves*. J Urol. Apr 2009;181:172.
4. Tietjen Douglas N., GLOOR James M., Husmann Douglas A. *Proximal Urinary Diversion in the Management of Posterior Urethral Valves: Is it Necessary?* The Journal of Urology, Volume 158, Issue 3, September 1997, p. 1008-1010
5. Anderson JD, Chambers GK, Johnson HW. *Application of a leukocyte and nitrite urine test strip to the management of children with neurogenic bladder*. Diagn Microbiol Infect Dis. Jul 1993;17(1):29-33.
6. Merguerian PA, Sverrisson EF, Herz DB, McQuiston LT. *Urinary tract infections in children: recommendations for antibiotic prophylaxis and evaluation*. An evidence-based approach. Curr Urol Rep. Mar 2010;11(2):98-108.

Correspondance to:

Anca Gabriela Bădescu,
County Emergency Hospital Constanța,
B-rd Tomis no 145,
Constanța,
România,
Telephone: 0722238808
E-mail: badescuanca2000@yahoo.com

VASCULAR ANOMALIES IN CHILDREN – 17 YEARS EXPERIENCE

Maria-Corina Stănciulescu[1,2], Emanuela Verenca[1], ES Boia[1,2], CM Popoiu[1,2], VL David[1,2], Anca Popoiu[1,2], Patricia Cristodor[1]

Abstract

Objective: The aim of this study is to assess our results of the treatment in children with vascular anomalies.

Methods: We retrospectively reviewed the charts of 704 patients with 843 vascular anomalies treated in the Department of Pediatric Surgery between January 1996 and June 2012.

Results: Sex ratio was females/males 1.5:1, 69% were less than one year of age at the time of admission. The average time of hospital stay was 2 days. 83.5% of vascular anomalies were hemangiomas and 83,6 % of these affected the skin and subcutaneous tissue. 64% of hemangiomas were tuberous and most were located on the head and neck. 11% affected multiple sites and/or were associated with other vascular anomalies.

Conclusion: This audit allows us to improve the diagnosis, methods of treatment and improving our clinic's recording. Our results stress on the necessity for implementation of educational programs among the people living in the countryside, so that they would become aware of the importance of addressing the physician for their children's health concerns.

Key words: vascular anomalies, vascular tumors, vascular malformations, hemangiomas.

Introduction

In 1996, the International Society for the Study of Vascular Anomalies (ISSVA) accepted the classification of vascular anomalies into vascular tumors (the most common of which is infantile hemangioma) and vascular malformations, based on clinical, radiological and pathological characteristics [1,2]. The differentiation was founded on the idea that the suffix "oma" (as in "angioma") implies a tumor that proliferates, which does not apply to vascular malformation, as they are non-proliferative [3]. According to contemporary statistical data, vascular anomalies are on the rising, affecting on average 10% of all infants; also, they are believed to account for about 45% of the tumors of skin and soft tissues [4]. It is believed that hemangiomas are the result of excess angiogenesis while vascular malformations are caused by errors in vessel remodeling [5]. The most frequent localizations of vascular anomalies are the teguments from the cervico- facial area; however, they can affect any organ system, be it parenchymatous or cavitary [4].

Material and methods

This study includes 704 patients (1 day to 18 years of age) with 843 vascular anomalies, who were admitted and treated in our clinic during the January 1996 – June 2012 time frame (Fig. 1). Patient data was obtained from hospital admission records, clinical observation forms, surgical records, imagistic studies and histopathologic exams. Since 2008 electronic records were also used. The analysis employed looked at demographic and anamnestic data, therapeutic methods, clinical evolution, treatment results and complications.

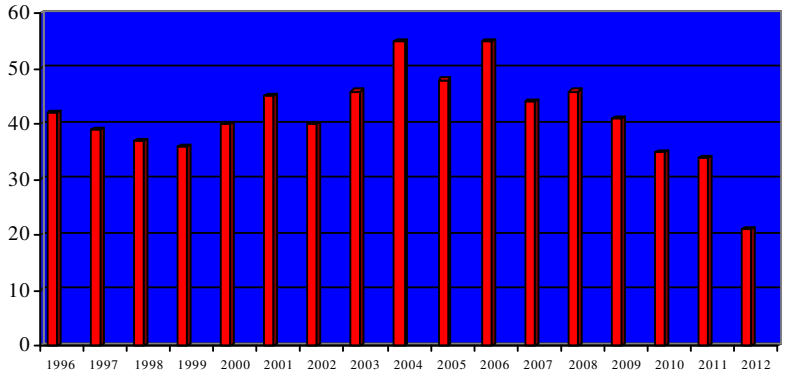

Fig. 1. Number of patients by year of admission.

[1]University of Medicine and Pharmacy "Victor Babeş" Timişoara, România
[2]Emergency Children's Hospital "Louis Ţurcanu" Timişoara, România
E-mail: stanciulescucorina@yahoo.com, emma_ver@yahoo.com, boiaeugen@yahoo.com, mcpopoiu@yahoo.com, david.vlad@yahoo.com, apopoiu2004@yahoo.com , patricia.cristodor@gmail.com

The Emergency Children's Hospital "Louis Ţurcanu" serves the Western part of Romania, specifically the Timiş, Caraş Severin, Hunedoara and Arad counties. However, patients in this study came from other parts of the country as well, especially the Mehedinţi, Gorj, Bihor, Botoşani, Suceava, Vaslui and Vrancea counties.

Results

Of the 704 patients included in the study, 427 are girls and 277 are boys, with an approximate female:male ratio of 1.5:1. 487 (69%) patients were less than one year of age at the time of admission. Table 1 and Figure 2 summarize patient distribution by age. The majority of patients (65%) came from the urban environment. 69% were less than one year of age at the time of admission. The number of days of admission varied between 1–28 days, with an average of 2 days. Only 6 patients stayed in the hospital for more than 15 days.

Table 1: Patient distribution by age.

Age	No. Patients
0-2 mo	44
2-6 mo	236
6-12 mo	207
1-3 yrs	137
3-7 yrs	28
>7 yrs	52

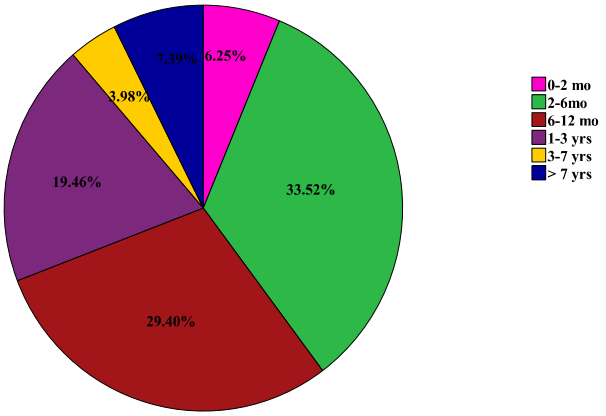

Fig. 2. Patient distribution by age.

The prevalence of vascular anomalies was as follows: hemangiomas (83.5%), lymphangiomas (4%) and "Others" (12.64%) (Fig.3). The "Others" category includes 89 patients with vascular malformations (mostly Klippel-Trenaunay Syndrome, Sturge-Weber Syndrome and peripheral arteriovenous malformations) but also vascular tumors (Kaposiform hemangioendothelioma, congenital hemangiomas and glomangiomas).

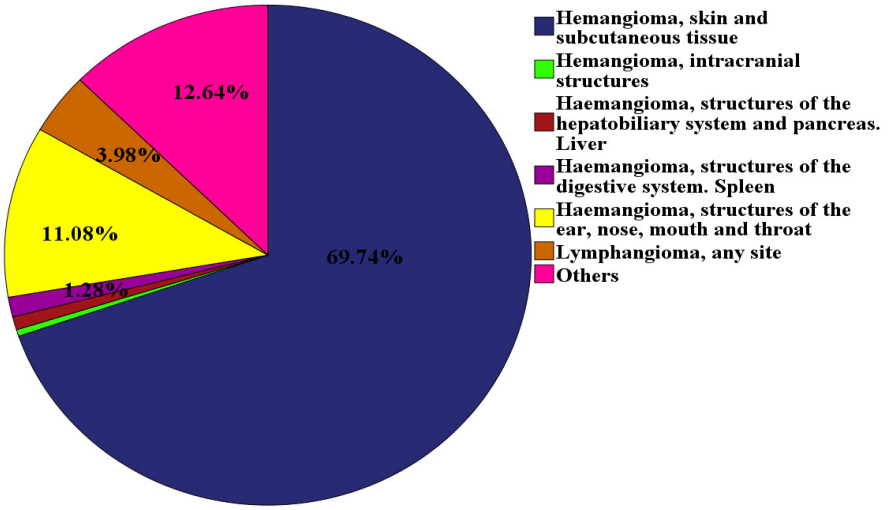

Fig. 3. Distribution of patients with vascular anomalies by diagnostic.

By far, the greatest percentage of hemangiomas affected the head and neck area (51%), followed by the trunk (15%). 11% of patients had multiple hemangiomas, with or without other associated vascular anomalies (capillary malformations in most cases) (Fig. 4). Female: male distribution of hemangiomas was in a ratio of 2:1.

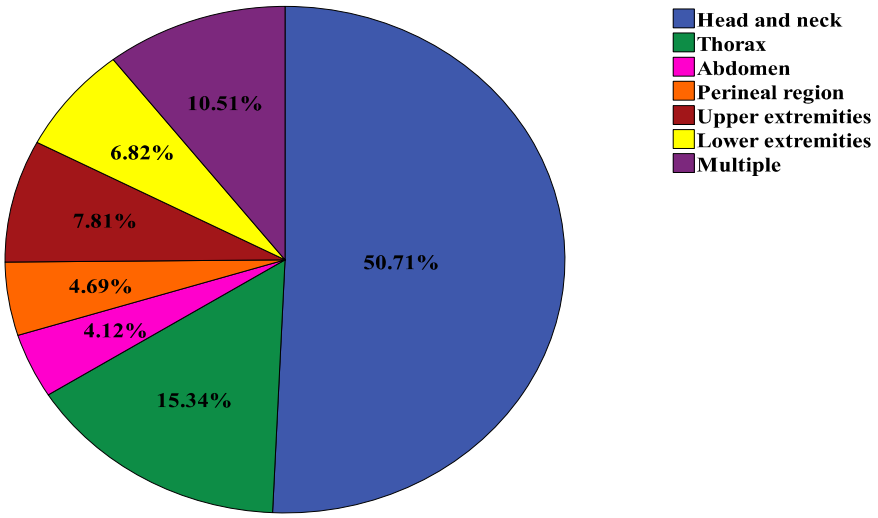

Fig. 4. Hemangioma distribution by anatomical location.

Of the 587 patients with hemangiomas, 376 (63.6%) were tuberous, 83 (14.2%) cavernous, 79 (13.6%) unspecified and 49 (8.4%) suffered complications such as bleeding, infections, and/or ulceration. Out of the 704 patients treated solely in our clinic, 88.15% required therapeutic intervention and in most cases, lesion excision was performed (Fig 5).

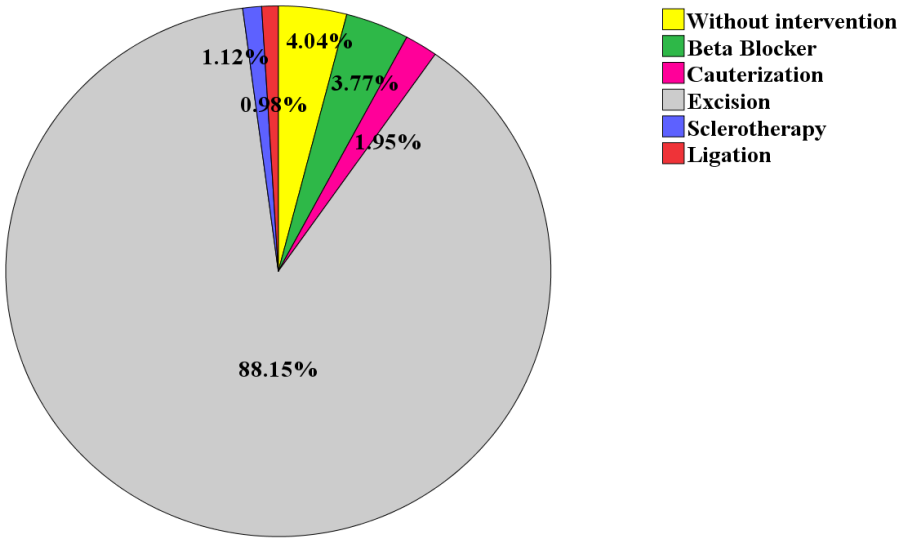

Fig. 5. Types of interventions employed.

In 4.4% of patients, especially those with giant hemangiomas, up to 5 surgical interventions were required for complete excision. In 11 cases of large-sized hemangiomas, reconstructive surgery with skin grafting was performed. In 8 cases of hemangiomas located in regions that made it difficult for surgical treatment to be performed, sclerosing agents were injected (Bleomycin or Aethoxysklerol), together with peri and intralesional ligation. A single lymphangioma case required intralesional injection with Picibanil (OK-432); the posttherapeutic result

in this case was very good. In May 2010, our clinic introduced treatment with beta blocker (propranolol) for patients with infantile hemangiomas; 3.77% of the patients with vascular anomalies have so far benefited from such treatment, with very good results.

Discussions

The separation of vascular anomalies into vascular tumors and vascular malformations has been of key importance in easing the ability of clinicians to diagnose and treat these entities [6]. Vascular tumors are believed to mostly arise sporadically, but an Autosomal Dominant (AD) mode of inheritance has been reported by Blei et al, the genetic defect affecting the 5q 31–33 chromosome [7]. Infantile hemangiomas usually appear within a few days after birth, exhibit an accelerated rate of growth during the infant's first year of life and then undergo regression by the age of 7 [8]. The incidence of infantile hemangiomas during the first 3 days of life ranges from 1.1% - 2.6% and it rises to 8.7% - 12.7% during the first month – one year interval [9]. In our study a number of 280 (47,7%) patients with infantile hemangiomas were diagnosed before six months of life; our results are consistent with literature data. Most hemangiomas (51%) affected the head and neck area; the thorax was involved in 15% of cases, with multiple areas being affected in 10.5% of cases like in Haggstrom observation.[10]

Vascular malformations are almost always present at birth and differ from hemangiomas based on clinical appearance, histopathologic features, and biologic behavior [11]. In rare cases, a patient can present both vascular tumors and vascular malformations. Literature has reported on the copresence of a hemangioma and a capillary malformation of the port-wine stain type at either the same site or in close proximity [6].

In other instances, however, if these two lesions are located at distant sites, their association is coincidental [6]. Due to insufficient reporting, we are unable to determine what percentage of our patients fit either one of the situations above; however, we know that 11% of had multiple hemangiomas, with or without other associated vascular anomalies (capillary malformations in most cases).

While literature presents a female:male ratio for infantile hemangiomas anywhere from 3-9:1, the ratio of patients in our clinic was lower (2:1). The reason for female predominance is unknown but it is believed to be linked to hormonal differences [12]. As most cases referred to our surgery clinic were of a more severe nature, the type of treatment most commonly employed for vascular anomalies was surgery, with very good results. Annual distribution of patients suggests the decreasing number of cases in our clinic, could be explained by increasingly administration of beta blocker. Though propranolol treatment was administered on a relatively small sample size (28 patients) its very good results in treating infantile hemangiomas make the drug a likely, less invasive choice in the future management of these lesions. That pattern of evolution is specific for a surgery department were almost all (88,15%) cases were surgically treated due to their complications-bleeding, infection and ulceration.

70% of our patients presented hemangioma on the skin of subcutaneous tissue, evidence not described by previous authors. Although the incidence of vascular malformations is known to be reduced in surgical wards, we find 89 cases having complexes syndromes, even if they are generally reported from medical departments.

According to the National Institute of Statistics, as of January 1, 2010, the urban/rural distribution of population in Romania was 55% and 45% respectively [13]. However, only 35% of the patient population came from the rural environment. As the rate of vascular anomalies is uniform throughout the population, the significant discrepancy in the patients from the urban versus rural environment is suggestive of the fact that people living in the countryside are less willing to address the physician in matters of their children's health. We would like to therefore emphasize the importance of implementation of educational programs, such that awareness is increased on the significance of health checkups in growing children.

While initially mostly presenting an aesthetic problem, vascular anomalies can lead to problems such as: ulceration, hemorrhage, functional impairment, visual/auditory obstruction, and respiratory/cardiac insufficiency or Kasabach-Merritt syndrome.

Conclusions

It is essential for the clinician to differentiate between vascular tumors and vascular malformations, in order to implement a better management. The lower percentage of patients from the rural environment is suggestive of the fact that parents from the countryside are not as likely to bring their children to the doctor as parents living in urban areas. Hence, increased awareness on the importance of regular checkups is needed. Given the excellent results that propranolol has brought in treating hemangiomas, we feel confident to make increasing use of this form of treatment. If medical treatment fails, patients will benefit from surgical procedures.

References

1. Enjolras O. Classification and management of the various superficial vascular anomalies: hemangiomas and vascular malformations. J Dermatol. 1997 Nov; 24(11):701-10.
2. Enjolras O. Les angiomes de l'enfant a un tournant dans leur comprehension et dans leur prise en charge. Arch Pediatr 1999; (6): 1261-1265.
3. Mulliken JB, Glowacki J. Hemangiomas and vascular malformations in infants and children: a classification based on endothelial characteristics. Plast Reconstr Surg 1982; (69): 412-22.
4. Gudumac E, Malai A, Hîncu G, Cojuşneanu N. Managementul anomaliilor vasculare la copii. Scientific Annals. 2006; (7): 3-6.

5. Enjolras O, Wassef M, Chpot R. Introduction: ISSVA Classification. In: Color Atlas of Vascular Tumors and Vascular Malformations. Cambridge University Press 2007:3-11.
6. Garzon MC, Enjolras O, Frieden IJ. "Vascular tumors and vascular malformations: evidence for an association." J Am Acad Dermatol. 2000 Feb;42(2 Pt 1):275-9.
7. Blei F, Walter J, Orlow SJ, Marchuk DA. Familial segregation of hemangiomas and vascular malformations as an autosomal dominant trait. Arch Dermatol 1998; (134):718-722.
8. Mulliken JB, Enjolras O. Congenital hemangiomas and infantile hemangioma: missing links J Am Acad Dermatol. 2004 Jun;50(6):875-82.
9. Sundine MJ, Wirth GA. Hemangiomas: an overview. Clin Pediatr (Phila). 2007 Apr;46(3):206-21.
10. Haggstrom AN, Lammer EJ, Schneider RA, Marcucio R, Frieden IJPatterns of infantile hemangiomas: new clues to hemangioma pathogenesis and embryonic facial development. Pediatrics. 2006 Mar;117(3):698-703.
11. Enjolras O, Chapot R, Merland JJ. "Vascular anomalies and the growth of limbs: a review" J Pediatr Orthop B. 2004 Nov;13(6):349-57.
12. Enjolras O, Mulliken JB. The current management of vascular birthmarks. Pediatr Dermatol. 1993;10:311-333.
13. Institutul Naţional de Statistică. Populaţia României pe localităţi. Bucureşti 2010 ISSN 2066-2181.

Correspondance to:
Maria-Corina Stănciulescu
Str. Dr. Iosif Nemoianu No.2
Timisoara,
Romania,
E-mail: stanciulescucorina@yahoo.com

LIVER NODULAR LESIONS IN THE CHILDREN – BASIC IMAGISTIC APPROACH

SB Motoi[1], Simona Cerbu[2], F Birsasteanu[1]

Abstract

For the diagnostic of the nodular hepatic diseases the methods are including: ultrasound, computed tomography, magnetic resonance imaging and angiography.

Ultrasound can identify the structure cystic or solid nature, and also the calcification from the tumor.

Computed tomography is helpful in examining children because the time of investigation is short and it is giving the segmental anatomy.

Magnetic resonance imaging is "the gold standard" for the pathology of the liver; it has a good contrast of soft tissue and has no ionizing radiation. Magnetic resonance imaging using organ–specific contrast agents can appreciate the type of the cellularity from the tumor and in children is preferred over invasive procedures.

These two imaging modalities are preferred technique because it is important to establish the segmental anatomy and the vascular structures for the resecability of the lesion.

Key words: liver nodules, benign, malign, magnetic resonance imaging

Introduction

Two-thirds of the liver tumors in children are malignant. The prevalence of the benign hepatic tumors in children is much lower than in adults [1]. We appreciate that MRI investigation is the better modality for evaluation of the focal liver lesions.

The aim for scanning times is 20 to 35 minutes for abdomen and pelvis in pediatric population. Based on their level of cooperativeness the children are classified into three age groups: infants (under 1,5 years), small children (1-6 years) and older children (6-18 years); the MRI examination is specific for each group op children [2]

Imaging of infants is better at 3,0 T than 1,5 T. It is important to use fat suppression to improve image quality and soft tissue contrast resolution [3]

Small children are more alert and more anxious so they will require small sedation.

Older children have ability to cooperate with hold breath instruction.

Classification of the liver neoplasm in relation to age: [4]

Under five years of age	Over five years of age
Hepatoblastoma	Hepatocellular carcinoma
Infantile hemangioendothelioma	Undifferentiated embryonal sarcoma
Mesenchymal hamartoma	Fibrolamellar carcinoma
Metastases from neuroblastoma, Willm's tumor	Metastases
Angiosarcoma	Adenoma

Infantil hemangioendothelioma

It represents the most common benign liver tumor in children [5]

It is discovered within the first six months of life, males are less affected than females.

The tumor may be presented as solitary or multiples nodules affected both lobe and may have sharp or ill-defined margins. The multinodular type involve the skin and also other organs [6]

The lesion is typically heterogeneous low signal T1-weighted images with intralesional hemorrhages, high signal on T2-weighted images. After contrast administration (gadolinium) the lesion show peripheral enhancement in early arterial phase and also persistent central enhancement in late phase. In interstitial phase the nodules enhance homogeneously – fig 1. [7,8]

[1]University of Medicine and Pharmacy "Victor Babeş" Timişoara, România
[2]Emergency Children's Hospital "Louis Ţurcanu" Timişoara, România
E-mail: sorin.motoi@o2it.ro, cerbusimona@yahoo.com, fbirsasteanu@yahoo.com

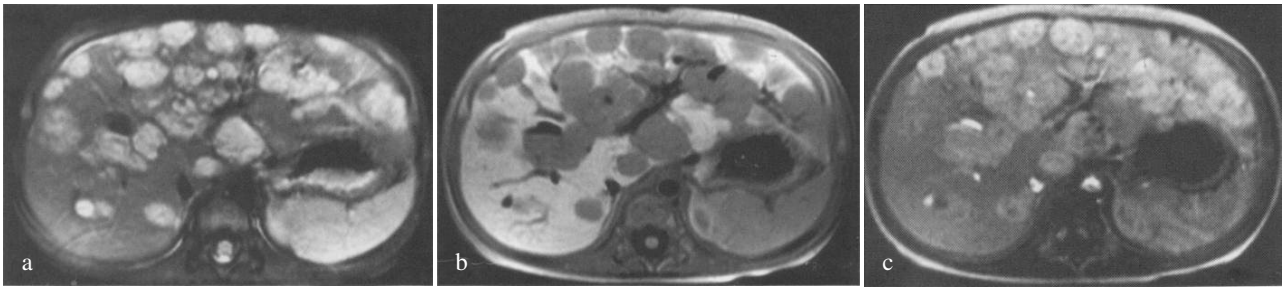

Fig. 1 - Infantile hemagioendothelioma - 18 month old boy: a) T2-weighted fat-suppressed shows multiple nodular lesions, small size, under 1cm, appear in hight signal intensity; b) the lesion in T1- weighted before contrast; c) T1-weighted fat-suppressed on the interstitial-phase, after homogeneously gadolinium enhanced.

Hepatoblastoma

Is the most common hepatic tumor in children; can appear from the newborn to adolescent prior but rarely older.

The tumor is detected by 3 years old, and boys are more affected than girls 3:2.

The tumor is solid and may present calcifications and necrosis, multiple septa and fibrous bands; it is well defined by a pseudocapsule [9]

The tumor can be seen in older children, over 5 years, and the clinical and imagistics aspects mimic HCC, with vascular invasion and recurrence, and the prognostic is worse.

Sometimes the hepatoblastom is multifocal, involved the organs: lung, kidney, brain and abdominal lymph nodes [10]

In 50% of children the hepatoblastoma is an incidental finding, only 25% presents abdominal pain, fever, weight loss; only 10% presents fewer with jaundice [11]

AFP is positive also in hepatoblastoma and in HCC, but has higher values than in adult with HCC [12]

In hepatoblastoma can observe high values of human chorionic gonadotropin associated with early puberty. Thrombocytosis can appear in 93% [9]

CT has a fundamental role to determinate the extension of the tumor but also the metastases from lung and lymph nodes [9]

After contrast administration, we observe early enhancement, heterogeneously, hyperintense in the fibrotic areas and with rapid wash out in the portal phase; in the delayed interstitial phase after gadolinium, the lesion became heterogeneously hypo- or isointense [11] – fig 2. [13]

Differential diagnosis on CT and MRI imaging can be done with: hemangioendothelioma, neuroblastoma metastasis, mesenchymal hamartoma, hapatocellular carcinoma.

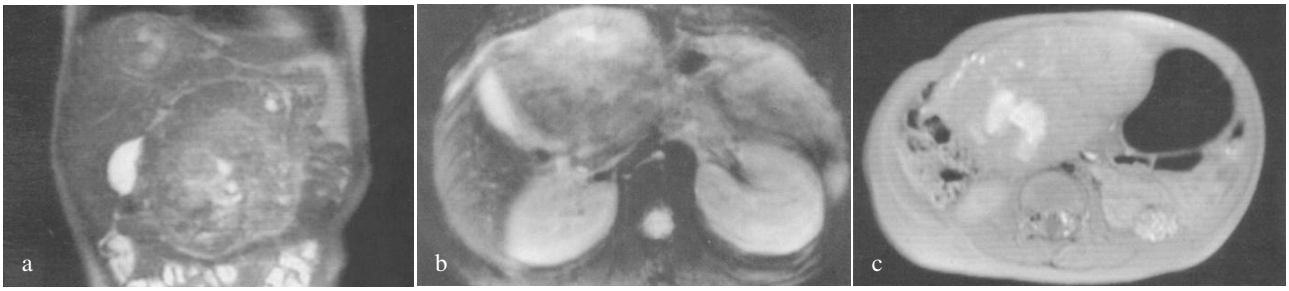

Fig. 2 - Hepatoblastoma - 1 year old boy: a) coronal T2-weighted image which demonstrates a large hepatic mass, with heterogeneous signal; b) transverse T2-weighted fat-suppressed image show a high signal in the center of the mass consistent with hemorrhage; c) T1-weighted immediate postgadolinium show diffuse enhancement.

Mesenchymal hamartoma

It is a benign developmental cystic liver tumor; appears under 2 years old, males are more affected than females. Sometimes these abnormalities develop before birth. It can be a prenatal diagnosis on ultrasound and in MRI imaging [14]

Ultrasonographic features show multiple cysts with internal septations, well defined, with variable sized from few mm to cm. The cystic mass measuring 15 cm, is well defined, has no calcifications and after contrast administration on CT or MRI, septa and solid components enhance – fig 3. [15]

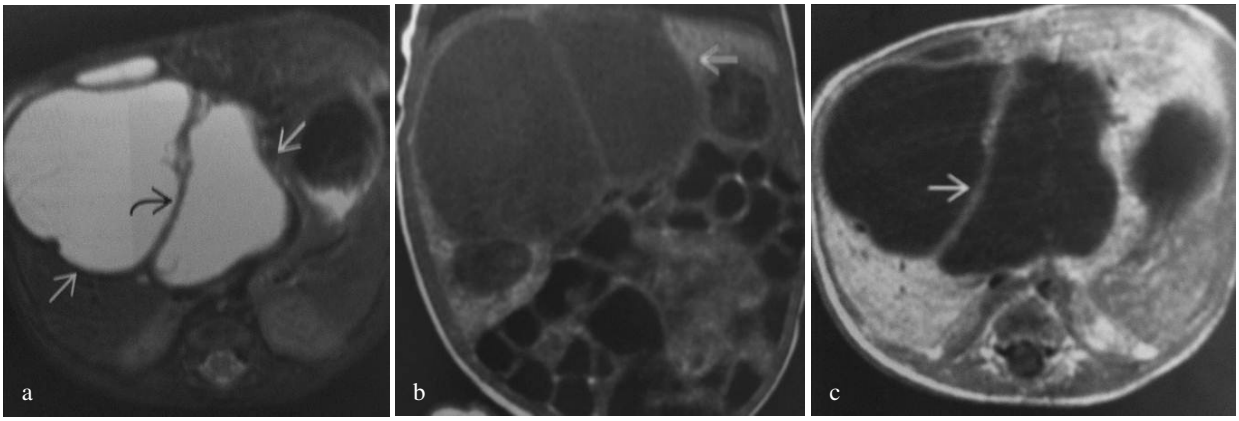

Fig. 3 - Mesenchymal hamartoma – 2 weeks old boy, diagnosticated on a prenatal ultrasound: a) on axial T2-weighted image shows a multicystic septated mass; b) the hepatic mass in a coronal T1-weighted image before contrast; c) axial T1 weighted-image after gadolinium enhance show the enhance of the thickened septation.

Hepatocellular carcinoma

After hepatoblastoma, HCC represent the second most common malignant tumor of infancy. It has two peak periods, between four and five years and between 12 and 14 years of age [16]

It is well documented in childhood; most cases are associated with metabolic disease (tyrosinemia) and infection with HVB [17]

Macroscopically there are three different growth pattern of HCC [9,18, 19]

Type one is a massive solitary non-encapsulated mass;

Type two multifocal can simulate metastases, formed by several nodules, sometimes with confluences.

Type three is the diffuse form, it is rare and it involves the whole liver.

The best method to detect the HCC nodules is MRI and the dynamic contrast give a lot of patterns to describe the lesion. Pseudocapsula if exist has to be differentiated by granulation tissue. Dysplastic nodules, smaller than 3 cm may enhance homogeneously, but tumors over 4 cm have a heterogeneously enhancement and may present necrosis and fibrous tissue. HCC have a specific pattern of enhancement after contrast administration, it has a strong enhance in the early in arterial phase and has a rapid "wash-out" on venous phase.

Some studies demonstrate that the role of CT in detection of the dysplastic nodules in the cyrotic liver is lower than MRI because the bloody supplies of the normal liver parenchyma is similar to that dysplastic nodules – fig 4 [20, 21].

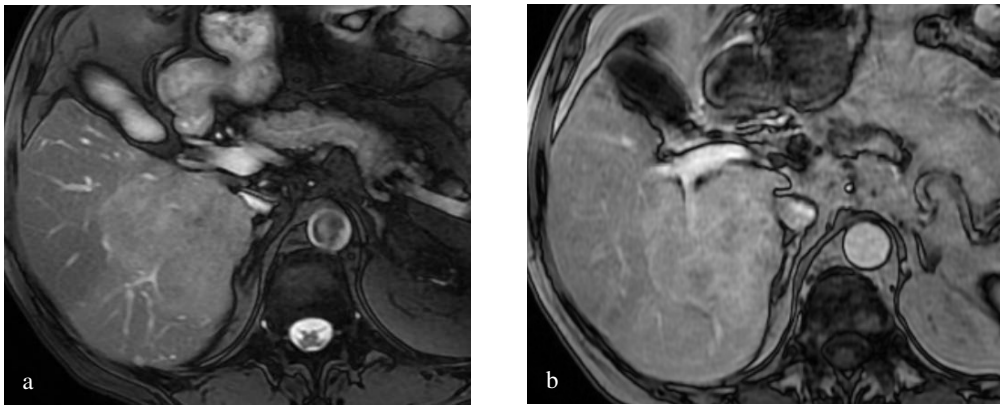

Fig 4- Hepatocellular carcinoma – 17 years old boy with HVB: a) T2 axial image – nodular HCC with portal invasion; b) inhomogenous enhancement after gadolinium.

Fibrolamellar carcinoma

It is a slow growing tumor and appears in adolescents

Appears in non-cyrotic liver with normal AFP levels.

The tumor vary from 5-20 cm, has calcifications and necrosis; it is well define, has central scar and radial septa. On the early phase after contrast media, the enhancement is diffuse; the scar and the septa enhance on delayed phased.

Differential diagnosis can be done with: focal nodular hyperplasia, conventional hepatocellular carcinoma. [29]

Undifferentiated embryonal sarcoma

It affected children between six and ten years [22] and also the adults [23]. Males and females are equal affected [24].

It is presented like a large mass, can reach 20 cm, well defined, often pseudoincapsulated and may contain cystic, hemorrhagic or necrotic areas; tumors with cystic components are more frequent than the solid and they have a rapid growth [25]; usually is symptomatic [26] and the levels of AFP from serum is normal [27].

On MRI the tumors appear like degeneration cystic, with hemorrhagic and necrotic areas; the septations and the pseudocapsule is in hypo signal on T1 and T2 and after contrast enhancement the stromal components and the septations are enhanced – fig 5. [11,28]

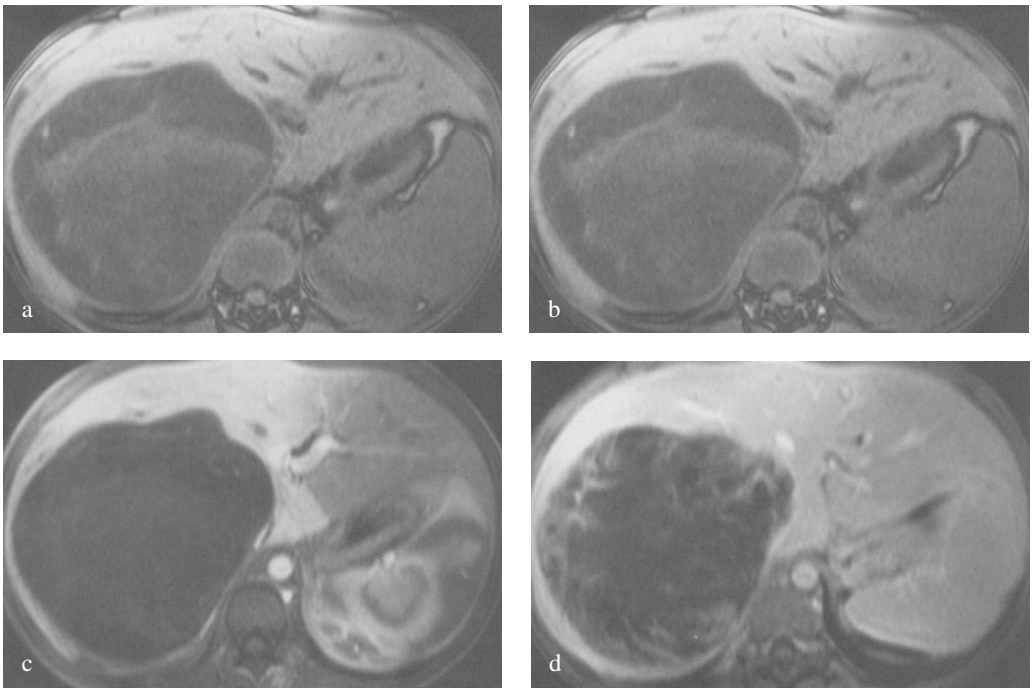

Fig 5 [13] – Undifferentiated embryonal sarcoma: a) coronal T2-weighted fat-sat suppressed show a large mass in high signal; b) axial T1-weighted without contrast; c) T1 wighted images after contrast images show in early phase a negligible enhancement; d) late-phase - moderate enhancement of the outer margins of the mass.

Conclusions

MR imaging is a fundamental tool for diagnostic in pediatric patients; et has a high accuracy and also an important role to determine the full extent of the hepatic lesions and also to evaluate the resecability in the preoperative stages.

MRI is preferred technique because has a better soft tissue contrast and for the lack of the ionizing radiation in comparison with computed tomography.

References

1. Ernst J. Rummeny, Peter Reimer, Walter Heindel - MR Imaging of the Body, New York, 217, 2009
2. Richard C. Semelka, M.D. – Abdominal-Pelvic MRI:1645-1646; (3rd ed), volume 2, 2010
3. Ramalho M, Altun E, Heredia V, Zapparoli M, Semelka R., Liver MR imaging: 1,5 T versus 3 T. Magn Reson Imaging Clin N Am 15(3):321-345, 2007
4. Gunther Schneiderr, Luigi Grazioli, Sanjai Saini. MRI of the Liver, 2nd , 10:1, 336, Italy, 2006

5. Siegel MJ.MR imaging of pediatric abdominal neoplasms. Magn Reson Inaging Clin N Am 8:838-850, 2000
6. Kew MC. Hepatic tumors and cysts. In: Feldman M,Scharschmidt BF , Sleisenger MH : Sleisehger and Fordtran's Gastrointestinal and Liver desease (6th ed.). WB Saunders, 1364-1387, Philadephia 1998
7. Carneiro RC, Fordham LA, Semelka RC. MR Imaging of the pediatric liver. Magn Reson Imaging Clin N Am 10(1):140-160, 2002
8. Richard C. Semelka, M.D. – Abdominal-Pelvic MRI:1645-1646; (3rd ed), volume 1, 2010
9. Helmberg TK, Ros PR, Mergo PJ et al. Pediatric liver neoplasms: a radiologic –pathologic correlation.9:1340-1345; Eur Radiol 1999;
10. King SJ, Babyn PS , Greenberg ML, et al. Value of CT in determining the resecability of hepatoblastoma before and after chemotherapy. Am J Roentgenol 160:793-798; 1993
11. Siegel MJ. Pediatric liver imaging. Seminars in liver disease 21:250-270, 2001
12. Tsuchida Y, Ikeda H, Suzuki N, et al. A case of well-differentiated , fetal-type hepatoblastoma with very low serum alpha-fetoprotiein. J Ped Surg 34:1762-1764, 1999.
13. 13.Richard C. Semelka, M.D. – Abdominal-Pelvic MRI: (3rd ed), volume 1, 253-256, 2010
14. Laberge J-M Patenaude Y, Desilets V , Cartier L., Kalife S, Jutras L, Chen M-F. Large hepatic mesenchymal hamartoma leading to mid-trimester fetal demise. Fetal Diagn Tber 20: 141-145, 2005
15. Lane F. Donnelly, Blaise V. Jones, Sara M O'Hara , Christopher G. Anton, Corning Benton, Sjirk J.Westra et al. Diagnostic Imaging Pediatrics 1st ed, 4:91, 2005
16. Pobiel RS, Bisset III GS. Pictorial essay: imaging of liver tumors in the infant and child. Pediatr Radiol 25:495-506,1995
17. Kew MC. Hepatic tumors and cyst. In:Feldman M, Scharschmidt BF, Sleisenger MH: Sleisenger and Fordtran's Gastrointestinal and Liver Desease 6th ed WB Saunders, Philadelphia, 1364-1387, 1998
18. Fujita T, Honjo K, Ito K, et al. High resolution dynamic MR imaging of hepatocellular carcinoma with a phased –array body coil. Radiographics 17:127-130, 1997
19. Miller FH, Butler RS, Hoff FL, et al. Using triphasic helical CT to detect focal hepatic lesions in patiens with neoplasms. Am J Roentgenol 171:643-650, 1998
20. Hayashi M, Matsui O, Ueda K, et al. Correlation between blody supply and grade of malignancy of hepatocellular nodules associated with liver cirrhosis; evaluation by CT during intraarterial injection of contrast medium. AJR Am J Roentgenol 172:970-976, 1999
21. Lim JH, Cho JM, Kim EY, et al. Dysplastic nodules in liver cirrhosis:evaluation of hemodynamics with CT during arterial portography and CT hepatic arteriography 214:870-874,;Radiology 2000
22. Davey MS, Cohen MD. Imaging of gastrointestinal malignancy in childhood.34:717-742, Radiol Clin North Am 1996
23. Buetow PC, Buck JL, Pantongrag- Brown L, et al. Undifferentiated (embryonal) sarcoma of the liver: pathologic basis of imaging findings in 28 cases; 203:779-783. Radiology 1997.
24. Kirks DR, Griscom NT. Hepatobiliary tumors. Practical Pediatric Imaging. Diagnostic Radiology of Infants and Children.; 954-969.Lippincot-Raven 1998
25. Moon WK, Kim WS, Kim IO, et al. Undifferentiated embryonal sarcoma of the liver: US and CT findings; 24:500-503. Pediatr Radiol 1994
26. Donnely LF, Bisset GS. Pediatric Hepatic Imaging; 36:413-427. Radiol Clin N Am 1998
27. Craig JR. Mesenchymal tumors of the liver. Diagnostic problems for the surgical pathologist; 3:141-160, Pathology 1994
28. Yoon Y, Kim JKK, Kang KH. Hepatic undiffentiated embryonal sarcoma:MR findings; 21:100-102, J Comput Assist tomogr 1997
29. Federle, Jeffrey, Woodward, Borhani. Diagnostic Imaging Abdomen III 1:150-155, 2nd ed, 2010

Correspondance to:

Simona Cerbu,
Str. Dr. Iosif Nemoianu, Nr. 2
300011
Timisoara
Romania
Phone: 0749276265
E-mail: cerbusimona@yahoo.com

MANUSCRIPT REQUIREMENTS

The manuscript must be in English, typed single space, one column on A4 paper, with margins: top – 3 cm, bottom – 2,26 cm, left – 1,5 cm, right – 1,7cm. A 10-point font Times New Roman is required.

The article should be organized in the following format: Title, Names of all authors (first name initial, surname), Names of institutions in which work was done (use the Arabic numerals, superscript), Abstract, Keywords, Text (Introduction, Purpose, Materials and Methods, Results, Discussions and/or Conclusions), References, and first author's correspondence address.

For details please visit www.jurnalulpediatrului.ro

ERRATUM

Erratum to JURNALUL PEDIATRULUI – Year XIV, Vol. XIV, supplement 2, 2011

- Pp 2, line 13, Chapter Contents, Article No. 5, Title: *"The importance of early diagnosis in the spleen ruptures. Case presentation."* Authors: Horatiu Gocan, Adrian Surd, Rodica Muresan must be replaced with: *„Congenital duodenal stenosis due to Ladd peritoneal bands. Case presentation"*
- Pp 23, line 1, Title: *"The importance of early diagnosis in the spleen ruptures.Case presentation."* must be replaced with *„Congenital duodenal stenosis due to Ladd peritoneal bands. Case presentation"*

Erratum to JURNALUL PEDIATRULUI – Year XIV, Vol. XIV, Nr. 55-56, july-december 2011

- Pp 35, line 4, Authors: *Rodica Ilie[1], Constantin Ilie[2], Ileana Enătescu[2], Elena Bernad[2], Corina Daniela Frandes[3], Rosemarie Herbeck[1]* must be replaced with: *Rodica Ilie[1,2], Constantin Ilie[2,3], Ileana Enătescu[2,3], Elena Bernad[2,3], Corina Daniela Frandes[4], Rosemarie Herbeck[1]*
- Pp 35, lines 43-45, Authors' affiliations: *[1]Emergency Children's Hospital „Louis Ţurcanu" Timisoara; [2]„Bega" Clinic of Obstetrics and Gynecology, Timisoara; [3]West "Vasile Goldiş" University of Arad*, must be replaced with: *[1]Emergency Children's Hospital „Louis Ţurcanu" Timisoara; [2]„Victor Babes" University of Medicine and Pharmacy, Timisoara; [3]„Bega" Clinic of Obstetrics and Gynecology, Timisoara; [4]West "Vasile Goldiş" University of Arad*

NOTA REDACŢIEI

Cu privire la articolul intitulat *"DENTAL AND CRANIOFACIAL ANOMALIES IN A PARTICULAR CASE OF TURNER PHENOTYPE"* având ca autori*: C Capitaneanu, Valerica Belengeanu, Ioana Micle, Ioana Maris, Mihaela Cernica, D Belengeanu, Noemi Meszaros, Eugenia Capitaneanu,* publicat în JURNALUL PEDIATRULUI – Year XIV, Vol. XIV, Nr. 55-56, july-december 2011, facem urmatoarele precizări:

- Articolul a fost acceptat pentru publicare în JURNALUL PEDIATRULUI – Year XIV, Vol. XIV, Nr. 53-54, january-june 2011, conform draftului trimis autorilor.
- Datorită unei cerinţe a CNCSIS cu privire la formatul primei pagini (a se vedea diferenţele de punere în pagină dintre draftul trimis autorilor şi forma finală din revistă - pe www.jurnalulpediatrului.ro), a fost necesară rearanjarea textului articolului, proces care s-a realizat la editură în paralel cu tipărirea numărului 55-56, july-december 2011 al revistei, astfel încât printr-o eroare articolul menţionat a fost publicat în acest număr în loc de numărul 53-54, january-june 2011.